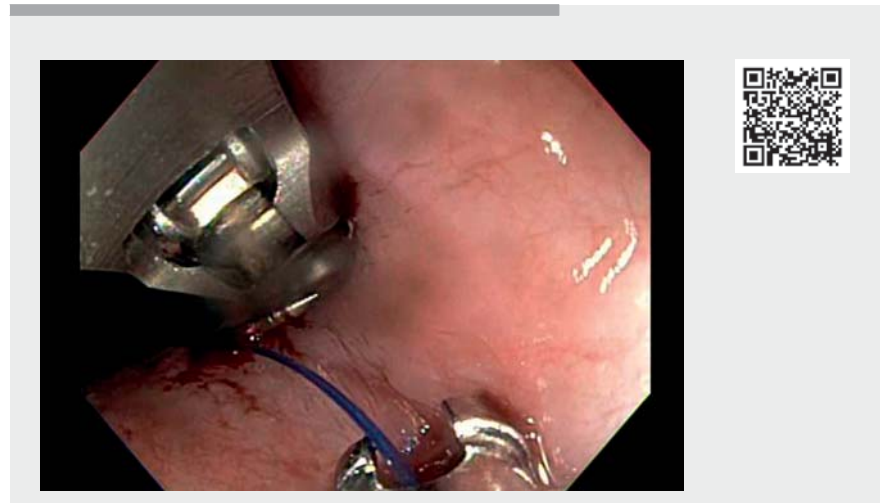


An unexpected adverse event during gastrointestinal endoscopy involving retrieval of dislodged endoscopic suture material from the trachea



A 75-year-old man with T3N1M0 esophageal adenocarcinoma who was deemed to be a poor surgical candidate and was being evaluated for chemoradiotherapy was referred for progressive dysphagia and esophageal stent placement. An upper gastrointestinal (GI) endoscopy was performed, which showed a mass in the distal esophagus leading to near-complete obstruction of the esophageal lumen. A through-the-scope fully covered self-expandable metal stent (diameter 18 mm, length 9.7 cm; Boston Scientific, Marlborough, Massachusetts, USA) was placed. To prevent stent migration, it was planned that two endoscopic sutures would be placed for stent fixation in a “mucosa–stent–mucosa” fashion. Upon deployment of the second suture, there was a device malfunction and it was not possible to deploy the cinch. The suture was cut using endoscopic scissors; however, during this process, the endoscopic suturing device briefly got stuck in the stent retrieval thread, leading to proximal stent migration. As a result, the stent was removed.

On the request of the anesthesiologist, given the patient’s tenuous hemodynamic status, the decision was made to abort the procedure and reattempt it a few days later. Because the patient had excessive airway secretions, a bedside bronchoscopy was performed by the anesthesiologist to aspirate the secretions. Incidentally, during this, endoscopic suture material was found in the trachea and the pulmonology team were consulted. Given that the patient was already intubated and in the GI endoscopy suite, a decision was made for the GI endoscopist to remove the suture using a pediatric upper GI endoscope under pulmonary supervision. The pediatric endoscope was ad-



Video 1 Retrieval of dislodged endoscopic suture material from the trachea.

vanced through the endotracheal tube and the endoscopic suture was grasped using pediatric biopsy forceps and removed (**▶ Video 1**). The endoscope and the endotracheal tube were both removed at the same time and the patient was then re-intubated. The patient was subsequently extubated in the recovery suite, without any further issues. Unexpected adverse events can occur during GI endoscopy. Our case highlights the importance of adaption, innovation, and the use of a multidisciplinary approach in managing potential unexpected adverse events during GI endoscopy.

Endoscopy_UCTN_Code_TTT_1AU_2AZ

Competing interests

The authors declare that they have no conflict of interest.

The authors

Daniyal Abbas¹, **Nicholas McDonald²**, **Mohammad Bilal³**

- 1 Department of Internal Medicine, East Carolina University, Greenville, North Carolina, USA
- 2 University of Minnesota System, Department of Medicine, Division of Gastroenterology, Hepatology and Nutrition, University of Minnesota, Minneapolis, Minnesota, USA
- 3 Advanced Endoscopy, Division of Gastroenterology & Hepatology, Minneapolis VA Medical Center and University of Minnesota, Minneapolis, Minnesota, USA

Corresponding author

Mohammad Bilal, MD

Advanced Endoscopy, Division of
Gastroenterology & Hepatology, Minneapolis
VA Medical Center, 1 Veterans Drive,
Minneapolis, MN 55417, USA
billa17@hotmail.com

Bibliography

Endoscopy 2022; 54: E871–E872

DOI 10.1055/a-1858-5168

ISSN 0013-726X

published online 24.6.2022

© 2022. The Author(s).

This is an open access article published by Thieme under the terms of the Creative Commons Attribution-NonDerivative-NonCommercial License, permitting copying and reproduction so long as the original work is given appropriate credit. Contents may not be used for commercial purposes, or adapted, remixed, transformed or built upon. (<https://creativecommons.org/licenses/by-nc-nd/4.0/>)

Georg Thieme Verlag KG, Rüdigerstraße 14,
70469 Stuttgart, Germany



ENDOSCOPY E-VIDEOS

<https://eref.thieme.de/e-videos>



Endoscopy E-Videos is an open access online section, reporting on interesting cases and new techniques in gastroenterological endoscopy. All papers include a high quality video and all contributions are freely accessible online. Processing charges apply (currently EUR 375), discounts and waivers acc. to HINARI are available.

This section has its own submission website at

<https://mc.manuscriptcentral.com/e-videos>