

POSTVACCINIAL (INFLUENZA) DISSEMINATED ENCEPHALOPATHY (BROWN-SEQUARD SYNDROME)

Suresh J. Antony, MD, FRCP, D. Frank Fleming, MD, and Teresa K. Bradley, MD
Greenville, North Carolina

This article reports a case of Brown-Sequard syndrome that occurred in a patient following the administration of trivalent influenza vaccine. The patient responded well to intravenous steroids and physical therapy. This is the first reported case in the literature. (*J Natl Med Assoc.* 1995;87:705-708.)

Key words • influenza vaccine
• Brown-Sequard syndrome

Influenza in the United States is a common yet preventable disease, especially in the population at risk. The use of the trivalent split vaccine has substantially reduced the morbidity and mortality of the disease. These commercially available vaccines have been associated with relatively few mild adverse reactions. This article reports the first case of acute disseminated encephalomyelitis presenting as Brown-Sequard syndrome following the administration of trivalent influenza vaccine.

CASE REPORT

A 57-year-old female with a history of thoracic (T6 level) neuritis, right leg paresthesias, and progressive left leg weakness was admitted to the hospital approximately 10 days after receiving trivalent influenza vaccination. In addition, she had developed urinary retention 24 hours prior to admission.

Her medical history was significant only for a febrile

reaction to a previous influenza vaccination. There was no history of drug or egg allergies or recent illnesses. Medications on admission included estrogen and medroxyprogesterone acetate. Physical examination revealed normal vital signs, and the patient was oriented to time, place, and person. Cranial nerves were intact. The upper limb strength, sensation, and reflexes were normal bilaterally. The left lower limb had one-fifth strength, decreased reflexes, normal sensation, and upgoing toes. The right limb had normal reflexes and strength with decreased sensation to pin prick and light touch extending to T8-T9. Vibration was diminished below the knees bilaterally with normal position sensation. Cerebellar testing was grossly normal considering the weakness of the left leg. Gait was not assessed accurately due to her inability to stand independently. The bladder also was noted to be distended; the rest of the physical examination was essentially normal.

Laboratory data were unremarkable except for the cerebrospinal fluid (CSF), in which the total protein was 34 mg/dL, glucose was 78 mg/dL, 9 red blood cells/ μ L, 15 white blood cells/ μ L with 91% lymphocytes, 0% polyps, and 9% monocytes. The CSF protein electrophoresis was normal, and the CSF culture was negative. Myelin basic protein was 7.8 ng/mL (indeterminant). The rheumatoid factor, antinuclear antibodies, and erythrocyte sedimentation rate were normal, and the monospot and Lyme antibody titer was negative. Magnetic resonance imaging (MRI) of the brain revealed nonspecific white matter changes in the frontal horns only. Magnetic resonance imaging of the cervical and thoracic spine revealed abnormal signals with mild generalized edema in the spinal cord from C3-T5 (Figure 1).

The patient was treated with intravenous steroids for approximately 8 days, followed by an oral steroid taper

From the Departments of Internal Medicine and Family Medicine, East Carolina University School of Medicine, Greenville, North Carolina. Requests for reprints should be addressed to Dr Suresh J. Antony, Division of Infectious Diseases, Vanderbilt University, A-3310 Medical Center North, Nashville, TN 37232-2605.

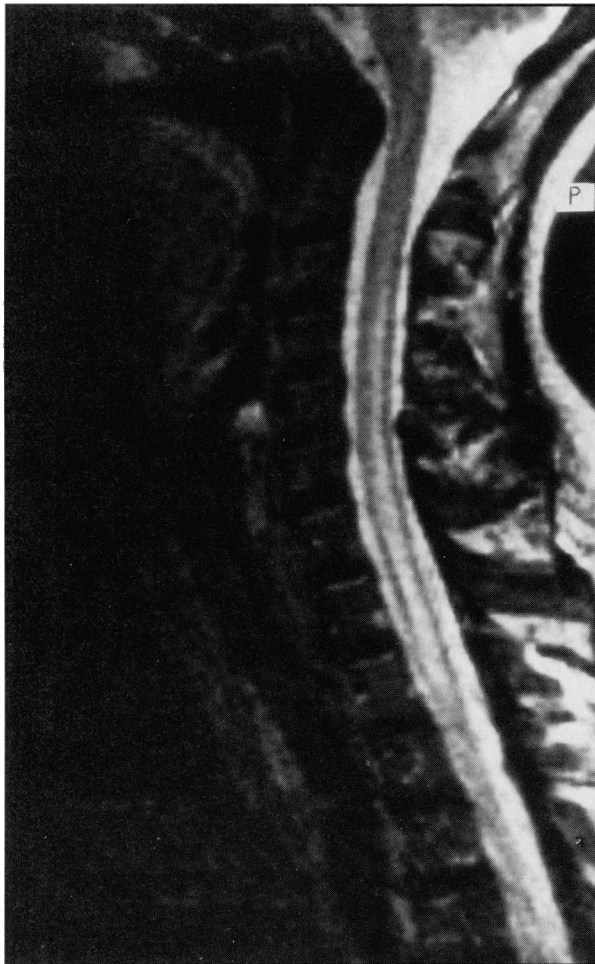


Figure 1. Magnetic resonance image of the spinal cord (C3-T5) showing abnormal signals with edema.

for 10 days, and underwent physical and occupational therapy. On follow-up, she was found to have improved strength in the left limb with persistent and sensory deficits of the right flank and leg. Excellent abductors and adductors of the thigh were noted, as well as improved strength in the hip flexors. Hyperesthesia persisted at the left T9 level. Repeat MRI of the spinal cord revealed resolution of the edema with improved patchy hyperintense linear lesions slightly to the left of the midline from T1-T4 (Figure 2), which correlates with the clinical scenario of Brown-Sequard left thoracic syndrome.

DISCUSSION

Acute disseminated encephalomyelitis following vaccination and various infections was first described

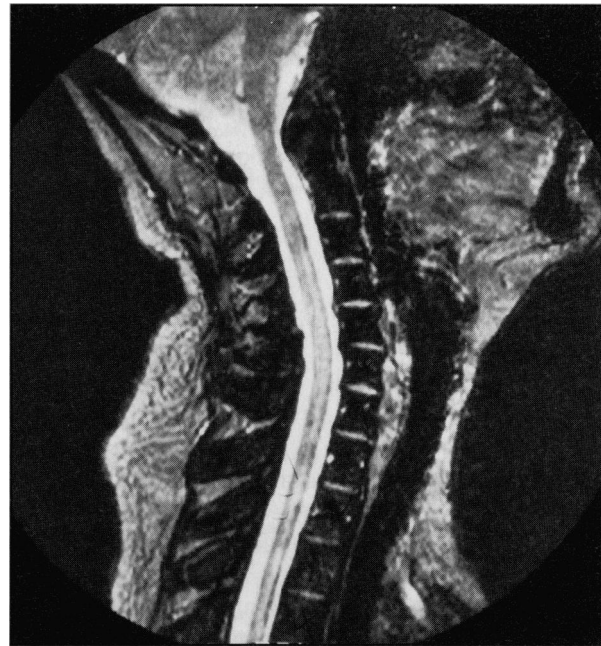

Figure 2. Magnetic resonance image of the spinal cord (T1-T5) showing resolving linear lesions to the left of the midline with resolving edema.

by DeVries¹ in 1960. He described characteristic pathologic perivenous demyelination in one group and nonspecific changes without demyelination in another group, which usually presented as encephalitis.²⁻⁴ However, since the introduction of the purified trivalent influenza split vaccine in the 1970s, these side effects have been reduced in severity.⁵⁻⁹

The Centers for Disease Control suggest that the following groups be immunized:¹⁰⁻¹¹

- adults and children with chronic cardiovascular and pulmonary disorders,
- residents of nursing homes and other chronic-care facilities,
- medical personnel who have extensive contact with high-risk patients, and
- individuals over 65 years of age and adults and children with chronic metabolic illnesses such as renal failure, immunosuppression, and asthma.^{11,12}

Vaccination for influenza is thought to provide at least 70% protection once the patient has responded with antibody production (usually 2 weeks after immunization). In addition, it is important to note that the antigenic variation is revised annually by the Food and Drug Administration to include the antigen that is most likely to be prevalent at that time.¹² The trivalent

vaccine used currently contains two strains of influenza A and one of influenza B.

Acute disseminated encephalomyelitis has been reported following rabies vaccination and the use of drugs such as streptomycin and paraaminosalicylic acid (PAS).¹³ Guillian Barre syndrome was reported in 1 out of 100 000 during the vaccination for the swine epidemic in 1976, with 1 out of 2 million persons dying of Guillian Bar Syndrome during this epidemic. This was seen only in adults and has not been reported subsequently.^{14,15}

Several studies have noted adverse effects of the influenza vaccination including flu-like illness, coryza, cough, fatigue, myalgias, and headaches.^{7,8} There was no serious neurological reaction reported in recent studies.^{6,7,16,17}

Adverse reactions to the vaccination can be classified as:

- toxic, which includes myalgia and fever and occurs in the range of 5% to 7%.¹⁸⁻²⁰
- allergic reactions such as urticaria and anaphylaxis, which are relatively rare since the introduction of the new purified vaccine, or
- neurological events such as encephalitis, which occurred with the previous vaccine.²⁻⁴

Review of the recent literature is sparse and includes a case of acute cerebellar ataxia in a child following the vaccination.²¹ Wells⁴ also reported two cases of myelitis and one case of neuropathy following vaccination. Our patient presented with neurological findings suggestive of Brown-Sequard syndrome or a variant of acute disseminated encephalomyelitis.

Most patients who present with acute disseminated encephalomyelitis have a history of recent viral illness such as measles, influenza, herpes simplex, or foreign antigen exposure, such as vaccination.²² The illness usually presents with constitutional symptoms, followed by a latent period, and then focal or widespread central nervous system involvement, such as meningitis, pyramidal tract involvement, sensory and cerebellar involvement, motor disorders, and even seizures.²³ This patient presented with both pyramidal and sensory tract involvement that resembled a Brown-Sequard syndrome.²⁴⁻²⁶

Diagnosis of these patients consists of examination of the CSF, which may have a slightly elevated protein and pressure. However, it may be completely normal in up to 30% of the cases.²³ Electroencephalograms are nonspecific and thus have limited value. The most useful test in this condition would be MRI, as demonstrated in Figures 1 and 2.

Management of postvaccinial acute disseminated encephalomyelitis has not been studied extensively due to the rarity of the condition. As noted in this patient, the use of standard doses of steroids (0.5 to 1.0 mg/kg) during the acute phase, followed by a steroid taper appears to be somewhat effective. In addition, physiotherapy and occupational therapy also would be beneficial. Recovery tends to be prolonged, but complete.

SUMMARY

The patient reported here had no prior illnesses or allergies, and the time interval between the vaccination and the illness is compatible with a direct relationship, although this cannot be proven. This case report suggests that severe neurological defects are possible with this trivalent vaccine but that they are rare. Physicians must be aware of this possibility when evaluating such unusual presentations.

Acknowledgments

The authors thank Professor Eugene Furth and Dr Jeffrey Engel of the Department of Medicine for reviewing the manuscript. The authors also thank Mrs Sharon Honeyblue for her secretarial assistance in preparing the manuscript.

Literature Cited

1. DeVries E. *Postvaccinial Perivenous Encephalitis*. New York, NY: Elsevier Publishing Co; 1960.
2. Warren K. Encephalopathy due to influenza vaccine. *Arch Intern Med*. 1956;97:803-805.
3. Wood C, Ellison G. Encephalopathy following influenza immunization. *J Pediatr*. 1964;65:745-748.
4. Wells C. A neurological note on vaccination against influenza. *Br Med J*. 1971;3:755-756.
5. Ruben FL, Jackson GG. A new subunit influenza vaccine: acceptability compared with standard vaccines and effect of dose on antigenicity. *J Infect Dis*. 1972;125:656-664.
6. Mostow SR, Schoenbaum SC, Dowdle WR. Studies with inactivated influenza vaccine purified by zonal centrifugation. Adverse reactions and serological responses. *Bull World Health Organ*. 1969;41:525-530.
7. Margolis KL, Poland GA, Nichol KL, Macpherson DS, Meyer JD, Korn JK, et al. Frequency of adverse reactions after influenza vaccination. *Am J Med*. 1990;88:2730.
8. Scherfele DW, Bjornson G, Johnston J. Evaluation of adverse events after influenza vaccination in hospital personnel. *Can Med Assoc J*. 1990;142:127-130.
9. Centers for Disease Control. Prevention and control of influenza. Recommendations of the Immunization Practice Advisory Committee (ACIP). *MMWR Morb Mortal Wkly Rep*. 1990;39(RR-7):1-15.
10. Recommendation of the Immunization Practices Advisory Committee (ACIP). Prevention and control of influenza. *MMWR Morb Mortal Wkly Rep*. 1988;37:361-364,369-379.
11. Simon H. Immunization and chemotherapy for viral infections. Ch. XXXIII. *Scientific American*. 1993;111:4-6.

12. Scott TFM. Post infectious and vaccinal encephalitis. *Med Clin North Am.* 1967;51:701-703.

13. Cavanaugh JB. Encephalopathy following administration of streptomycin and paraaminosalicylic acid. *J Clin Pathol.* 1953;6:128-134.

14. Schonberger LB, Bregman DJ, Sullivan Bolyai JZ, Keenlyside RA, Ziegler DW, Retaillian HF, et al. Guillian Barre syndrome following vaccination in the national influenza program, US 1976-1977. *Am J Epidemiol.* 1976;110:105-123.

15. Roscelli JD, Bass JW, Pang L. Guillian Barre syndrome and influenza vaccination in the US army, 1980-1988. *Am J Epidemiol.* 1991;133:952-955.

16. Masurel N, Laufer J. A one year study of trivalent influenza vaccines in primed and unprimed volunteers. Immunogenicity, chemical reactions and protection. *Journal of Hygiene.* 1984;92:263-276.

17. Cate TR, Kasel JA, Couch RB, Six HR, Knight V. Clinical trials of bivalent influenza A/New Jersey/76 A/Victoria/75 vaccines in the elderly. *J Infect Dis.* 1977;136(suppl):5518-5525.

18. Advisory Committee on Immunization Practices. Prevention of control of influenza. *MMWR Morb Mortal Wkly Rep.* 1987;36:373-386.

19. Kelbourne ED, Chanock RM, Choppin PW. Influenza vaccines—summary of influenza workshop. *J Infect Dis.* 1974;29:750-771.

20. Betts RF, Douglas RG. Comparative study of reactogenic and immunogenicity of influenza A/New Jersey virus vaccines in normal volunteers. *J Infect Dis.* 1977;139:S443-S449.

21. Saito H, Yanagiasawa T. Acute cerebellar ataxia after influenza vaccination with recurrence and marked cerebellar atrophy. *Tohoku J Exp Med.* 1989;158:95-103.

22. Alcock NS, Hoffman HL. Recurrent encephalomyelitis in childhood. *Arch Dis Child.* 1962;37:40-44.

23. Multiple sclerosis and related conditions. *Clinical Neurology.* 3:47-48.


24. Koehler PJ, Endtz LJ. The Brown Sequard syndrome—true or false? *Arch Neurol.* 1986;43:921-924.

25. Taylor RG, Gleave JRW. Incomplete spinal cord injuries (with Brown Sequard phenomena). *J Bone Joint Surg.* 1957;39B:438-450.

26. Breakman R, Penning L. Injuries of the cervical spine. In: Vinken PJ, Bruyn GW, eds. *Handbook of Clinical Neurology, Part I: Injuries of the Spine and Spinal Cord.* Amsterdam, the Netherlands: North Holland Publishing Co; 1976;25:227-380.

CUSTOM REPRINTS!

Let the *Journal of the National Medical Association* enhance your article with personally-designed reprints!



You can get more use out of the information you find in the *Journal of the National Medical Association* with article reprints. Now, SLACK Incorporated offers quality reprints in a choice of styles—you can custom-design your reprints on quality gloss paper in color or black and white.

This means you can give your article more impact with the power of color. And your reprints can be assembled into a bound booklet. Custom reprints from SLACK Incorporated give your articles a polished, professional look.

Order your reprints now in a choice of colors and in 8 1/2" x 11" or newspaper (11" x 15") sizes. The power of knowledge...the power of choice...*Journal of the National Medical Association* article reprints.

**FOR A FREE ESTIMATE, CALL CATHY WARK AT
1-800-257-8290**

(in N.J., call 1-609-848-1000)

Available on a quotation basis. Minimum order is 100.