

19. Achard JM, Duverlie G, Schmit JL, Lebon P, Veyssier P, Fournier A: Mollaret's meningitis and herpes simplex virus type 1 (Letter). *N Engl J Med* 1992; 326:893-894
20. Crossley GH, Dismukes WE: Central nervous system epidermoid cyst: A probable etiology of Mollaret's meningitis. *Am J Med* 1990; 89:805-806
21. Kwong YL, Woo E, Fong PC, Yung RWH, Yu YL: Mollaret's meningitis revisited. *Clin Neurol Neurosurg* 1988; 90:163-167
22. Goldstein R, Guberman A, Izaguirre CA, Karsh J: Mollaret's meningitis: A case with increased circulating natural killer cells. *Ann Neurol* 1986; 20:359-361
23. Bergström T: Is Mollaret's meningitis caused by herpes simplex virus type 2 (Abstr)? *Lakartidningen* 1989; 86:1279-1280
24. Swartz MN, Dodge PR: Bacterial meningitis—A review of selected aspects: 1. General clinical features, special problems and unusual meningeal reactions mimicking bacterial meningitis (continued). *N Engl J Med* 1965; 272:842-848
25. Hendler N, Schlaeffer F, Zirkin H, Rabinowitz B, Berginer VM: Mollaret's meningitis in association with delivery in a Bedouin woman; a case report. *Eur J Obstet Gynecol Reprod Biol* 1991; 39:77-79

Lymphocytic Hypophysitis

JAMES A. MAGNER, MD
R. LEE WEST, MD
Greenville, North Carolina

LYMPHOCYTIC HYPOPHYSITIS is an unusual disorder that nearly exclusively affects women; fewer than 50 cases have been reported in the literature. The present case also is unusual because a normal computed tomographic (CT) scan had been obtained of the sella shortly before the development of a large pituitary mass due to lymphocytic hypophysitis. Lymphocytes were characterized using immunoperoxidase stains. A probably unrelated malabsorption syndrome later complicated her hormone replacement therapy.

Report of a Case

The patient, a 30-year-old woman who was a registered nurse and had four children, was troubled by depression and was treated with imipramine hydrochloride. Because of frequent migraine headaches, a CT scan of the head was done in July 1989 and was normal. The normal pituitary gland was well visualized.

In September 1990, she gave birth to her fifth child. She attempted to breast-feed but had little milk, and her menses did not return. She had worsened diffuse headaches and "poor vision" when tested for her driver's license in October 1990. That same month an ophthalmologist documented 20/20 acuity in her right eye, perception of hand motion only in the left eye, normal ocular findings, and bitemporal superior quadrantanopia. Magnetic resonance imaging of the brain revealed a large mass involving the sella and suprasellar region that measured 2 cm in transverse diameter in the suprasellar area. There was lateral displacement of the carotid arteries and

elevation of the optic chiasm, but no invasion of the cavernous sinuses or Meckel's cavity. There were no cystic changes. There was prominent enhancement with gadopentetate dimeglumine (Magnevist) (Figure 1).

In October 1990, the patient was admitted for a transphenoidal operation. She was a one-pack-per-day smoker and had just completed treatment with ciprofloxacin hydrochloride for a left lower lobe pneumonia. She did not use alcohol. Her weight was 70.5 kg (155.5 lb), temperature 36.8°C (98.2°F), pulse 84 beats per minute and regular, and blood pressure 102/68 mm of mercury. Pupils were equal and reactive. Visual field examination by confrontation revealed a pronounced decrease in her bitemporal fields. Visual acuity was 20/100 in the left eye and 20/40 in the right eye. The complete blood count, platelet count, prothrombin time, sedimentation rate, and serum sodium, potassium, glucose, and creatinine levels were normal.

A partial pituitary resection revealed lymphocytic hypophysitis. The soft pituitary fragments were white-tan in color, and frozen section showed an intense lymphoid infiltrate. The softness of the specimen possibly reflected an active inflammatory process. Microscopic sections showed small clusters of pituitary cells surrounded by inflammatory infiltrate and fibrous tissue (Figure 2). No epithelial tumor was identified. The inflammatory infiltrate was predominantly mononuclear cells and comprised mature lymphocytes, mature plasma cells, macrophages, and many eosinophils. No granulomas were present, and acid-fast and methenamine-silver stains failed to show organisms.

Immunoperoxidase stains were done using the frozen tissue. There was a mixture of T cells (CD3⁺), B cells (CD22⁺), and macrophages (CD11e⁺), with CD3⁺ cells predominating. B cells were arranged in nodules. Both κ- and λ-light chains were present. All of these findings were typical of a mixed inflammatory cell infiltrate. A placental alkaline phosphatase level was normal, and an S-100 test showed occasional dendritic macrophages.

After the operation transient diabetes insipidus developed. Her visual fields and acuity returned to near normal. She was discharged on a regimen of cortisone acetate, 25 mg each morning and 12.5 mg each evening. Magnetic resonance imaging of the brain performed in December 1990 showed apparent total resection of the pituitary tumor. She noted diffuse myalgias and gradually lost weight, from 72.6 kg (160 lb) in November 1990 to 65 kg (144 lb) in June 1991, 55.8 kg (123 lb) in December 1991, 49.4 kg (109 lb) in June 1992, and 47 kg (104 lb) in November 1992. She weighed 44.9 kg (99 lb) in May 1993, had a serum cortisol level of less than 28 nmol per liter (1 μg per dl) despite excellent compliance, and was referred by her primary physician to the Endocrine Clinic at East Carolina University School of Medicine, Greenville, North Carolina.

At that time she had no vision problems, occasional migraine headaches, and no galactorrhea. She was fatigued, mildly nauseated, and had diffuse joint aches, especially in her hands. She had no recent menses and

(Magner JA, West RL: Lymphocytic hypophysitis. *West J Med* 1994; 160:462-464)

From the Section of Endocrinology, Department of Medicine (Dr Magner), and the Department of Pathology and Laboratory Medicine (Dr West), East Carolina University School of Medicine, Greenville, North Carolina.

Reprint requests to James A. Magner, MD, Section of Endocrinology, Brody Medical Sciences Bldg, Rm 2N72, East Carolina University School of Medicine, Greenville, NC 27858-4354.

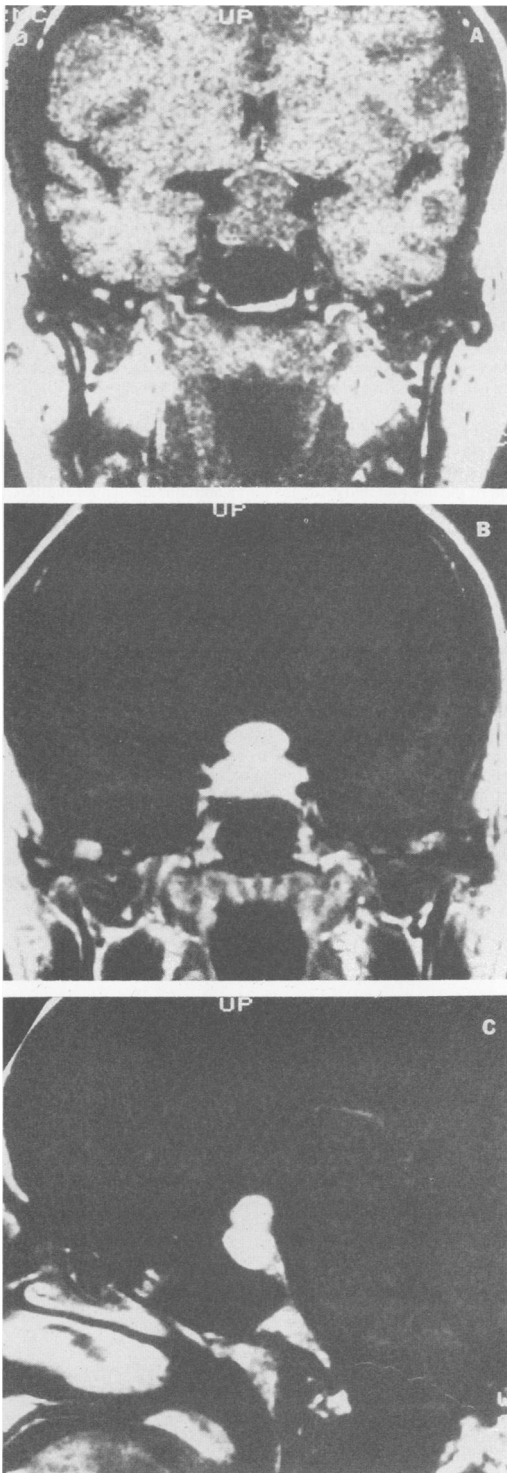


Figure 1.—T1-weighted magnetic resonance imaging of the head of a patient with lymphocytic hypophysitis 1 month postpartum. (A), A coronal view without contrast shows an hourglass-shaped pituitary mass with suprasellar extension compressing the optic chiasm. (B), A coronal view after the administration of 14 ml of gadopentetate dimeglumine (Magnevist) shows pronounced enhancement of the tumor. (C), A sagittal view after Magnevist was administered shows tumor enhancement.

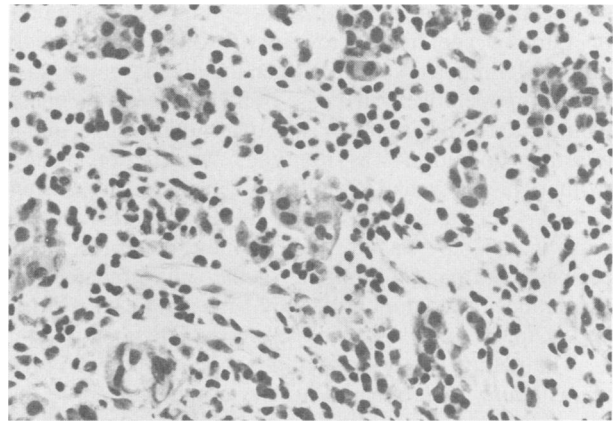


Figure 2.—Histologic section of the pituitary gland shows a small cluster of anterior pituicytes and a heavy inflammatory infiltrate of lymphocytes, plasma cells, and macrophages (hematoxylin and eosin stain, original magnification $\times 400$).

described several episodes of “hot flashes.” She reported that she first noted having diarrhea in November 1990. The stools were greasy, and the diarrhea was greatly worsened by eating fatty foods. Her blood pressure was 80/58 mm of mercury, pulse 72 per minute and regular, and respiratory rate 18 per minute. Her fundi and visual fields were normal. The hematocrit was 0.35 (35.2%), the mean cellular volume was normal, vitamin B₁₂ and folate levels were normal, and the leukocyte count was 7.1×10^9 per liter (7,100 per mm³). The prolactin level was 510 pmol per liter (12 ng per ml), luteinizing hormone 11 IU per liter, and follicle-stimulating hormone 18 IU per liter. The thyroxine level was 126 nmol per liter (9.8 μ g per dl), and the thyroid-stimulating hormone level was 2.5 mU per liter.

A diagnosis of fatty stools with concomitant malabsorption of cortisone acetate was suspected. Her fatigue, arthralgias, and nausea resolved within three days after the cortisone acetate dose was increased to 50 mg every morning and 25 mg every evening. A 24-hour specimen for fecal fat was not successfully collected. A D-xylose test and the results of a small bowel biopsy were normal. Antiendomysial antibody was not detectable. An empiric trial of pancreatic enzyme replacement (pancrelipase [Creon capsules, Solvay Pharmaceuticals]) markedly decreased the diarrhea, she rapidly gained weight and improved clinically, and she has returned to work. On days that she forgets to take the pancreatic enzyme replacement, severe greasy diarrhea returns. There is no evidence of autoimmune disease and no significant family history.

Discussion

Lymphocytic hypophysitis is a rare inflammatory disease of the pituitary gland that may produce headaches, visual field abnormalities, and hypopituitarism. Fewer than 50 cases have been reported. It more commonly affects women during pregnancy or shortly after childbirth.¹⁻⁵ Only four cases have been reported in men.⁶

The cause is uncertain, and proposed possibilities include an autoimmune reaction⁷ or an inflammatory re-

response after a viral infection.⁸ It is seldom diagnosed preoperatively, and histologic examination is required to make a definitive diagnosis. When the diagnosis was suspected preoperatively in a case of a 29-year-old pregnant woman, a trial of dexamethasone was not effective, and a pituitary operation was required.⁹ A different young woman, however, had visual field defects resolve during high-dose steroid treatment, and the field defects returned when that therapy was stopped.¹⁰ In the patient in the present case, normal CT imaging of the sella predated the appearance of the tumor, the only such incidence ever reported, to our knowledge, for lymphocytic hypophysitis.

The natural history of lymphocytic hypophysitis remains poorly understood. Pituitary deficiencies have resolved in some patients, including adrenocorticotropin, or corticotropin, deficiency.¹¹⁻¹³ Although our patient continued to take her medication, she was unintentionally withdrawn from oral cortisone acetate therapy because of malabsorption of the drug, which resulted in clinical hypoadrenalism. This fortuitous circumstance provided insight into the potential of the pituitary gland to recover after the dual insults of hypophysitis and surgical intervention. The symptoms of hypoadrenalism persisted for nearly two years, suggesting that her corticotropin deficiency never recovered. The pituitary-thyroid axis remained intact. The malabsorption syndrome was completely corrected by pancreatic enzyme replacement, but returned on several occasions when the patient forgot to take the enzyme supplement. The precise reason for the pancreatic insufficiency remains uncertain.

A rapid onset of headaches and visual field abnormal-

ities in a pregnant or recently pregnant woman should suggest the possibility of lymphocytic hypophysitis.

REFERENCES

1. Mayfield RK, Levine JH, Gordon L, Powers J, Galbraith RM, Rawe SE: Lymphoid adenohypophysitis presenting as a pituitary tumor. *Am J Med* 1980; 69:619-623
2. Asa SL, Bilbao JM, Kovacs K, Josse RG, Kreines K: Lymphocytic hypophysitis of pregnancy resulting in hypopituitarism: A distinct clinicopathologic entity. *Ann Intern Med* 1981; 95:166-171
3. Jensen MD, Handwerger BS, Scheithauer BW, Carpenter PC, Mirakian R, Banks PM: Lymphocytic hypophysitis with isolated corticotropin deficiency. *Ann Intern Med* 1986; 105:200-203
4. Miyamoto M, Sugawa H, Mori T, Hashimoto N, Imura H: A case of hypopituitarism due to granulomatous and lymphocytic adenohypophysitis with minimal pituitary enlargement: A possible variant of lymphocytic adenohypophysitis. *Endocrinol Jpn* 1988; 35:607-616
5. McConnon JK, Smyth HS, Horvath E: A case of sparsely granulated growth hormone cell adenoma associated with lymphocytic hypophysitis. *J Endocrinol Invest* 1991; 14:691-696
6. Supler ML, Mickle JP: Lymphocytic hypophysitis: Report of a case in a man with cavernous sinus involvement. *Surg Neurol* 1992; 37:472-476
7. Pestell RG, Best JD, Alford FP: Lymphocytic hypophysitis: The clinical spectrum of the disorder and evidence for an autoimmune pathogenesis. *Clin Endocrinol (Oxf)* 1990; 33:457-466
8. Yoon JW, Choi DS, Liang HC, et al: Induction of an organ-specific autoimmune disease, lymphocytic hypophysitis, in hamsters by recombinant rubella virus glycoprotein and prevention of disease by neonatal thymectomy. *J Virol* 1992; 66:1210-1214
9. Reusch JE, Kleinschmidt-DeMasters BK, Lillehei KO, Rappe D, Gutierrez-Hartmann A: Preoperative diagnosis of lymphocytic hypophysitis (adenohypophysitis) unresponsive to short course dexamethasone: Case report. *Neurosurgery* 1992; 30:268-272
10. Parent AD: The course of lymphocytic hypophysitis (Letter). *Surg Neurol* 1992; 37:71
11. Bevan JS, Othman S, Lazarus JH, Parkes AB, Hall R: Reversible adrenocorticotropin deficiency due to probable autoimmune hypophysitis in a woman with postpartum thyroiditis. *J Clin Endocrinol Metab* 1992; 74:548-552
12. Cosman F, Post KD, Holub DA, Wardlaw SL: Lymphocytic hypophysitis—Report of 3 new cases and review of the literature. *Medicine (Baltimore)* 1989; 68:240-256
13. Cryer P, Broderick D, Gonzalez JG, Clutter W: Headaches, diabetes insipidus, and hyperprolactinemia in a woman with an enlarged pituitary gland. *Am J Med* 1993; 96:332-339