

Case report

Rat-bite fever as a cause of septic arthritis: a diagnostic dilemma

RICHARD L RUMLEY,¹ NICHOLAS A PATRONE,² AND LINDSEY WHITE³

From the ¹Section of Infectious Diseases, and the ²Section of Rheumatology, East Carolina University School of Medicine; and the ³Department of Medicine, School of Medicine, East Carolina University, Greenville, North Carolina 27858-4354, USA

SUMMARY Rat-bite fever results from an infection with the organism *Streptobacillus moniliformis*. Symptomatic patients often present with fever, malaise, cough, maculopapular rash, and occasional arthritis, and usually have a history of rodent exposure. This report describes a patient with rat-bite fever resulting in suppurative arthritis. The patient's diagnosis was made by culture of *S moniliformis* from his left wrist. The diagnosis was delayed, however, owing to the lack of an exposure history, atypical clinical presentation, and the unusual microbiologic characteristics shown by this organism.

Key words: *Streptobacillus moniliformis*.

Rat-bite fever can present as either an acute or a relapsing illness characterised by the onset of arthralgias, arthritis, fever, malaise, cough, and rash.¹⁻⁵ Although rat-bite fever is an uncommonly reported disease, its aetiological agent, *Streptobacillus moniliformis*, has been cultured from patients with brain abscess,³ bacteraemia,⁴ pericardial effusion,⁵ endocarditis,⁶ and amnionitis.⁷

S moniliformis, naturally inhabiting the rodent's respiratory tract,⁸ occurs world wide.⁹ Infections are usually associated with a history of exposure to rats.⁸⁻¹⁰⁻¹¹ This organism is difficult to identify in most hospital laboratories owing to its unusual growth requirements, morphology, and biochemical reactions in commercial microbial identification kits.⁹⁻¹²

This report describes a patient with rat-bite fever, and suppurative arthritis. Although *S moniliformis* was isolated from this joint fluid, the diagnosis of rat-bite fever was delayed owing to the absence of exposure history and the difficulty in organism identification.

Case history

The patient was a 48 year old previously healthy black man from rural North Carolina, who presented with a three month history of generalised malaise and a three week history of fever, chills, headache, night sweats, productive cough, hoarseness, sore throat, and arthritis. Twelve hours before admission he developed pain, swelling, erythema and stiffness in his left wrist and shoulder. Employed as a warehouse fork lift operator, he denied exposure to rodents or domestic animals.

Physical examination showed a thin diaphoretic black man in mild respiratory distress with a temperature of 38°C, a pulse of 112 beats/min, and a respiratory rate of 40/min. No rash, lymphadenopathy, hepatosplenomegaly, cardiac changes, or pulmonary findings were detected. His left wrist was warm, swollen, tender, with a limited range of active and passive motion. His right shoulder was painful on active range of motion but showed no evidence of effusion or synovitis.

Laboratory studies showed a white blood count of $14.2 \times 10^9/l$ with 73% polymorphonuclear leucocytes, 10% bands, 14% lymphocytes, 1% eosinophils, and 2% monocytes. His haemoglobin was

Accepted for publication 27 April 1987.
Correspondence to Dr Nicholas A Patrone, 3S-16 Brody Building, School of Medicine, East Carolina University, Greenville, North Carolina 27858-4354, USA.

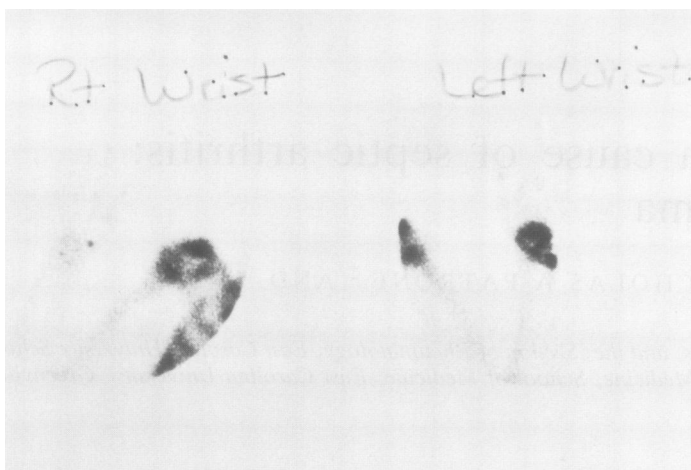


Fig. 1 After injection with ^{99m}Tc (methyl diphosphonate) the three phase bone scan of this patient's left wrist showed increased activity in all phases.

129 g/l and packed cell volume was 0.378. Westergren sedimentation rate was raised at 130 mm/h, but his blood chemistry was normal. Monospot test, antistreptolysin O titre, rheumatoid factor, and Venereal Disease Research Laboratory test were negative. Electrocardiogram and chest x ray were unremarkable. Six aerobic and anaerobic blood cultures collected over four days showed no growth. An x ray of the left wrist showed soft tissue swelling, but no periosteal changes were seen. A bone scan demonstrated increased uptake in the area of his left wrist and in both shoulders (Fig. 1). Needle aspiration of the left wrist yielded two drops of purulent material; Gram stain demonstrated numerous neutrophils, a few Gram negative rods, and rare Gram positive cocci in chains. From this aspirate several small heterogeneous colonies grew slowly on chocolate blood agar and in broth under both anaerobic and aerobic conditions. By colony morphology, Gram stain properties, and biochemical identification using a commercial test system (API 20E: Analytab Products, Plainview, NY) the organism was initially identified as a mixture of an 'unusual' *Klebsiella pneumoniae* and a *Streptococcus* species.

The patient was treated for four weeks with intravenous nafcillin and gentamicin. He improved rapidly over the first week, with gradual improvement for the remainder of therapy. Owing to mild persistent tenderness of his left wrist and shoulder when antibiotics were discontinued and the unusual collection of organisms associated with his infection, his left wrist was biopsied for microscopic examination and culture. Pathological changes of the synovium included cartilage necrosis and acute and chronic inflammatory changes consistent with septic

arthritis (Fig. 2). Stains and cultures of biopsy specimens for aerobic, anaerobic, fungal, or mycobacterial organisms were negative. Two months after he entered hospital the Centers for Disease Control in Atlanta, Georgia, identified the organism isolated from his joint fluid as *S. moniliformis*. At a follow up visit four months after admission the patient was totally free of arthritis, fever, cough, or

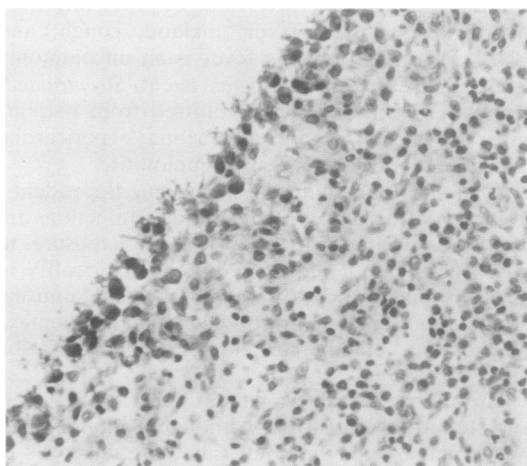


Fig. 2 The photomicrograph of the patients' left wrist synovial biopsy specimen shows extensive chronic inflammation. Oedema, numerous lymphocytes, and plasma cells are present throughout the section. Areas of fibrin and neutrophils in various stages of organisation are also present. The biopsy specimen was stained with haematoxylin and eosin.

malaise. His Westergren sedimentation rate and his peripheral white cell count had returned to normal.

Discussion

The syndrome of rat-bite fever is produced by an infection with either *S moniliformis* or *Spirillum minus*. Although these organisms are found world wide, *S moniliformis* is responsible for most of the rat-bite fever in North America. It naturally inhabits the rodent's respiratory tract but is rarely transmitted to humans. This rare occurrence may be artificial as clinical presentation is often non-specific and laboratory identification of this organism is difficult for most hospital microbiology laboratories.

The patient presented in this case had many of the reported symptoms of acute rat-bite fever, including the sudden onset of generalised malaise, weakness, fever, chills, headache, with progression to chronic arthralgias, arthritis, myalgias, and cough. Symptoms may mimic changes found in Rocky Mountain spotted fever, especially in areas endemic for *Rickettsia rickettsii* infections.¹³ The lack of a readily available serological test for this organism and an absence of rodent exposure in the history may delay or contribute to misdiagnosis of this infection.⁴ The synovial biopsy specimen from this case showed cartilage necrosis with accompanying acute and chronic inflammatory changes, but no organisms were demonstrated on tissue Gram stain or culture. This biopsy specimen, however, was taken two weeks after the initiation of empirical antimicrobial therapy.

S moniliformis has a predilection for synovial and serosal surfaces. In animals it has been recovered from the tendon sheath of arthritic turkeys and cervical abscesses of guinea pigs. *S moniliformis* has been isolated from a number of human deep seated infections.^{1 3 5-7} A pure culture of this organism was isolated from our patient's wrist, but its identification was delayed owing to its slow growth, unusual biochemical characters, and the use of commercially prepared identification kits.

This organism could have been partially characterised in our clinical microbiology laboratory and others if clinical and epidemiological information suggesting this organism had been available. This information would direct the microbiologist to note this organism's variable staining properties, slow growth, and weak age dependent fermentation reactions. This organism could be further identified by demonstrating the typical 'puff ball' colonies produced by culturing it in a serum supplemented broth and a CO₂ enriched atmosphere.^{1 12}

Penicillin, ampicillin, erythromycin, streptomycin, and the cephalosporins have been shown to

have the most activity against *S moniliformis* in vitro, with limited in vivo experiences.^{9 14} Tetracycline and chloramphenicol have variable susceptibility patterns but are probably useful in treating the L phase variants of *S moniliformis*. The sulphonamides are not active in vitro or in vivo against this organism. There are no reports of susceptibility testing of this organism to nafcillin, and the role of this antibiotic in treating our patient's infection is not known. Gentamicin does have some activity against *S moniliformis* and probably played a major part in treating his infection.

Although rat-bite fever is an uncommon illness, we believe that the non-specific clinical manifestations, difficulties with organism identification, and problems with identifying rodent exposure make an accurate diagnosis quite difficult. Appropriate microbiological studies obtained early in the infection can lead to the correct diagnosis, with potential for complete resolution of problems and specific antimicrobial therapy.

References

- Murray H W. Streptobacillus moniliformis (rat-bite fever). In: Mandell G L, Douglas R G, Bennett J E, eds. *Principles and practices of infectious diseases*. 2nd ed. New York: Wiley, 1985: 1305-6.
- Raffin B J, Freemark M. Streptobacillary rat-bite fever: a pediatric problem. *Pediatrics* 1979; **64**: 214-7.
- Oeding P, Pedersen H. Streptothrix muris ratti (Streptobacillus moniliformis) isolated from a brain abscess. *Acta Pathologica et Microbiologica Scandinavica* 1950; **27**: 436-42.
- Shanson D C, Midgley J, Gazzard B G, et al. Streptobacillus moniliformis isolated from blood in four cases of Haverhill fever. First outbreak in Britain. *Lancet* 1983; **ii**: 92-4.
- Carbeck R B, Murphy J F, Britt E M. Streptobacillary rat-bite fever with massive pericardial effusion. *JAMA* 1967; **201**: 133-4.
- McCormack R C, Kaye D, Hook E W. Endocarditis due to Streptobacillus moniliformis. *JAMA* 1967; **200**: 183-5.
- Faro S, Walker C, Pierson R L. Amnionitis with intact amniotic membranes involving Streptobacillus moniliformis. *Obstet Gynecol* 1980; **55**: 9-11s.
- Anderson L C, Leary S L, Manning P J. Rat-bite fever in animal research laboratory personnel. *Lab Anim Sci* 1983; **33**: 292-4.
- Rogosa M. Streptobacillus moniliformis and Spirillum minus. In: Lennette E H, Balows A, Hausler W J, Shawdomy H J, eds. *Manual of clinical microbiology*. 4th ed. Washington, DC: American Society for Microbiology, 1984: 400-6.
- Parker F, Hudson N P. The etiology of Haverhill fever (erythema arthriticum epidemicum). *Am J Pathol* 1926; **2**: 357-79.
- Strangeways W I. Rats as carriers of Streptobacillus moniliformis. *Journal of Pathology and Bacteriology* 1983; **37**: 45-51.
- Savage N. Facultatively anaerobic gram-negative rods. In: Krieg N R, Holt J G, eds. *Bergey's manual of systemic bacteriology*, Vol 1. Baltimore: Williams and Wilkins, 1985: 598-600.
- Portnoy B L, Satterwhite T K, Dyckman J D. Rat bite fever misdiagnosed as Rocky Mountain spotted fever. *South Med J* 1979; **72**: 607-9.
- Roughgarden J W. Antimicrobial therapy of rat bite fever. A review. *Arch Intern Med* 1965; **116**: 39-54.