

VARIATIONS IN CRANIOFACIAL AND VELOPHARYNGEAL STRUCTURES AMONG
INDIVIDUALS WITH 22Q11.2 DELETION SYNDROME

by

Lakshmi Kollara Sunil

July, 2016

Director of Dissertation: Jamie Perry, PhD

Major Department: Communication Sciences and Disorders

22q11.2 deletion syndrome is the most common genetic cause of velopharyngeal dysfunction. Studies examining 22q11.2 deletion syndrome have thus far primarily focused on variations in the bony framework. Limited information exists regarding the velopharyngeal muscle variations for this clinically challenging population. However, with advances in MRI, muscle and soft tissue imaging is possible. A series of experiments were thus designed to explore and validate the use of our research methodology on normal control participants and a single participant with 22q11.2 deletion syndrome, before initiating the study on a larger sample of children with 22q11.2 deletion syndrome. The overarching aims of this investigation were to examine craniofacial and velopharyngeal characteristics among children with 22q11.2 deletion syndrome and to determine whether craniofacial measures can predict velopharyngeal structure and muscle configurations in this population. This investigation represents the first large scale attempt to image children with 22q11.2 DS without sedation.

The aim of Study I was to validate the use of a supine MRI scanner over an upright scanner to obtain data of interest. Study II was focused on the application of a child-friendly MRI protocol to ensure data collection on young pediatric participants without the use of

sedation. The aim of Study III was to translate our child-friendly MRI scanning protocol to a clinical population and assess feasibility in a single participant with 22q11.2 deletion syndrome. Study IV assessed craniofacial and velopharyngeal characteristics among children with 22q11.2 deletion syndrome using the imaging protocol detailed in studies one, two, and three.

Results from this study suggest that children with 22q11.2 deletion syndrome have several craniofacial and velopharyngeal characteristics that are significantly different compared to children with normal velopharyngeal anatomy. This investigation describes a safe and effective method to obtain MRI data in a clinically complex population without the use of sedation. Individuals with 22q11.2 deletion syndrome present with unique velopharyngeal muscle variations that may contribute to the high rate of velopharyngeal dysfunction associated with this syndrome.

VARIATIONS IN CRANIOFACIAL AND VELOPHARYNGEAL STRUCTURES AMONG
INDIVIDUALS WITH 22Q11.2 DELETION SYNDROME

A Dissertation

Presented to the Faculty of the Department of
Communication Sciences and Disorders
East Carolina University

In Partial Fulfillment of the Requirements for the Degree
Doctor of Philosophy in Communication Sciences and Disorders

by

Lakshmi Kollara Sunil

July, 2016

© Lakshmi Kollara Sunil, 2016

VARIATIONS IN CRANIOFACIAL AND VELOPHARYNGEAL STRUCTURES AMONG
INDIVIDUALS WITH 22Q11.2 DELETION SYNDROME

by

Lakshmi Kollara Sunil

APPROVED BY:

DIRECTOR OF
DISSERTATION: _____

Jamie Perry, PhD

COMMITTEE MEMBER: _____

Heather Harris Wright, PhD

COMMITTEE MEMBER: _____

Charles Ellis, Jr, PhD

COMMITTEE MEMBER: _____

Xiangming Fang, PhD

COMMITTEE MEMBER: _____

Adriane Baylis, PhD

CHAIR OF THE DEPARTMENT OF
COMMUNICATION SCIENCES AND DISORDERS: _____

Jamie Perry, PhD

DEAN OF THE
GRADUATE SCHOOL: _____

Paul J. Gemperline, PhD

To my loving family

ACKNOWLEDGEMENTS

My deepest gratitude and appreciation to my mentor Dr. Jamie Perry for inspiring me to pursue my PhD. I can never thank you enough for the guidance, support, and friendship that you have provided me. Thank you for nurturing my passion for cleft palate research and for the wisdom and humor you have shared along the way. Thank you also for always having faith in me and for encouraging me to pursue my ideas. I am so honored to have had the opportunity to work under your guidance and direction and to be your first PhD graduate.

I would like to thank my committee members, Dr. Heather Wright, Dr. Charles Ellis, Dr. Xiangming Fang, and Dr. Adriane Baylis for the collaboration, guidance, and thought provoking suggestions that each of them offered to me over the years. A huge thank you to all the faculty at East Carolina University for their encouragement and support throughout my graduate degrees. Dr. Heather Wright, I am so thankful for your insights, advice, and encouragement. My thanks to Dr. Balaji Rangarathnam for his helpful guidance on international paperwork. Dr. Joseph Kalinowski, thank you for sharing your perspectives on research and life in academia. A special thank you to Dr. Kathleen Cox and Ms. Lori Kincannon for helping me juggle two graduate degrees and an intense clinical practicum. I would like to thank Mr. Jason Conrad in the Office for Research Integrity and Compliance for his expertise on all IRB related matters.

I would also like to thank my research collaborators Dr. Adriane Baylis, Dr. Richard Kirschner, Dr. Gregory Bates, Mr. Mark Smith, and Ms. Alyssa Martz at Nationwide Children's Hospital for their expertise and contributions to this study. My thanks also to all the families and children who enthusiastically participated in my studies. I would like to thank the Cleft Palate-Craniofacial Journal and the Journal of Speech, Language, and Hearing Research for permission

to include copyrighted articles. My thanks also to the Cleft Palate Foundation and the American Cleft Palate-Craniofacial Association for funding two of my research studies.

To my friends Graham, Stephen, Hannia, Courtney, Larrin, Hannah, and Udayasree, life in Greenville would have been very hard to survive without you all. Thank you for helping me celebrate my accomplishments and for being there for me during some tough times. Graham, I am so thankful for your friendship, moral support, technical guidance, and coffee breaks during our time together in the program. Stephen, Hannia and Ian, thank you for being my family here the past four years.

Thank you to my grandparents Yeshoda Ramunni and Kausalya Chathunny for your words of wisdom and blessings. To my uncle Chandroth and aunt Sarasa, thank you for welcoming me into the United States with open arms and for always being there for me. Vandhu, thank you for being my rock. Amma and Acha, I am so appreciative of all the sacrifices you made to get me to where I am today. I can never thank you enough for the unconditional love, constant support, and motivation you have provided me my entire life. Thank you for all that you do for me, no matter how far apart we may be.

TABLE OF CONTENTS

| | |
|---|------|
| LIST OF TABLES | xiii |
| LIST OF FIGURES | xv |
| CHAPTER 1: INTRODUCTION..... | 1 |
| Study I..... | 2 |
| Study II..... | 3 |
| Study III | 4 |
| Study IV | 5 |
| References..... | 6 |
| CHAPTER 2: LITERATURE REVIEW | 7 |
| History of 22q11.2 DS | 7 |
| General Overview of Characteristics | 7 |
| Craniofacial Features | 9 |
| Platybasia | 9 |
| Cranial Length | 11 |
| Cervical Spine..... | 13 |
| Oral Cavity..... | 13 |
| Velopharyngeal Anatomy and Physiology in 22q11.2 DS | 14 |
| Pharyngeal Anatomy..... | 14 |
| Palatal Anomalies | 16 |
| Asymmetry of the Palate and Pharynx in 22q11.2 DS1 | 18 |

| | |
|---|----|
| Speech Characteristics | 19 |
| Speech Surgery and Outcomes | 20 |
| MRI Investigations of the Velopharynx in 22q11.2 DS | 22 |
| References..... | 24 |

CHAPTER 3: EFFECTS OF GRAVITY ON THE VELOPHARYNGEAL
STRUCTURES IN CHILDREN USING UPRIGHT MAGNETIC

| | |
|------------------------|----|
| RESONANCE IMAGING..... | 28 |
|------------------------|----|

(Article published in the Cleft Palate-Craniofacial Journal)

| | |
|---|----|
| Abstract | 28 |
| Introduction | 29 |
| Method | 32 |
| Subjects..... | 32 |
| Magnetic resonance imaging | 33 |
| Speech tasks | 35 |
| Regions of interest | 36 |
| Statistical methods | 39 |
| Results | |
| Velar measures | 40 |
| Levator Veli Palatini Muscle Measures | 41 |
| Differences Across Condition..... | 42 |
| Discussion..... | 43 |

| | |
|--|----|
| Velar measures (length, thickness, and height) | 43 |
| Levator Veli Palatini Muscle Measure | 44 |
| Clinical Implications..... | 46 |
| Limitations of the Study..... | 47 |
| Conclusion | 48 |
| References..... | 49 |

CHAPTER 4: RACIAL VARIATIONS IN VELOPHARYNGEAL

AND CRANIOMETRIC MORPHOLOGY IN CHILDREN: AN

IMAGING STUDY (Article published in Journal of Speech,

Language, and Hearing Research)

| | |
|---|----|
| Abstract | 51 |
| Introduction..... | 52 |
| Method | 55 |
| Participants..... | 55 |
| Pre-scan training | 57 |
| Magnetic resonance imaging | 58 |
| Image analyses | 58 |
| Statistical analyses | 63 |
| Results..... | 65 |
| Effects of sex and race on craniometric measures | 69 |
| Effects of sex and race on velopharyngeal measures..... | 70 |

| | |
|--|----|
| Craniometric and muscle prediction models..... | 70 |
| Qualitative differences | 73 |
| Discussion..... | 76 |
| Conclusion | 81 |
| References..... | 83 |

CHAPTER 5: EXAMINING A NEW METHOD TO STUDYING

VELOPHARYNGEAL STRUCTURES IN A CHILD WITH 22Q11.2 DS

(Article accepted with minor revisions in Journal of Speech, Language,

and Hearing Research)

| | |
|---|----|
| Abstract..... | 87 |
| Introduction..... | 88 |
| Method | 90 |
| Participant | 90 |
| Orofacial examination..... | 91 |
| Perceptual articulation and resonance assessments | 91 |
| Aerodynamic pressure flow | 92 |
| MRI behavioral training..... | 92 |
| Imaging protocol | 93 |
| Results and discussion | 94 |
| Conclusion..... | 98 |
| References..... | 99 |

CHAPTER 6: MORPHOLOGICAL VARIATIONS IN VELOPHARYNGEAL
MUSCLES AMONG INDIVIDUALS WITH 22Q11.2 DELETION SYNDROME...101

| | |
|---|-----|
| Introduction | 101 |
| Methods | 105 |
| Participants..... | 105 |
| Behavioral Adaptations..... | 106 |
| MRI Study..... | 107 |
| Image Analyses..... | 108 |
| Statistical analyses | 113 |
| Results..... | 114 |
| Aim I: Craniofacial and Velopharyngeal Variations | 115 |
| Aim II: Prediction Models | 120 |
| Discussion..... | 123 |
| Craniofacial Observations | 124 |
| Velopharyngeal Observations | 126 |
| Velopharyngeal Muscle Observations | 129 |
| Relationship between Craniofacial and Velopharyngeal Variables..... | 131 |
| Future Directions | 133 |
| Conclusion | 134 |
| References | 135 |

CHAPTER 7: GENERAL DISCUSSION139

| | |
|--|-----|
| APPENDIX A: IRB APPROVAL FOR EAST CAROLINA UNIVERSITY | 141 |
| APPENDIX B: IRB APPROVAL FOR NATIONWIDE CHILDREN'S HOSPITAL..... | 142 |
| APPENDIX C: IRB APPROVAL FOR UNIVERSITY OF ILLINOIS | 143 |
| APPENDIX D: PERMISSION LETTER FOR CLEFT PALATE-CRANIOFACIAL JOURNAL..... | 145 |
| APPENDIX E: PERMISSION LETTER FOR JOURNAL OF SPEECH, LANGUAGE, AND HEARING RESEARCH | 146 |

LIST OF TABLES

A1. Scanning protocol35

A2. Description of Measurements36

A3. Group means and differences across all six measures40

A4. Comparison of group means for levator muscle morphology analyses
 between current study and similar studies using MRI46

B1. Subject demographics56

B2. Description of the 11 craniometric measures60

B3. Description of the nine velopharyngeal measures.....62

B4. Estimated marginal means and standard deviations for each craniometric
 measures.....66

B5. Estimated marginal means and standard deviations for each muscle measures67

B6. Results from the ANCOVA models, analyzing the effects of sex and
 race on craniometric measures68

B7. Results from the ANCOVA models, analyzing the effects of sex and
 race on muscle measures69

B8. Results from the multiple linear regression analyses72

C1. Velopharyngeal measures in comparison to an age matched cohort96

| | |
|--|-----|
| D1. Description of craniofacial and velopharyngeal measures | 109 |
| D2. Means and standard deviations for craniofacial variables for the 22q group and normative control group | 114 |
| D3. Means and standard deviations for velopharyngeal structures and muscles for the 22q group and normative control group | 115 |
| D4. Results from the ANCOVA models, analyzing the differences in craniofacial structures among the 22q group and normative control group | 116 |
| D5. Results from the ANCOVA models, analyzing the differences in velopharyngeal structures and muscles among the 22q group and normative control group..... | 118 |
| D6. Results from the ANCOVA models, analyzing the differences in velopharyngeal structures and muscles among the 22q group and normative control group | 121 |
| D7. Results from the multiple linear regression analysis for the 22q11.2 DS group | 122 |

LIST OF FIGURES

| | |
|--|-----|
| A1. Demonstration of the velar measures and retrovelar space in the midsagittal image plan..... | 37 |
| A2. Measures taken on the oblique coronal image plane. | 38 |
| B1. Craniometric measures obtained in the midsagittal plane..... | 61 |
| B2. Oblique coronal image demonstrating levator muscle..... | 63 |
| B3. Magnetic resonance images demonstrating qualitative differences in velar length and thickness across different racial groups in the midsagittal plane..... | 74 |
| B4. Magnetic resonance images demonstrating cohesive levator muscle sling in the oblique coronal plane..... | 75 |
| C1. Side-by-side comparison of the levator muscle in the oblique coronal image plane..... | 95 |
| C2. Side-by-side comparison of velopharyngeal structures in the sagittal image plane. .. | 97 |
| D1. Craniofacial measures | 110 |
| D2. Velopharyngeal measures demonstrated in the midsagittal image plane | 111 |
| D3. Levator and velopharyngeal measures demonstrated in the oblique coronal image plane | 112 |

CHAPTER 1

INTRODUCTION

22q11.2 deletion syndrome (22q11.2 DS) is the most common genetic cause of velopharyngeal dysfunction and is the second most common multiple anomaly syndrome, with a population prevalence of 1:2000 people (Shprintzen, 2008). A comprehensive review of the literature related to cranial base, platybasia, pharyngeal dimensions, cervical spine, oral cavity, velar, and speech characteristics in individuals with 22q11.2 DS syndrome will be reviewed in Chapter II.

Studies examining 22q11.2 DS have thus far primarily focused on variations in the bony framework. With advances in MRI, muscle and soft tissue imaging is possible. Only one MRI investigation has been conducted to assess the internal musculature of the velopharyngeal mechanism in children with 22q11.2 DS (Park, Ahn, Jeong, & Baek, 2015). Limitations of this study include the inclusion of only two variables (muscle thickness and symmetry) and the use of a comparison cohort that included only children with submucous cleft palate.

Limited information exists regarding the velopharyngeal muscle variations for this clinically challenging population. It is likely that these structural variations are evident and contribute to differences in functional aspects such as speech and resonance characteristics in these individuals. In order to understand these functional differences, variations or predisposing features of the structural characteristics must be examined further. Specifically, there are no data on how muscle form affects function in individuals with 22q11.2 DS. Magnetic resonance imaging studies in children are limited. There are no studies that have demonstrated the use of MRI in the 22q11.2 DS population without the use of sedation. Given the known risks associated with sedation (Halliday & Kelleher, 2013), the experiments below demonstrate a means to overcome this critical barrier.

A series of experiments were thus designed to explore and validate the use of our research methodology on normal controls and a single subject with 22q11.2 DS, before initiating the study on a larger 22q11.2 DS population. The series of investigations are further described below in more detail:

Study I: Does gravity influence the velopharyngeal structures in children during speech?

Kollara, L., & Perry, J. L. (2014). Effects of gravity on the velopharyngeal structures in children using upright magnetic resonance imaging. *Cleft Palate-Craniofacial Journal*, 51(6), 669-676.

Speech is typically produced in the upright position. Magnetic resonance imaging data are traditionally obtained in the supine position, yet information obtained from these studies is applied to an upright position activity such as speech. This study aimed to compare the velopharyngeal mechanism in the upright and supine positions in 12 children between 4- 8 years of age, during rest and sustained speech production. Specifically, we examined the hypothesis that gravity has an effect on velopharyngeal structures during rest and sustained speech production. Results indicated gravity had a non-significant effect on the velopharyngeal structures of interest and that supine imaging data could be translated to an upright activity such as speech. This study represents the first investigation of the influence of gravity on velopharyngeal structures among the child population. As a result of this study, we determined that velopharyngeal data obtained in the supine position, such as from MRI, could be used to relate to speech events that occur in the upright position. A child-friendly MRI scanning protocol was also created as part of Study I. This protocol demonstrated a 100% success rate for imaging children as young as four years, without the use of sedation. The child-friendly adaptations

included letting the participants listen to the sounds of the MRI scanner by listening to audio samples of MRI noise played on an iPad and encouraging them to watch the participant being imaged before them. The participants were allowed to explore the MRI machine before their exams and an adult (parent/investigator) was present in the scanning room for the entire duration of the scan. The investigator communicated with the participants throughout the exam and frequently inquired about their comfort level. During the study, the participants listened to music through headphones to increase patient comfort and minimize distraction and were also given a panic button. Foam cushions were placed on either side of the participants' head within the head coil and the participants wrapped their hands around a pillow to minimize motion artifacts. This behavioral imaging protocol has since been adopted for other imaging studies.

Study II: Does race and sex affect velopharyngeal and craniometric morphology in children?

Kollara, L., Perry, J. L., & Hudson, S. (2016). Racial variations in velopharyngeal and craniometric morphology in children: An imaging study. *Journal of Speech, Language, and Hearing Research*, 59(1), 27-38.

Race and sex has been found to have a significant effect on velar length and thickness in the adult population (Perry, Kuehn, Sutton, Gamage, & Fang, 2014). To investigate the possibility of these findings being present in the child population, 32 children with normal velopharyngeal anatomy across two racial groups including Black and White were imaged using MRI. The child-friendly MRI scanning protocol (Kollara & Perry, 2014) was successfully implemented for this study and enabled 100% success rate in collecting data for the variables of interest for a larger sample size (32 children). No significant sex effects were noted for the variables of interest. However, a significant racial difference was observed for velar thickness,

velar length, and velopharyngeal ratio. As a result of this study, we determined that future studies examining velar variables would need to be controlled for race. Additionally, we determined we do not need to control for sex for studies using the same variables and age range. Results also indicated the anterior cranial base angle to be the most common craniometric predictor for muscle prediction models. This served as a preliminary indicator of the potential in utilizing craniometric markers in assessing muscle physiology for clinical populations that present with abnormal cranial base angles such individuals with 22q11.2 DS.

Study III: Is our non-sedated MRI protocol appropriate for individuals with 22q11.2 DS and what insights can be obtained?

Kollara, L., Schenck, G. C., Perry, J. L., & Jaskolka, M. (2016). Examining A New Method to Studying Velopharyngeal Structures in A Child with 22q11.2 DS. *Manuscript accepted with minor revisions for publication.*

To our knowledge, no studies to date have used MRI to scan children with 22q11.2 DS without the use of sedation. This investigation was conducted to determine the feasibility of our proposed MRI methods in a single subject of our targeted clinical population. This study was also used to examine qualitatively the muscle variations typical for this population and to provide further support for our study hypotheses. Magnetic resonance imaging data on the velopharyngeal structures of interest was successfully obtained for the participant using our child-friendly MRI protocol (Kollara & Perry, 2014). Preliminary findings revealed a small, U-shaped levator muscle arrangement. The muscle appears thin compared to age- and sex-matched controls (Perry et al., 2014). The velum appeared thin and short and increased pharyngeal depth was also noted. It was thus determined that children with 22q11.2 DS could be imaged using

MRI without the use of sedation and that our research protocol could be tested on a larger subject group.

Study IV: Do variations exist in craniofacial and velopharyngeal structures among children with 22q11.2 DS?

Information about the internal velar musculature among individuals with 22q11.2 DS is limited. There are no published findings on the levator physiology for these individuals, in comparison to an age-matched normative cohort. The purpose of this study is to investigate the structural characteristics of craniofacial and velopharyngeal anatomy among children with 22q11.2 DS, in comparison to age-matched, non-syndromic children with normal velopharyngeal anatomy. We will apply our previously described child-friendly MRI protocol (Kollara & Perry, 2014) to image children with 22q11.2 DS without the use of sedation. The following hypotheses were developed from the investigations detailed above:

Hypothesis 1: Individuals with 22q11.2 DS will demonstrate an obtuse anterior cranial base angle, a short, thin velum and a thin, hypoplastic levator muscle compared to age-matched controls.

Hypothesis 2: Craniometric variables related to velopharyngeal depth (cranial base and pharyngeal bony depth) will be correlated to muscle dysmorphology (thickness and length).

REFERENCES

- Halliday, M., & Kelleher, J. (2013). Question 1: Is sedation necessary for MRI in an infant? *Archives of Disease in Childhood*, 98(10), 825-828. doi:10.1136/archdischild-2013-304898.
- Kollara, L., & Perry, J. L. (2014). Effects of gravity on the velopharyngeal structures in children using upright magnetic resonance imaging. *Cleft Palate-Craniofacial Journal*, 51(6), 669-676. doi:10.1597/13-107.
- Kollara, L., Perry, J. L., & Hudson, S. (2016). Racial variations in velopharyngeal and craniometric morphology in children: An imaging study. *Journal of Speech, Language, and Hearing Research*, 59(1), 27-38. doi:10.1044/2015_JSLHR-S-14-0236.
- Park, M., Ahn, S. H., Jeong, J. H., & Baek, R. M. (2015). Evaluation of the levator veli palatini muscle thickness in patients with velocardiofacial syndrome using magnetic resonance imaging. *Journal of Plastic, Reconstructive & Aesthetic Surgery*, doi:S1748-6815(15)00191-6.
- Perry, J. L., Kuehn, D. P., Sutton, B. P., Gamage, J. K., & Fang, X. (2014). Anthropometric analysis of the velopharynx and related craniometric dimensions in three adult populations using MRI. *Cleft Palate-Craniofacial Journal*, doi:10.1597/14-015.
- Shprintzen, R. J. (2008). Velo-cardio-facial syndrome: 30 years of study. *Developmental Disabilities Research Reviews*, 14(1), 3-10. doi:10.1002/ddrr.2.

CHAPTER 2

LITERATURE REVIEW

History of 22q11.2 DS

A syndrome is defined as the presentation of multiple anomalies in an individual wherein all of those anomalies have the same etiology (Shprintzen & Golding-Kushner, 2008).

Microdeletion refers to a type of submicroscopic DNA rearrangement where there is deletion of DNA across more than one gene (Shprintzen & Golding-Kushner, 2008). 22q11.2 deletion syndrome (22q11.2 DS) is the most common genetic cause of velopharyngeal dysfunction and is the second most common multiple anomaly syndrome, with a population prevalence of 1:2000 people (Shprintzen, 2008). The chromosome microdeletion occurs on the shorter branch of chromosome 22 at band q11.2, resulting in a genetic deficiency of approximately 40 genes (Shprintzen, 2008). This syndrome perhaps has the most expansive phenotype of any multiple anomaly syndromes with over 180 clinical features, where no presentation is the same (Shprintzen, 2008). Speech and language impairment, congenital heart issues, developmental delay, and psychiatric disorders occur in these individuals at much higher rates compared to the general population (Shprintzen & Golding-Kushner, 2008).

General Overview of Characteristics

The term velo-cardio-facial syndrome (VCFS) was first reported in a paper that described similar patterns of malformation in 12 individuals (Shprintzen et al., 1978). The observed features included palatal (velo for velum) and heart (cardio) anomalies, and a characteristic facial appearance (facial). In 1992, it was determined that VCFS was a microdeletion syndrome caused

by a deletion on chromosome 22. Severe hypernasality and congenital heart disease were the initial symptoms that called attention to 22q11.2 DS (Shprintzen & Golding-Kushner, 2008). To date, 190 distinct patterns of anomalies have been reported in individuals with 22q11.2 DS. These include craniofacial, ocular, ear, dental, neurologic, genitourinary, skeletal, vascular, muscle, glandular, heart, limb, internal organ, and genitourinary anomalies (Shprintzen & Golding-Kushner, 2008). The following craniofacial malformations are reported to occur in connection in 22q11.2 DS (Shprintzen & Golding-Kushner, 2008):

1. Platybasia
2. Palatal anomalies (overt cleft palate, submucous cleft palate, occult submucous cleft palate, deficient muscle, and asymmetric palate)
3. Cleft lip
4. Asymmetric pharynx
5. Retrognathia
6. Asymmetric crying facies (infancy)
7. Functional facial asymmetry
8. Structural facial asymmetry
9. Straight facial profile
10. Hypotonic facies
11. Vertical maxillary excess
12. Small primary teeth
13. Enamel hypoplasia (primary dentition)
14. Downturned oral commissures
15. Microstomia

16. Microcephaly

17. Small posterior cranial fossa

A comprehensive literature review of only pertinent craniofacial and velopharyngeal anomalies will be included in this review. Specifically, this review will cover features including platybasia, cranial base, pharyngeal dimensions, cervical spine, oral cavity, velar, and speech characteristics among this population.

Craniofacial Features

Studies have investigated variations in cranial base length, cranial base angles, facial dimensions, facial orientation, maxilla, mandible, cervical spine, pharyngeal dimensions, and hard palate lengths in individuals with 22q11.2 DS.

Platybasia

Platybasia is described as an abnormal flattening of the skull base. The human cranium has a flexion along the skull base that differentiates its anterior and posterior aspects. The anterior portion supports the facial bones and the posterior portion contains the posterior part of the brain and the spinal cord. The angulation of the skull base is measured as the angle from the nasion to the sella turcica to the basion. This angle is typically 128° with a standard deviation of approximately 4° (Shprintzen & Golding-Kushner, 2008). An abnormal obtuse angulation of the skull base results in a condition called platybasia. A more acute angulation of the skull base results in kyphosis. Platybasia results in deepening of the velopharyngeal port which may result in velopharyngeal dysfunction (Arvystas & Shprintzen, 1984).

Variable findings have been reported regarding the presence of platybasia in subjects with 22q11.2 DS. Studies have reported this subject group to have a confirmed diagnosis of platybasia utilizing diagnostic methods such as lateral cephalometry and magnetic resonance

imaging (MRI) (Arvystas & Shprintzen, 1984; Heliovaara & Hurmerinta, 2006; Ruotolo et al., 2006). Other studies have indicated a trend toward platybasia, but not statistically significant, utilizing diagnostic methods such as lateral cephalometry and computed tomography (Dalben Gda, Richieri-Costa, & Taveira, 2010; Glander & Cisneros, 1992; Wang et al., 2009). Studies have also reported the non-existence of platybasia in these subjects (Veerapandiyan et al., 2011).

The relationship between cranial base angles and speech resonance in 24 individuals with 22q11.2 DS was assessed utilizing retrospective chart reviews (Spruijt, Kon, & Mink van der Molen, 2014). Groups of patients with hypernasal speech were found to have a trend toward more obtuse cranial base angles. However, no significant relationship was determined between resonance ratings and cranial base angles. The clinical significance of platybasia is still unknown.

The prevalence of platybasia in patients with 22q11.2 DS between three and 40 years of age, with congenital velopharyngeal insufficiency and no history of previous surgeries was examined using lateral cephalometric radiography (Nachmani et al., 2013). Out of the 366 subjects, 79 were syndromic (n = 28 with 22q11.2 DS and Pierre-Robin; n = 22 with Treacher Collins and Stickler; n = 29 with miscellaneous). The control group consisted of 126 subjects with normal speech and no previous surgeries. Findings from this study revealed increased prevalence of platybasia in subjects with velopharyngeal insufficiency compared to other controls (28.7% versus 2.4%) and increased prevalence of platybasia in 22q11.2 DS than other syndromic groups (50% versus 27.3% (Pierre Robin). The prevalence of platybasia was also found to be significantly different for the five velopharyngeal insufficiency groups in this study, with the non-cleft cohort demonstrating the highest prevalence (40.3%), followed by occult submucous cleft palate (33.7%), submucous cleft palate (28.8%), cleft palate only (20.3%), and

cleft lip and palate (16.7%). The increased prevalence of platybasia in non-cleft subjects (40.3%) without 22q11.2 DS highlight the fact that platybasia may serve as a diagnostic skeletal marker to differentially diagnose patients with congenital velopharyngeal insufficiency with or without cleft palate (Nachmani et al., 2013). Platybasia could result in greater nasopharyngeal space, which may worsen symptoms of velopharyngeal dysfunction in instances of small mechanical deficit.

Platybasia may adversely affect the relationship between the facial bones and the neurocranium which may result in abnormal configurations of the nasopharynx (Arvystas & Shprintzen, 1984; Nachmani et al., 2013). Velopharyngeal closure is accomplished through the synchronized movements of the velopharyngeal muscles, primarily the levator veli palatini (levator) muscle. Superior and posterior movements of the velum responsible for velopharyngeal closure require constriction of the levator muscle, the palatopharyngeus, and the superior pharyngeal constrictor muscle. This vector of muscles has its origins in the skull base and posterior pharynx and inserts into the palate. Abnormalities in these bony structures have a subsequent effect on muscle form and function, which may influence velopharyngeal dysfunction (Perry et al., 2014; Nachmani et al., 2013).

Cranial Length

Forty-one subjects with 22q11.2 DS were noted to have longer anterior cranial base length compared to age- and sex-matched controls (Heliovaara & Hurmerinta, 2006). The subjects were evaluated cephalometrically and 13 subjects had palatal clefts. These are contradictory to other findings (Wang et al., 2009), where these subjects were described to have decreased anterior cranial base lengths determined using three-dimensional computed tomography. Comparisons were made with 20 age- and sex-matched controls with cleft palate.

Posterior cranial base length (Dalben Gda et al., 2010; Heliovaara & Hurmerinta, 2006; Wang et al., 2009) and posterior cranial base angle are reportedly decreased in individuals with 22q11.2 DS.

The skull base anomalies in 22q11.2 DS alter the position of the facial bones. These variations are not represented as malformations of the facial bones. Rather, it affects the relative positions of the facial bones to one another. The midface and resulting facial profile are recessed in relation to the forehead and as such appear flat (Shprintzen & Golding-Kushner, 2008). A longer than normal lower third of the face is referred to as vertical maxillary excess. This feature is reported to be a common finding in individuals with 22q11.2 DS (Shprintzen & Golding-Kushner, 2008). Compared to non-syndromic control subjects, subjects with 22q11.2 DS have been reported to have increased overall face length (Heliovaara & Hurmerinta, 2006), decreased overall face length (Wang et al., 2009), increased superior facial height (Wang et al., 2009), and increased anterior facial height (Arvystas & Shprintzen, 1984). Other facial characteristics described for these subjects include increased facial convexity (Heliovaara & Hurmerinta, 2006) and malar flatness (Arvystas & Shprintzen, 1984).

The posterior cranial fossa is the portion of the cranium that is posterior to the flexion of the skull base behind the sella turcica. Cerebellar hypoplasia and a smaller than normal cerebellar vermis are reported findings in individuals with 22q11.2 DS (Shprintzen & Golding-Kushner, 2008). The incidence of craniosynostosis in the 22q11.2 DS population is higher than in the general population. The incidence of craniosynostosis in the general population is 1/2500. The incidence of craniosynostosis in the 22q11.2 DS group has been reported to be 2/370 (McDonald-McGinn et al., 2005).

Cervical Spine

Cervical abnormalities have been reported on subjects with 22q11.2 DS compared to non-syndromic control groups. Veerapandiyan et al. (2011) reported cervical data on 21 subjects with 22q11.2. Compared to normative data, it was found that 19 out of 21 subjects with 22q11.2 DS presented with at least 1 cervical spine abnormality which included open posterior C1 arch, C2 swoosh (abnormal extension of lamina and posterior elements of axis superiorly), C2-C3 fusion, thin/small C1 (Heliovaara & Hurmerinta, 2006), C1 anterior arch abnormality (e.g., absent anterior arch, non-united arch, hypoplastic arch, dysmorphic anterior arch), and dysmorphic dens (C2). Data on 21 children with 22q11.2 compared to non-syndromic control group with complete unilateral cleft lip/palate revealed decreased C1 (atlas) and C2 (axis) length and height in those with 22q11.2 DS (Wang et al., 2009). Cervical variations may aggravate velopharyngeal insufficiency in the 22q11.2 DS population based on the ratio of nasopharyngeal depth and velar length (Veerapandiyan et al., 2011). Upper cervical spine abnormalities have a higher prevalence in individuals with craniofacial syndromes and may contribute to increased osseous pharyngeal depth and subsequent velopharyngeal dysfunction.

Oral Cavity

Contradictory findings have been reported regarding hard palate length in subjects with 22q11.2 DS, with studies indicating decreased hard palate length (Ruotolo et al., 2006; Wang et al., 2009) and an increased hard palate length (Heliovaara & Hurmerinta, 2006). Downturned oral commissures and microstomia are relatively common findings in the 22q11.2 DS population. Dalben Gda et al. (2010) assessed craniofacial morphology in 18 patients with 22q11.2 DS and compared findings to age- and sex-matched controls with no morphofunctional alterations. The 22q11.2 DS subjects were found to have increased interincisal dental angle and

greater lingual inclination of mandibular incisors. Studies have reported subjects with 22q11.2 DS to have increased maxillary length (Heliovaara & Hurmerinta, 2006), decreased posterior maxillary height (Dalben Gda et al., 2010), and retrognathia (Heliovaara & Hurmerinta, 2006). These subjects were found to have posteriorly diverged mandibles (Heliovaara & Hurmerinta, 2006), steep mandibular plane angle (Arvystas & Shprintzen, 1984; Glander & Cisneros, 1992) and decreased gonial angle (Dalben Gda et al., 2010).

Velopharyngeal Anatomy and Physiology in 22q11.2 DS

Velopharyngeal structure abnormalities are observed in approximately 75% of individuals with 22q11.2 DS (Chegar, Tatum, Marrinan, & Shprintzen, 2006).

Pharyngeal Anatomy

Reduced adenoid tissue, tonsillar hypertrophy, and reduced movement of lateral pharyngeal walls have been observed in nasoendoscopic investigations in subjects with 22q11.2 DS (Ysunza, Carmen Pamplona, & Santiago Morales, 2011). Heliovaara and Hurmerinta (2006) determined subjects with 22q11.2 DS had wide nasopharyngeal area (Veerapandiyan et al., 2011), narrow hypopharyngeal area, delayed development and reduced length of hyoid bone, and larger hyoidal gaps (fusion of hyoidal cornu major and base) compared to age- and sex-matched controls using cephalometric analyses. Conversely, data on 18 Brazilian subjects with 22q11.2 DS compared to age- and sex-matched control groups indicated subjects with 22q11.2 DS have no significant differences in depth of bony pharynx (distance between posterior nasal spine and basion), nasopharynx, and oropharynx (Dalben Gda et al., 2010). Due to lack of correlation between findings it is difficult to fully ascertain if velopharyngeal insufficiency can be attributed to larger pharyngeal dimensions as postulated by Arvystas and Shprintzen (1984). Studies have

attributed velopharyngeal insufficiency to pharyngeal functional etiology (e.g., pharyngeal hypotonia) rather than an anatomical etiology (Dalben Gda et al., 2010).

An MRI study assessed five children with 22q11.2 DS and comparisons were made to a control group consisting of 123 children with no history of velopharyngeal dysfunction (Ruotolo et al., 2006). Subjects with 22q11.2 DS were found to have increased (but not statistically significant) osseous pharyngeal depth (distance between posterior nasal spine and anterior body of C1), increased osseous pharyngeal depth to velar length ratio, more obtuse angle of superior-anterior quadrant, and increased velopharyngeal width (distance between lateral pharyngeal walls). The airway was found to be significantly more obtuse and voluminous.

Although pharyngeal hypotonia has been described as one of the most common findings in 22q11.2 DS, the etiology and extent of this hypotonia is unknown. A study investigated the thickness and histologic and histochemical properties of the superior pharyngeal constrictor in subjects with 22q11.2 DS using MRI and biopsy specimens (Zim et al., 2003). The superior pharyngeal constrictor muscle thickness was found to be significantly less in 26 subjects with 22q11.2 DS (2.03 mm) compared to age- and sex-matched controls without 22q11.2 DS (2.85mm). Histologic analyses on nine subjects (age range = 4-12 years) revealed subjects with 22q11.2 DS to have a significantly greater proportion of type 1 fibers (slow contraction with high resistance to fatigue) with significantly smaller muscle fiber diameters in the superior pharyngeal constrictor muscle, compared to superior pharyngeal constrictor muscle of three adult cadavers (age range = 80-86 years). Limitations of this study include the wide age range (3-29 years) and the restricted control group (substantially older adult cadavers for histological analyses). The wide age range does not account for the effects of growth on the superior pharyngeal constrictor muscle.

An investigation compared 49 syndromic subjects with Pierre-Robin sequence and Stickler syndrome (n = 20) and Pierre-Robin sequence with 22q11.2 DS (n = 29) with age- and sex-matched control group with Stickler and 22q11.2 DS with no Pierre-Robin sequence (Glander & Cisneros, 1992). Subjects in the 22q11.2 DS with Pierre-Robin group presented with increased airway width at nasopharyngeal level, increased width of oropharyngeal space (lower and middle), thinner posterior pharyngeal wall issue at nasopharyngeal level and upper oropharynx (Golding-Kushner, 1991), and increased lower pharyngeal height.

Palatal Anomalies

The most common forms of palatal abnormalities reported include submucous cleft palate (44%), occult submucous cleft palate (38%), and 18% present with overt cleft palate (Shprintzen, 2008; Veerapandiyan et al., 2011). It is uncommon that individuals with 22q11.2 DS demonstrate the classic triad of submucous cleft palate (bifid uvula, zona pellucida, and notched hard palate). Most often a submucous cleft palate is detected in these individuals orally due to presence of a bifid uvula with or without the other associated symptoms (Shprintzen & Golding-Kushner, 2008). In cases of occult submucous cleft palate, the anomalies of the velum are subtle. It may present as a gentle concavity, prominent midline depression, or a flat nasal surface of the velum.

Few studies have investigated the characteristics of the velum in individuals with 22q11.2 DS. A lateral cephalometry investigation (Veerapandiyan et al., 2011) reported subjects with 22q11.2 DS to have decreased velar length, and an abnormal anterior location of velar dimple. In normal subjects, the velar dimple was located at 80% of length of velum during phonation; in subjects with 22q11.2 DS, the velar dimple was located at 57.3% of the length of the velum during phonation. The anterior location of the velar dimple may reflect a more anterior location

of the levator muscle and the more anterior the velar dimple is located, the more likely the functional stretch of the velum is decreased, thus likely resulting in velopharyngeal insufficiency. Conversely, an MRI study (Ruotolo et al., 2006) found no significant variations in velar length and thickness among this clinical population. During speech in individuals with normal velopharyngeal anatomy, the thickening of the velum is due to the presence of the musculus uvulae (Shprintzen & Golding-Kushner, 2008). As the musculus uvula contracts during speech, it thickens at its muscle belly because it is not firmly attached at its distal end. The musculus uvulae may be absent in 22q11.2 DS and hence there may be an absence of thickening of the velum during palatal movement. However, the presence or absence of the musculus uvulae in this clinical population has not been examined.

Veerapandiyan et al. (2011) computed a need ratio in 22q11.2 DS subjects. The need ratio was computed by dividing nasopharyngeal depth by velar length. A value greater than 0.70 for the need ratio indicated an unfavorable relationship between nasopharyngeal depth and velar length and may be indicative of placing the individual at risk for velopharyngeal insufficiency. Results indicated 88% of subjects with 22q11.2 DS to have abnormally large need ratios (> 0.70). A significant difference in needs ratio was also observed for patients with and without C1 anterior arch abnormalities.

Two conference proceedings (Kuehn, 2003; Punjabi, Holshouser, D'Antonio, & Kuehn, 2002) reported using static MRI to evaluate the levator muscle. The authors observed anterior position of the levator fibers relative to the hard palate and an overall thin and hypoplastic levator sling. However, both reports were not published and therefore little information is known about the subject demographics and sample sizes. To date, only one research study has reported quantitative measures (i.e., thickness and symmetry) of the levator muscle in individuals with

22q11.2 DS (Park et al., 2015). However, limitations of the study include comparisons to individuals with submucous cleft palate.

Asymmetry of the Palate and Pharynx in 22q11.2 DS

Asymmetry in palatal and pharyngeal anatomy has been more recently reported. Chegar et al. (2006) assessed velar movement during speech in 121 subjects with 22q11.2 DS using endoscopy and videofluoroscopy. Results indicated 67% of subjects to demonstrate asymmetric elevation of the velum. The velar midline was found to be displaced to one or the other side. In a recent investigation, the thickness and symmetry of the levator muscle was investigated in 17 subjects with 22q11.2 DS using MRI (Park et al., 2015). All subjects were imaged under sedation. The comparison group consisted of nine subjects with submucous cleft palate without 22q11.2 DS. Results indicated that for each point for levator thickness, the non-syndromic submucous cleft palate group demonstrated greater thickness than the 22q11.2 DS group. Also, the difference between the right and left sides of muscle thickness in 22q11.2 DS group was larger (0.25mm) compared to non-syndromic submucous cleft palate group (0.09mm). The left side was significantly thicker than the right in 22q11.2 DS subjects.

Asymmetry has also been observed for pharyngeal structures, namely posterior pharyngeal and lateral pharyngeal wall movements in 76% subjects with 22q11.2 DS (Chegar et al., 2006). One side of the pharynx was found to have increased fullness over the other, with the right side manifesting more fullness than the left frequently. Individuals with 22q11.2 DS have reportedly minimal lateral pharyngeal wall movement. However, in instances where it is present, asymmetric lateral pharyngeal wall movement has been observed.

Speech Characteristics

The characteristics of voice, resonance, and articulation are important parameters in describing speech. About 10% of individuals with 22q11.2 DS have anterior laryngeal webbing (Shprintzen & Golding-Kushner, 2011). An anterior laryngeal web would decrease the vibrating length of the vocal folds, resulting in a higher pitched voice. Thin vocal folds would have a similar effect as well. The most common speech characteristic associated with 22q11.2 DS is hypernasality. Hypernasality occurs when there is excessive nasal resonance during vowel production. Velopharyngeal insufficiency is the most common cause of hypernasality. Velopharyngeal insufficiency may be caused due to a structural or neurologic issue which adversely affects the closure of the velopharyngeal mechanism. Several factors may predispose an individual with 22q11.2 DS to velopharyngeal insufficiency, including platybasia, palatal anomalies, thin velar and pharyngeal tissues, abnormal palatal and pharyngeal fibers, and adenoid hypoplasia.

An investigation of velopharyngeal closure timing variations in subjects with 22q11.2 DS (Baylis, Watson, & Moller, 2009) in comparison to non-syndromic cleft lip/palate group found that subjects with 22q11.2 DS presented with significantly increased duration for velopharyngeal closure (mean = 0.176 seconds) when compared to cleft lip/palate group (mean = 0.143 seconds). The subjects also presented with more severe hypernasality when compared to cleft lip/palate group and normal controls based on increased nasal airflow values during pressure flow assessment. It was noted that increased hypernasality was found even in the presence of a small velopharyngeal orifice size. A primary limitation of the study was a small sample size of the 22q11.2 DS group (n = 5). Similarly, Ysunza et al. (2011) reported these individuals to have hypernasal speech even in the absence of a palatal cleft. Additional speech characteristics

reported in subjects with 22q11.2 DS include articulation or phonological disorders, fast rate of speech, high pitch, and monotone (Kirschner & Baylis, 2014). The most common compensatory articulation error observed in these subjects is glottal stops (Kirschner & Baylis, 2014).

Speech Surgery and Outcomes

The goal of surgery is to eliminate velopharyngeal insufficiency and hypernasality and to create a normal valving system for speech and resonance. If hypernasality, nasal emission, and weak pressure persists in speech post-surgery, then the surgery has not achieved its goal. Surgery in 22q11.2 DS may be different due to the complex underlying morphological variations in this population as described in earlier sections. Surgical options for individuals with 22q11.2 DS may include Wardill push-back, Furlow palatoplasty, palatopharyngoplasty (using minimal levator incisions), pharyngeal flaps, and sphincter pharyngoplasties, and less common options including fat injections (Ysunza, Pamplona, Ortega, & Prado, 2008; Ysunza, Pamplona, Molina, & Hernandez, 2009).

Ysunza et al. (2009) evaluated surgical effectiveness in 29 patients with 22q11.2 DS and velopharyngeal insufficiency that underwent sphincter pharyngoplasties and superior pharyngeal flaps. In the pharyngeal flap cohort (n = 20), 85% subjects presented with normal resonance or mild hypernasality after surgical intervention and 15% demonstrated moderate hypernasality. For the sphincter pharyngoplasty group, none of the subjects demonstrated normal resonance or mild hypernasality post-surgery. Sixty-six percent of these subjects demonstrated moderate hypernasality and 3% had severe hypernasality. In individuals with 22q11.2 DS, pharyngeal flaps appeared to result in better speech outcomes compared to sphincter pharyngoplasties.

The sphincter pharyngoplasty procedure in the management of velopharyngeal insufficiency in 32 children with 22q11.2 DS has been investigated (Losken, Williams, Burstein, Malick, & Riski, 2006). Successful surgical outcomes were demonstrated in 78% of the 22q11.2 DS patients, with 22% requiring revisions. However, the revision rate in the 22q11.2 DS cohort was significantly higher (22%) compared to 218 non-22q11.2 DS patients with velopharyngeal insufficiency group (11%). Objective speech data obtained preoperatively showed subjects with 22q11.2 DS to demonstrate significantly greater velopharyngeal incompetence as demonstrated by nasalance scores, pressure-flow measurements, and radiographic measurements. In individuals with 22q11.2 DS, the revision rates for sphincter pharyngoplasty were reported to be twice as high when compared to non-syndromic cleft palate cases (Witt, Cohen, Grames, & Marsh, 1999).

Speech outcomes after surgical intervention for velopharyngeal insufficiency has been assessed in the 22q11.2 DS population (Milczuk, Smith, & Brockman, 2007). The study assessed parameters such as speech intelligibility, resonance, nasal air emissions, and overall severity of velopharyngeal insufficiency in 14 children with 22q11.2 DS. The comparison group included 15 children with overt cleft palate who underwent surgery for velopharyngeal insufficiency. Sphincter pharyngoplasty, Furlow palatoplasty, or a combination of both was chosen as operative procedures determined based on pre-surgical endoscopic assessments. Similar improvements were observed for both groups except in the case of speech resonance, where results were consistently far worse compared to individuals with non-syndromic cleft palate. In a retrospective review of four individuals with 22q11.2 DS who underwent Furlow double-opposing Z-palatoplasty for primary repair, it was reported that none demonstrated adequate velopharyngeal closure (D-Antonio, Davio, Zoller, Punjabi, & Hardesty, 2001).

A study reporting the results of palatal lengthening for velopharyngeal insufficiency in 22q11.2 DS patients found a success rate of 84% (Widdershoven, Stubenitsky, Breugem, & MinkvanderMolen, 2008). The authors compared surgical correction outcomes for velopharyngeal insufficiency in 25 patients with 22q11.2 DS and 32 patients without 22q11.2 DS. However, discrepancies were noted between nasal endoscopy results and improvements in speech. These results suggest mechanical improvements do not necessarily result in functional improvements (i.e., speech) in this challenging population. These findings also illustrate the complexity of speech disorders found in individuals with 22q11.2 DS.

A recent study conducted a retrospective review of long-term, post-operative outcomes in 132 patients with syndromic diagnoses who underwent primary modified Furlow palatoplasty (Basta et al., 2014). The two most common syndromes in the subject demographic included Stickler syndrome (n=32) and 22q11.2 DS (n=19). The 22q11.2 DS group demonstrated significantly poorer postoperative outcomes compared to other syndromes. Fifty percent of the 22q11.2 DS cohort had borderline speech and none had competent speech. Subjects in the 22q11.2 DS group presented with a three-fold higher need for secondary velopharyngeal insufficiency surgery. Certain studies have demonstrated fairly similar, good outcomes in patients with 22q11.2 DS and non-syndromic patients. However, persistent velopharyngeal dysfunction post-surgical intervention appears to be a common characteristic in this clinically complex population.

MRI Investigations of the Velopharynx in 22q11.2 DS

Magnetic resonance imaging is the only imaging modality that allows visualization of the internal musculature *in vivo*. Studies have examined the levator muscle in adults with normal

anatomy (Bae, Kuehn, Sutton, Conway, & Perry, 2011; Ettema, Kuehn, Perlman, & Alperin, 2002; Perry, Kuehn, & Sutton, 2013; Perry, Kuehn, Sutton, Gamage, & Fang, 2014; Tian & Redett, 2009), adults with cleft palate anatomy (Ha, Kuehn, Cohen, & Alperin, 2007), children with normal and cleft palate anatomy (Kollara & Perry, 2014; Kollara et al., 2016; Tian et al., 2010; Tian et al., 2010), and infants with normal and cleft palate anatomy (Kuehn, Ettema, Goldwasser, & Barkmeier, 2004; Perry, Kuehn, Sutton, Goldwasser, & Jerez, 2011).

Studies have utilized MRI in investigating the velopharyngeal area in individuals with 22q11.2 DS (Park et al., 2015; Ruotolo et al., 2006). The study by Ruotolo et al. (2006) included only five subjects across dissimilar periods of growth and the results were compared with an unpaired control group. In the investigation by Park et al. (2015), the control group consisted of subjects with submucous cleft palate. Both of these studies were carried out under sedation. Our preliminary investigations included in chapters three, four, and five (Kollara & Perry, 2014; Kollara et al., 2014; Kollara, Schenck, & Perry, 2016) demonstrate the feasibility of MRI without the use of sedation.

REFERENCES

- Arvystas, M., & Shprintzen, R. J. (1984). Craniofacial morphology in the velo-cardio-facial syndrome. *Journal of Craniofacial Genetics and Developmental Biology*, 4(1), 39-45.
- Bae, Y., Kuehn, D. P., Sutton, B. P., Conway, C. A., & Perry, J. L. (2011). Three-dimensional magnetic resonance imaging of velopharyngeal structures. *Journal of Speech, Language, and Hearing Research*, 54(6), 1538-1545. doi:10.1044/1092-4388(2011/10-0021) [doi]
- Basta, M. N., Silvestre, J., Stransky, C., Solot, C., Cohen, M., McDonald-McGinn, D., . . . Jackson, O. A. (2014). A 35-year experience with syndromic cleft palate repair: Operative outcomes and long-term speech function. *Annals of Plastic Surgery*, 73 Suppl 2, S130-5. doi:10.1097/SAP.0000000000000286 [doi]
- Baylis, A. L., Watson, P. J., & Moller, K. T. (2009). Structural and functional causes of hypernasality in velocardiofacial syndrome. A pilot study. *Folia Phoniatrica Et Logopaedica*, 61(2), 93-96. doi:10.1159/000209252 [doi]
- Chegar, B. E., Tatum, S. A., 3rd, Marrinan, E., & Shprintzen, R. J. (2006). Upper airway asymmetry in velo-cardio-facial syndrome. *International Journal of Pediatric Otorhinolaryngology*, 70(8), 1375-1381. doi:S0165-5876(06)00059-0 [pii]
- Dalben Gda, S., Richieri-Costa, A., & Taveira, L. A. (2010). Craniofacial morphology in patients with velocardiofacial syndrome. *Cleft Palate-Craniofacial Journal*, 47(3), 241-246. doi:10.1597/08-278.1 [doi]
- D-Antonio, L. L., Davio, M., Zoller, K., Punjabi, A., & Hardesty, R. A. (2001). Results of furrow Z-plasty in patients with velocardiofacial syndrome. *Plastic and Reconstructive Surgery*, 107(4), 1077-1079.
- Ettema, S. L., Kuehn, D. P., Perlman, A. L., & Alperin, N. (2002). Magnetic resonance imaging of the levator veli palatini muscle during speech. *Cleft Palate-Craniofacial Journal*, 39(2), 130-144. doi:10.1597/1545-1569(2002)039<0130:MRIOTL>2.0.CO;2 [doi]
- Glander, K., 2nd, & Cisneros, G. J. (1992). Comparison of the craniofacial characteristics of two syndromes associated with the pierre robin sequence. *Cleft Palate-Craniofacial Journal*, 29(3), 210-219. doi:10.1597/1545-1569(1992)029<0210:COTCCO>2.3.CO;2 [doi]
- Golding-Kushner, K. (1991). *Craniofacial morphology and velopharyngeal physiology in four syndromes of clefting*. (Unpublished doctoral dissertation). City University of New York, NY.
- Ha, S., Kuehn, D. P., Cohen, M., & Alperin, N. (2007). Magnetic resonance imaging of the levator veli palatini muscle in speakers with repaired cleft palate. *Cleft Palate-Craniofacial Journal*, 44(5), 494-505. doi:06-220 [pii]

- Heliövaara, A., & Hurmerinta, K. (2006). Craniofacial cephalometric morphology in children with CATCH 22 syndrome. *Orthodontics & Craniofacial Research*, 9(4), 186-192. doi:OCR373 [pii]
- Kirschner, R. E., & Baylis, A. L. (2014). Surgical considerations in 22Q11.2 deletion syndrome. *Clinics in Plastic Surgery*, 41(2), 271-282. doi:10.1016/j.cps.2013.12.002 [doi]
- Kollara, L., & Perry, J. L. (2014). Effects of gravity on the velopharyngeal structures in children using upright magnetic resonance imaging. *Cleft Palate-Craniofacial Journal*, 51(6), 669-676. doi:10.1597/13-107 [doi]
- Kollara, L., Perry, J. L., & Hudson, S. (2016). Racial variations in velopharyngeal and craniometric morphology in children: An imaging study. *Journal of Speech, Language, and Hearing Research*, 59(1), 27-38. doi:10.1044/2015_JSLHR-S-14-0236 [doi]
- Kollara, L., Schenck, G. C., Perry, J. L., & Jaskolka, M. (2016). Examining A New Method to Studying Velopharyngeal Structures in A Child with 22q11.2 DS. *Manuscript in Preparation*
- Kuehn, D. P. (2003). MRI investigation of VCFS. *American Cleft Palate Craniofacial Association Annual Meeting*, Greenville, SC.
- Kuehn, D. P., Ettema, S. L., Goldwasser, M. S., & Barkmeier, J. C. (2004). Magnetic resonance imaging of the levator veli palatini muscle before and after primary palatoplasty. *Cleft Palate-Craniofacial Journal*, 41(6), 584-592. doi:03-060 [pii]
- Losken, A., Williams, J. K., Burstein, F. D., Malick, D. N., & Riski, J. E. (2006). Surgical correction of velopharyngeal insufficiency in children with velocardiofacial syndrome. *Plastic and Reconstructive Surgery*, 117(5), 1493-1498. doi:10.1097/01.prs.0000206377.14083.ce [doi]
- McDonald-McGinn, D. M., Gripp, K. W., Kirschner, R. E., Maisenbacher, M. K., Husted, V., Schauer, G. M., . . . Zackai, E. H. (2005). Craniosynostosis: Another feature of the 22q11.2 deletion syndrome. *American Journal of Medical Genetics. Part A*, 136A(4), 358-362. doi:10.1002/ajmg.a.30746 [doi]
- Milczuk, H. A., Smith, D. S., & Brockman, J. H. (2007). Surgical outcomes for velopharyngeal insufficiency in velocardiofacial syndrome and nonsyndromic patients. *Cleft Palate-Craniofacial Journal*, 44(4), 412-417. doi:05-136 [pii]
- Nachmani, A., Aizenbud, D., Berger, G., Berger, R. L., Hazan-Molina, H., & Finkelstein, Y. (2013). The prevalence of platybasia in patients with velopharyngeal incompetence. *Cleft Palate-Craniofacial Journal*, 50(5), 528-534. doi:10.1597/11-265 [doi]
- Park, M., Ahn, S. H., Jeong, J. H., & Baek, R. M. (2015). Evaluation of the levator veli palatini muscle thickness in patients with velocardiofacial syndrome using magnetic resonance

- imaging. *Journal of Plastic, Reconstructive & Aesthetic Surgery*, doi:S1748-6815(15)00191-6 [pii]
- Perry, J. L., Kuehn, D. P., & Sutton, B. P. (2013). Morphology of the levator veli palatini muscle using magnetic resonance imaging. *Cleft Palate-Craniofacial Journal*, 50(1), 64-75. doi:10.1597/11-125 [doi]
- Perry, J. L., Kuehn, D. P., Sutton, B. P., Gamage, J. K., & Fang, X. (2014). Anthropometric analysis of the velopharynx and related craniometric dimensions in three adult populations using MRI. *Cleft Palate-Craniofacial Journal*, doi:10.1597/14-015 [doi]
- Perry, J. L., Kuehn, D. P., Sutton, B. P., Goldwasser, M. S., & Jerez, A. D. (2011). Craniometric and velopharyngeal assessment of infants with and without cleft palate. *Journal of Craniofacial Surgery*, 22(2), 499-503. doi:10.1097/SCS.0b013e3182087378 [doi]
- Punjabi, A., Holshouser, B. A., D'Antonio, L. L., & Kuehn, D. P. (2002). Magnetic resonance imaging of the velopharynx in patients with velocardiofacial syndrome. *American Cleft Palate Craniofacial Association Annual Meeting*, Seattle, WA.
- Ruotolo, R. A., Veitia, N. A., Corbin, A., McDonough, J., Solot, C. B., McDonald-McGinn, D., . . . Kirschner, R. E. (2006). Velopharyngeal anatomy in 22q11.2 deletion syndrome: A three-dimensional cephalometric analysis. *Cleft Palate-Craniofacial Journal*, 43(4), 446-456. doi:04-193R [pii]
- Shprintzen, R. J. (2008). Velo-cardio-facial syndrome: 30 years of study. *Developmental Disabilities Research Reviews*, 14(1), 3-10. doi:10.1002/ddrr.2 [doi]
- Shprintzen, R. J., Goldberg, R. B., Lewin, M. L., Sidoti, E. J., Berkman, M. D., Argamaso, R. V., & Young, D. (1978). A new syndrome involving cleft palate, cardiac anomalies, typical facies, and learning disabilities: Velo-cardio-facial syndrome. *The Cleft Palate Journal*, 15(1), 56-62.
- Shprintzen, R. J., & Golding-Kushner, K. (2008). *Velo-cardio-facial syndrome volume I* Plural Publishing.
- Shprintzen, R. J., & Golding-Kushner, K. (2011). *Velo-cardio-facial syndrom volume II treatment of communication disorders* Plural Publishing.
- Spruijt, N. E., Kon, M., & Mink van der Molen, A. B. (2014). Platybasia in 22q11.2 deletion syndrome is not correlated with speech resonance. *Archives of Plastic Surgery*, 41(4), 344-349. doi:10.5999/aps.2014.41.4.344 [doi]
- Tian, W., Li, Y., Yin, H., Zhao, S. F., Li, S., Wang, Y., & Shi, B. (2010). Magnetic resonance imaging assessment of velopharyngeal motion in chinese children after primary palatal repair. *Journal of Craniofacial Surgery*, 21(2), 578-587. doi:10.1097/SCS.0b013e3181d08bee [doi]

- Tian, W., & Redett, R. J. (2009). New velopharyngeal measurements at rest and during speech: Implications and applications. *Journal of Craniofacial Surgery*, 20(2), 532-539. doi:10.1097/SCS.0b013e31819b9f9e [doi]
- Tian, W., Yin, H., Li, Y., Zhao, S., Zheng, Q., & Shi, B. (2010). Magnetic resonance imaging assessment of velopharyngeal structures in chinese children after primary palatal repair. *Journal of Craniofacial Surgery*, 21(2), 568-577. doi:10.1097/SCS.0b013e3181d08bd1 [doi]
- Veerapandiyan, A., Blalock, D., Ghosh, S., Ip, E., Barnes, C., & Shashi, V. (2011). The role of cephalometry in assessing velopharyngeal dysfunction in velocardiofacial syndrome. *Laryngoscope*, 121(4), 732-737. doi:10.1002/lary.21449 [doi]
- Wang, K., Yang, Y., Shen, F., Tao, J., Xu, H., Portnof, J. E., . . . Salyer, K. E. (2009). Utilization of three-dimensional computed tomography for craniofacial phenotypic analysis in children with velocardiofacial syndrome. *Journal of Craniofacial Surgery*, 20(6), 2013-2019. doi:10.1097/SCS.0b013e3181bd2e34 [doi]
- Widdershoven, J. C., Stubenitsky, B. M., Breugem, C. C., & MinkvanderMolen, A. B. (2008). Outcome of velopharyngoplasty in patients with velocardiofacial syndrome. *Archives of Otolaryngology--Head & Neck Surgery*, 134(11), 1159-1164. doi:10.1001/archotol.134.11.1159 [doi]
- Witt, P., Cohen, D., Grames, L. M., & Marsh, J. (1999). Sphincter pharyngoplasty for the surgical management of speech dysfunction associated with velocardiofacial syndrome. *British Journal of Plastic Surgery*, 52(8), 613-618. doi:10.1054/bjps.1999.3168 [doi]
- Ysunza, A., Carmen Pamplona, M., & Santiago Morales, M. A. (2011). Velopharyngeal valving during speech, in patients with velocardiofacial syndrome and patients with non-syndromic palatal clefts after surgical and speech pathology management. *International Journal of Pediatric Otorhinolaryngology*, 75(10), 1255-1259. doi:10.1016/j.ijporl.2011.07.001 [doi]
- Ysunza, A., Pamplona, M. C., Molina, F., & Hernandez, A. (2009). Surgical planning for restoring velopharyngeal function in velocardiofacial syndrome. *International Journal of Pediatric Otorhinolaryngology*, 73(11), 1572-1575. doi:10.1016/j.ijporl.2009.08.007 [doi]
- Ysunza, A., Pamplona, M. C., Ortega, J. M., & Prado, H. (2008). Video fluoroscopy for evaluating adenoid hypertrophy in children. *International Journal of Pediatric Otorhinolaryngology*, 72(8), 1159-1165. doi:10.1016/j.ijporl.2008.03.022 [doi]
- Zim, S., Schelper, R., Kellman, R., Tatum, S., Ploutz-Snyder, R., & Shprintzen, R. (2003). Thickness and histologic and histochemical properties of the superior pharyngeal constrictor muscle in velocardiofacial syndrome. *Archives of Facial Plastic Surgery*, 5(6), 503-510. doi:10.1001/archfaci.5.6.503 [doi]

CHAPTER 3

STUDY I

Effects of Gravity on the Velopharyngeal Structures in Children Using Upright Magnetic Resonance Imaging¹

ABSTRACT

The influence of gravity on the velopharyngeal structures in children is unknown. The purpose of this study is to compare the velopharyngeal mechanism in the upright and supine positions while at rest and during sustained speech production in children between 4 and 8 years old. A 0.6 Tesla open-type, multipositional magnetic resonance imaging scanner was used to image subjects in the upright and supine positions. The scanning protocol included a T2 fluid attenuation inversion recovery and an oblique coronal turbo spin echo scan with short scanning durations (7.9 seconds) to enable visualization of the velopharyngeal anatomy during rest and production of sustained /i/ and /s/. The magnetic resonance imaging protocol used for this study enabled successful visualization of the velopharyngeal anatomy in the sagittal and oblique coronal planes at rest and during sustained phonation of /i/ and /s/. Positional differences demonstrated a small nonsignificant ($p > .05$) variation for velar measures (length, thickness, and height), retrovelar space, and levator veli palatini measures (length and angles of origin). Gravity had a negligible effect on velar length, velar thickness, velar height, retrovelar space, levator muscle length, and levator angles of origin. Supine imaging data can be translated to an upright activity such as speech. This is the first study to provide normative levator muscle lengths for

¹ Kollara, L., & Perry, J. L. (2014). Effects of gravity on the velopharyngeal structures in children using upright magnetic resonance imaging. *Cleft Palate-Craniofacial Journal*, 51(6), 669-676.

children between 4 and 8 years old. Upright imaging may be a promising tool for difficult-to-test populations.

INTRODUCTION

Speech is a dynamic process typically produced in the upright position. The structures that constitute the velopharyngeal port play an important role in speech production, swallowing, and breathing. The velopharyngeal mechanism includes the velum, lateral pharyngeal walls, and posterior pharyngeal wall. Velopharyngeal closure is accomplished through the combined action of several velopharyngeal muscles, the most important being the bilateral levator veli palatini (levator) muscle. The levator, palatoglossus, and palatopharyngeus muscles are collectively responsible for determining the velopharyngeal positioning in the pharyngeal cavity (Moon and Canady, 1995). Structural characteristics alone cannot determine the functional status of the velopharyngeal mechanism (Tian et al., 2010b). Magnetic resonance imaging (MRI) data are traditionally obtained in the supine position but these data may be applied to an activity in the upright position, such as speech. Assessment of the velopharyngeal structures during speech in the upright position is important. Better understanding of gravitational effects on the velopharyngeal structures will allow better utilization of MRI data in speech analysis and modeling (Stone et al., 2007).

Studies have examined the effect of gravity on swallowing and speech structures, including the respiratory apparatus, tongue, hyoid bone, pharyngeal areas, and velopharyngeal structures. Hoit (1994) observed that during speech breathing in the supine position, inspiration was dependent on the efforts of the diaphragm and expiration on the efforts of the rib cage. In

upright speech breathing, inspiration involves effects of the diaphragm and abdomen, but the latter predominates for expiration.

The effects of body position on swallowing have been studied. Perry et al. (2012) noted variations in the initiation of the pharyngeal swallow and coordinated velar elevation during a liquid swallow (7 cc). In the supine position, the velum continues to elevate after initiation of the pharyngeal swallow. In the upright position, the velum comes to a fully elevated position at nearly the same time as the pharyngeal swallow is initiated.

Buchaillard and Perrier (2009) found negligible differences in tongue shape and formant values between the upright and supine positions during production of French cardinal vowels. The absence of significant differences was attributed to the model having a fixed jaw position in both the upright and supine orientation. Badin et al. (2002) demonstrated increased backward displacement of the tongue for consonants and vowels in the supine position using MRI compared with the upright position on cineradiofilm images. The increased backward tongue displacement was attributed to tongue weight. Stone et al. (2007) observed acoustic spectra (formant frequencies) to be preserved despite varying tongue responses to gravity. Results indicated a significant subject effect. Stone et al. (2007) hypothesized a compensatory response of the tongue to gravity in which the tongue counteracts to body position to preserve the acoustic effect.

Oropharyngeal structures appear to be affected by gravitational influences. Suttiprapaporn et al. (2008) studied gravity-induced changes in the oropharyngeal structures using computed tomography scans on clinically normal adult subjects. The soft palate, epiglottis, and entrance of the esophagus moved caudally with the positional change from supine to seated

upright and moved posteriorly when the position changed from an upright to a supine position. Kitamura et al. (2005) assessed the influence of body position on vowel articulation using an open-type MRI scanner. It was noted that in the supine position, the tongue was more retracted (particularly for back vowels), the lips were thinner, and the lower end of the uvula turned downward in the direction of gravity.

Variations in velopharyngeal structures as a result of body position have been investigated. An electromyographic study was conducted on 19 adults to examine the effects of gravity on activation levels of the levator and palatoglossus muscles during speech (Moon and Canady, 1995). Less peak (muscle) activity was observed in the supine position (gravity working in the same direction) compared with the upright position. Peak intraoral pressure and peak palatoglossus electromyographic activity showed no significant differences between upright and supine positions. The peak levator electromyographic activity showed significant differences between both positions. Perry (2011b) reported the effect of gravity on velopharyngeal structures using open-type multiposition MRI on four adult women. The subjects were imaged at rest and during two speech tasks (/i/ and /s/) in upright and supine positions. Differences in velar height during /i/ production between the two positions were significant for all subjects. There were no significant differences in velar thickness. Greater levator muscle shortening was observed on images obtained at rest (2.8 mm). Minimal variations were observed between upright and supine positions for velar measures (length and thickness), pharyngeal measures (retrovelar and retrolingual), and levator muscle measures (length and angle of origin). The overall results demonstrated that the velopharyngeal structures were not affected by gravity during speech for this select population.

No upright MRI studies have examined the influence of positional changes in the velopharyngeal musculature in children. The purpose of this study was to compare velopharyngeal structures in the supine and upright positions during rest and sustained speech production in children (4–8 years old) with clinically normal anatomy. The study further demonstrates the feasibility of using upright MRI in evaluating the velopharyngeal characteristics of young children.

METHOD

Subjects

In accordance with the institutional review board at East Carolina University, 12 healthy children (five boys and seven girls) between 4 and 8 years old (mean, 6.23 \pm 1.27) were recruited to participate in the study. The mean height was 41.67 inches (SD, 4.60 inches) and mean weight was 20.42 lb (SD, 4.19 lb). Of the 12 subjects, nine were black and three were white. Although racial differences have been shown to affect velar length and thickness and angle of origin for the levator muscle, the effects of race are not significant for the levator muscle (Perry et al., 2013). The selected age range (4–8 years) is the critical age for determining secondary surgical needs in cleft palate and for speech, language, and communication development. Subjects were recruited by flyers placed throughout the community. A coloring book was mailed to the prospective subject 2–3 weeks before the MRI exam. The coloring book allowed the subject to become familiar with the process of an MRI exam. An oral mechanism examination and oral to nasal resonance balance assessment was administered on all subjects by a speech language pathologist.

All subjects were native English speakers and had no history of craniofacial anomalies, musculoskeletal disorders, swallowing disorders, sleep apnea, or neurologic disorders that

could potentially affect the regions of interest for the study. All subjects had a body mass index under 19 (mean, 18.63 \pm 3.01) to control for possible variations in the velopharyngeal area as a result of obesity.

Magnetic Resonance Imaging

MRI data were obtained using a 0.6 Tesla open-type multiposition MRI scanner (Fonar Corporation, Melville, NY) at Triangle Orthopaedic Associates, PA (Southpoint, Durham, NC). The scanner enabled multipositional imaging in the upright and supine positions. The subjects had to be positioned only once during the entire scanning session. The start position was alternated between subjects. The scanning bed allowed for a 90° rotation, which enabled each subject to be rotated the same exact degree.

Numerous steps were taken to ensure the comfort of the child during the scan. Before starting the MRI exam, the child was introduced to the sounds of the MRI scanner by listening to audio samples of MRI noise played on an iPad. The recordings were the same noises that they could expect to hear during the MRI scan. The subjects were given a panic button and were frequently asked about their comfort level. An adult (parent or researcher) was in the scanning room during the entire scan. Children were encouraged to watch another child being imaged before them and were provided 5 minutes before their respective MRI scans to explore the MRI machine (e.g., walk around the scanner). A head device with soft sponges and pressure clamps was used to minimize head movement. The subjects had a soft sponge on their lap to wrap their hands around and a sponge in which to place their feet to minimize hand and foot movements, which can create motion artifacts for the head. Head movement was further reduced by allowing the subjects to watch cartoons on the television while the scan was in progress. This enabled

them to maintain a consistent forward gaze, minimizing any distractions. A speaker microphone between the control room and the scanning room enabled the examiner to communicate with the subject throughout the exam.

The imaging protocol was modeled after a similar, previously published study on adult women (Perry, 2011b); however, shorter length of time was used for each scan. This ensured standardization and comparability between results obtained in the adult (Perry, 2011b) and child population. The scanning protocol (Table A1) included a three-plane localizer, midsagittal T2 fluid attenuation inversion recovery and an oblique coronal turbo spin echo scan. The plane that most clearly depicted the genu of the corpus callosum, hypophysis, and outline of the fourth ventricle was selected as the midsagittal plane. The levator muscle region was obtained by drawing an oblique coronal line through the midsagittal image. The oblique coronal slice, which depicted the levator muscle sling in its full thickness from origin to insertion, was selected. The sagittal and oblique coronal scans were obtained while the subject was at rest and during sustained /i/ and /s/ production. The scans were conducted in both upright and supine positions.

Table A1.

Scanning protocol (0.6 Tesla). TR = repetition time; TE = echo time

| | Perry 2011b (Adult females) | Current study (Children) |
|---|------------------------------------|---------------------------------|
| Sagittal T2-Fluid attenuation inversion recovery (FLAIR) | | |
| <i>TR; TE</i> | 7136.604ms; 92.5ms | 987ms; 160ms |
| <i>Slice thickness</i> | 4.8mm | 5mm |
| <i>Spacing</i> | 0.36mm | 0mm |
| <i>No. of slices</i> | 1 | 3 |
| <i>Length of scan</i> | 2min 7 sec | 7.9 secs |
| Oblique coronal turbo spin echo (TSE) | | |
| <i>TR; TE</i> | 3686.304ms; 22ms | 987ms; 160ms |
| <i>Slice thickness</i> | 2.5mm | 5mm |
| <i>Spacing</i> | 0.1mm | .37mm |
| <i>No. of slices</i> | 6 | 3 |
| <i>Length of scan</i> | 3min 9 sec | 7.9secs |

Speech Tasks

Subjects were instructed to produce /i/ and /s/ in the upright and supine positions. Both speech productions were practiced by the subject with the examiner before starting the MRI exam. Subjects were instructed to produce /s/ as “ssss” (single consonant) and not “eees” (vowel-consonant combination). Subjects maintained a sustained production for the duration of the sound (7.9 seconds in oblique coronal and in midsagittal). Subjects were instructed to inhale deeply before initiating the speech sound production. Speech sound productions were carefully monitored by the researcher in the scanning room to ensure that it was an accurate representation of the required sound and was sustained for the duration of the scan.

Regions of Interest

A total of six measures were made from sagittal and oblique coronal images using Amira (version 5.4.5, Visage Imaging, Berlin, Germany) visualization software. Measurements were obtained in both upright and supine positions. Midsagittal measures (Table A2; Fig. A1) included velar length, velar thickness, velar height, and retrovelar space. Velar length was measured as a curvilinear line from the posterior nasal spine to the tip of the uvula. The distance between the velar dimple to the velar knee was measured as the velar thickness. Velar height was measured as the vertical displacement of the velar knee from a reference line through the hard palate. The distance between the velar knee to posterior pharyngeal wall was measured as the retrovelar space.

Table A2.

Description of Measurements (Perry, 2011b)

| <i>Measure</i> | <i>Definition</i> |
|-------------------------------------|--|
| Velar length | Distance of a curvilinear line starting at the posterior nasal spine, coursing through the middle of the cross sectioned velum, to the tip of the uvula. |
| Velar thickness | Distance from the velar knee to the velar dimple. |
| Velar height | Vertical distance of the velar knee from a reference line drawn directly through the hard palate to the posterior pharyngeal wall. |
| Retrovelar space | Distance from the velar knee to the posterior pharyngeal wall. |
| Levator veli palatini muscle length | Distance from the origin of the muscle at the base of the skull, through the middle of the muscle belly, and to the midline insertion at the velum. |
| Angle of origin | Angle created between a reference line connecting the two origins of the levator muscle and the line drawn to measure the levator muscle length. |

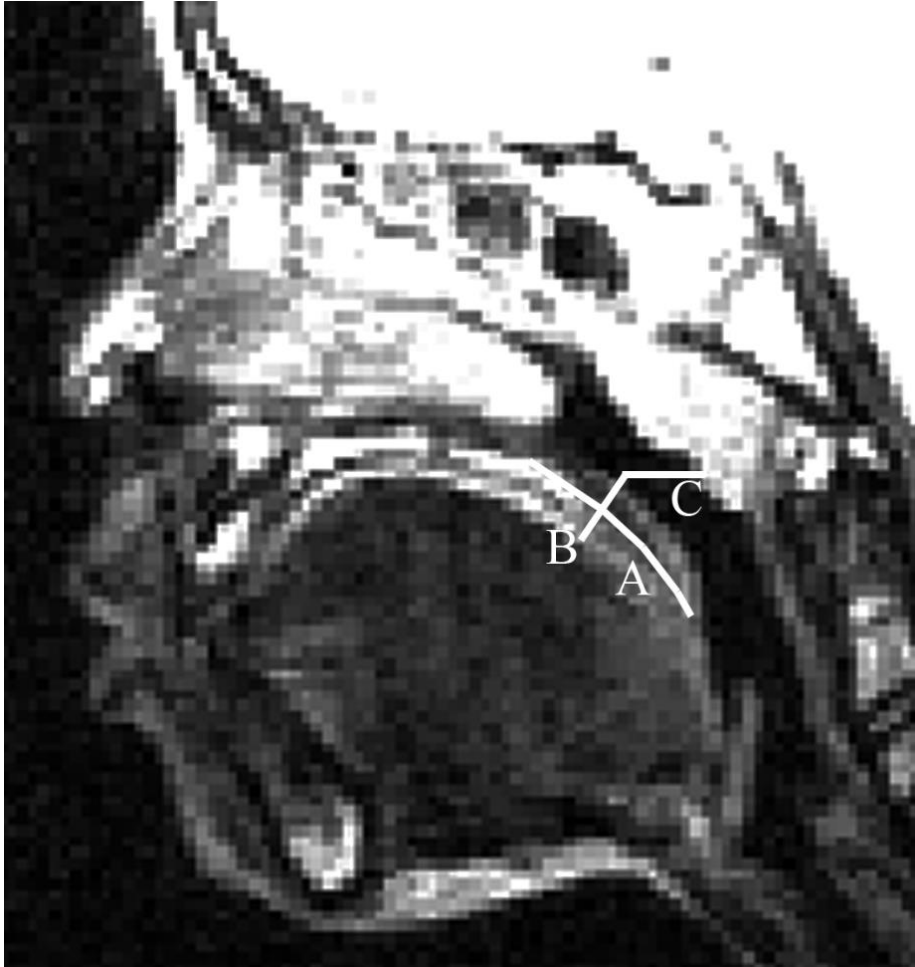


Figure A1. Demonstration of the velar measures and retrovelar space in the midsagittal image plane. A = velar length, B = velar thickness, C = velar height

The levator muscle length and angle of origin were measured on the oblique coronal images (Fig. 2). The levator length was calculated as the curvilinear distance from the origin at the base of the skull to the insertion in the middle of the velum. The total levator length was determined by adding the right and left levator lengths and calculating the average. A reference line was then drawn between the two origin points on the right and left muscle bundles. The angle formed between this reference line and the levator length at the point of its origin was

determined as the angle of origin. The measurement definitions and boundaries used were the same as those described for a similar study on adult women (Perry, 2011b) to ensure consistency in measurements in the adult and child populations.

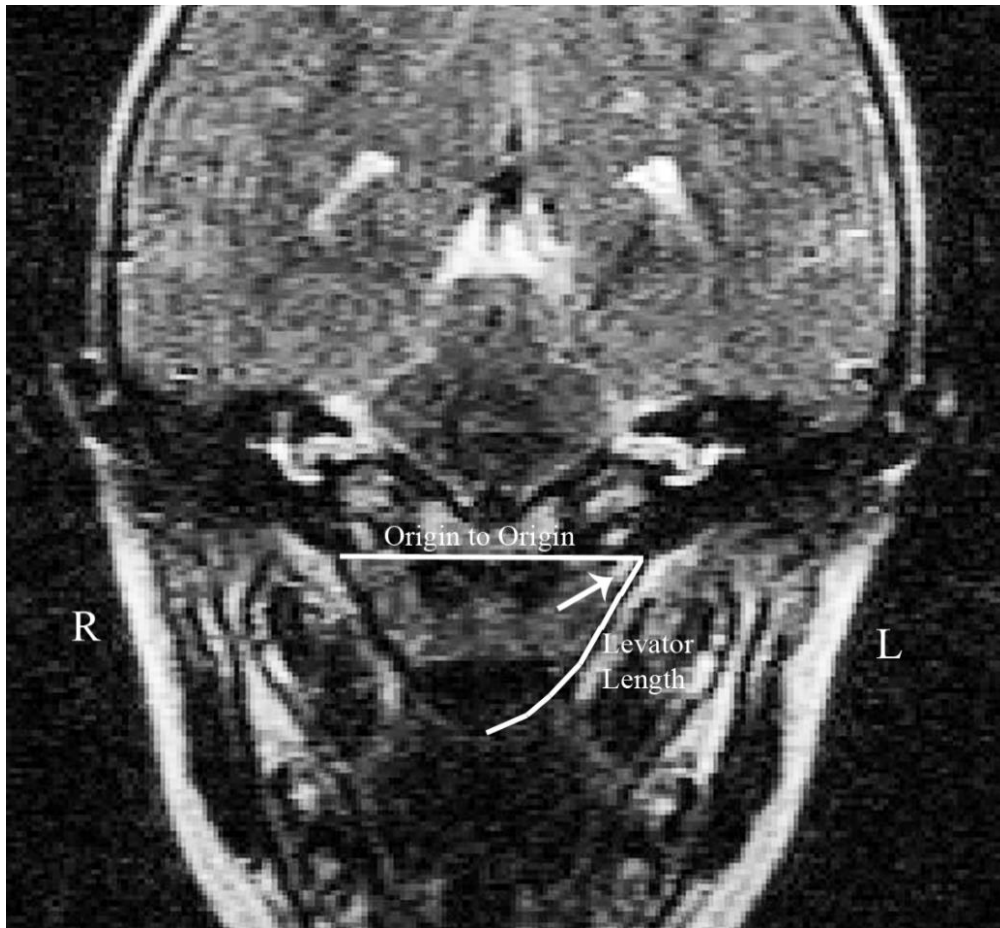


Figure A2. Measures taken on the oblique coronal image plane. The curvilinear white line courses through the levator muscle bundle. The arrow points to the angle of origin, which is determined by using a reference line connecting the levator muscle origins on the right and left sides.

Statistical Methods

Comparisons between the upright and supine positions for each measure were performed using a paired *t* test. The Bonferroni correction was used to minimize the effect of multiple comparisons and to control for type I error. The significance thus calculated equaled $0.05/c$ (where c = number of comparisons), resulting in a .002 level of significance.

The Pearson product moment correlation ($p = 0.05$) was used to establish interrater and intrarater reliability measures. Measurements were done on six randomly selected data sets by the primary and secondary raters 4 weeks after the first measures were obtained. Both raters made independent measures on a previous data set before starting data analysis. Clear definitions of the measurement boundaries were made and confirmed on practice data sets 5 weeks before starting data analysis. Both raters have prior experience in measuring the areas and structures in this study. The interrater and intra-rater reliability ranged from $r = .97$ to $r = .99$.

RESULTS

The MRI protocol used for this study was successful in visualizing the velopharyngeal structures of interest in the sagittal and oblique coronal planes. All subjects who agreed to participate successfully completed the imaging protocol. Clear images of the tongue, velum, and pharyngeal cavity were obtained. Changes in velar movement across different tasks (at rest and on phonation) were analyzed. The differences due to body position across the six measures are shown in Table A3. These measures indicate that changes in body position (from upright to supine) had a nonsignificant effect on differences in the velopharyngeal structures of interest in this study during rest and phonation tasks.

Table A3.

Group means and differences across all six measures. All measures of length are in mm and the angle of origin is reported in degrees. For the difference values, plus (+) values indicate a greater value in the upright position and minus (-) values indicate a lesser value in the upright position. * $\alpha = 0.002$

| <i>Measures</i> | <i>Rest</i> | | <i>/i/</i> | | <i>/s/</i> | | <i>p-value (Upright: Supine)</i> |
|-----------------------|-------------------------------|------------------------|------------------------------|------------------------|------------------------------|------------------------|--|
| | <i>(Upright ; Supine)</i> | <i>Differ ence</i> | <i>(Upright; Supine)</i> | <i>Differ ence</i> | <i>(Upright; Supine)</i> | <i>Differ ence</i> | |
| Velar length | 26.92; 27.44 | + 0.52 | 24.87; 25.46 | + 0.59 | 24.09; 25.13 | + 1.04 | 0.004 |
| Velar thickness | 7.97; 7.86 | - 0.11 | 6.90; 6.73 | - 0.17 | 6.63; 6.74 | + 0.11 | 0.750 |
| Velar height | 4.60; 4.50 | - 0.1 | 3.32; 3.10 | - 0.22 | 2.49; 2.62 | + 0.13 | 0.795 |
| Retrovelar space | 7.05; 7.16 | + 0.11 | 0.31; 0.23 | - 0.04 | 0.00; 0.00 | 0.00 | 0.850 |
| Levator muscle length | 32.9; 31.8 | - 1.1 | 29.53; 29.32 | - 0.21 | 28.41; 28.86 | + 0.45 | 0.226 |
| Angles of origin | 60.04; 58.1 | -1.94 | 54.25; 52.46 | -1.79 | 54.60; 54.63 | + 0.03 | 0.065 |

Velar Measures

The differences in velar length between upright and supine positions varied among individuals in the type of response to gravity. Five out of 12 subjects demonstrated an increase in length of the velum from the upright to supine position. The increase in length was consistent across rest, /i/, and /s/ tasks. The remaining 7 subjects demonstrated variations in their responses (increase or decrease) across positions and across the tasks. Group mean differences between

upright and supine indicated a minimal increase in velar length for rest (+0.52), /i/ (+0.59), and /s/ (+1.04). These differences however, were not statistically significant at $p = .004$.

The thickness of the velum between upright versus supine positions varied among individuals in the type of response to gravity. Only three out of 12 subjects demonstrated an increase in velar thickness from the upright to the supine position. Group mean differences between upright and supine were -0.11mm for rest, -0.17mm for /i/, and +0.11mm for /s/. These differences, however were minimal and within 0.1 mm, demonstrating a non-statistically significant finding ($p = .750$).

There were no consistent patterns or statistically significant differences in velar height between upright and supine position across rest, /i/, and /s/ ($p = .795$). The responses varied across subjects. Group mean differences across upright and supine positions were -0.1 for rest, -0.22 for /i/, and +0.13 for /s/.

As expected for children with normal velopharyngeal mechanism, the retrovelar space was zero for 11 out of the 12 subjects during speech tasks. Seven subjects demonstrated a decrease in retrovelar space from the upright to the supine position at rest. Group mean differences between upright and supine positions were minimal for rest (+0.11), /i/ (-0.04), and /s/ (0.00) productions. The differences across position for this variable were not statistically significant ($p = .850$).

Levator Veli Palatini Muscle Measures

For 11 of the 12 subjects, the levator muscle length minimally decreased (- 1.26mm) in length when moving from the upright to the supine position at rest. During production of /s/, 8 subjects demonstrated a minimal increase (+1.12mm) in levator muscle length in the supine

position. Group means indicate an average muscle shortening at rest (-1.1) and for /i/ production (-0.21). A minimal increase was observed for /s/ production (+0.45). The differences noted, however, were not significant ($p = .226$).

Four subjects demonstrated a decrease in angles of origin from the upright to the supine position at rest and during production of /i/ and /s/. Differences across subjects indicate that nine subjects had a decrease in angles of origin in the supine position for the production of /i/. The differences in angle between upright and supine positions were not significant ($p = .065$).

Differences Across Condition

A one-way analysis of variance (ANOVA) was performed to compare the effects of the three treatments (rest, /i/, and /s/ production) on levator length and the angle of origin. The ANOVA results for the levator length were $F_{2,35} = 10.1121$; $p = .0004$ in the upright position and $F_{2,35} = 4.0855$; $p = .026$ in the supine position. The ANOVA results for the angle of origin were $F_{2,35} = 5.8381$; $p = .0067$ in the upright position and $F_{2,35} = 3.8631$; $p = .0311$ in the supine position. As expected, the changes across the three treatments were statistically significant at the .05 level of significance.

The percentage of levator muscle contraction during production of /i/ and /s/ across upright and supine positions were calculated. For the production of /i/, the percentage of levator contraction was 10.3% in the upright position and 7.68% in the supine position. For /s/ production, the contraction was 13.7% in the upright position and 9.04% in the supine position. The percentage of contraction for both /i/ and /s/ productions were greater in the upright than in the supine position.

DISCUSSION

Overall, the effect of gravity on the velopharyngeal structures in young children during rest and sustained speech production tasks demonstrates no significant differences ($p < 0.002$) from the upright to the supine position. The responses of the variables of interest were different across subjects. There is not enough evidence to validate the use for upright MRI over the traditional supine imaging methods to reduce effects of gravity on the structures that were investigated. Supine imaging can be used to relate to upright speech gestures in this targeted child population. This study protocol demonstrated 100% success rate in which all children who volunteered for the study, successfully completed the study. Similar studies using supine imaging only for children between 4 - 7 years of age showed an average success rate of ninety-six percent (Tian et al., 2010a; Tian et al., 2010b). While these differences are negligible, the behavioral and imaging protocol development for this study can be adopted for future imaging studies involving children.

Velar Measures (Length, Thickness, and Height)

The velum remained nearly the same in thickness and height for rest, /i/, and /s/ production during upright and supine position. There was a consistent increase in velar length at rest, /i/ and /s/ production between the two positions. While these findings are consistent with Perry (2011b), they are not consistent with findings of Ingman et al. (2004). Of the three measure of length, thickness, and height, velar length exhibited most differences between the upright and supine positions. The incidence of increase in velar height that one might assume in the supine position due to the effects of gravity was observed only in the production of /s/. This finding is consistent with that of Perry (2011b) for adult females. However, Perry (2011b) showed statistically significant difference in velar height between upright and supine position. The

findings in the present study related to velar height during /s/ were not statistically significant. This may be due to the greater sample size used in the present study (N = 12) compared to Perry (N = 4). The increase in velar length, thickness, and height during the production of /s/ could be attributed more to the sound production characteristic of /s/ rather than a significant response to gravity. The mean velar muscle length (mean, 26.01mm) and thickness (mean, 7.11mm) in the present study (in the supine position) were similar to those reported in studies of Chinese children (mean length, 25.52mm; mean thickness, 9.15mm during rest and sustained phonation (Tian et al., 2010a; Tian et al., 2010b). Although studies by Tian et al. (2010a and 2010b) examined numerous speech tasks, the data in these papers were not reported separately for each phoneme. The phonemes used in these studies, /a/, /i/, /z/, /m/, /f/ (Tian et al., 2010a) and /a:/, /i:/, /ts/, /m/ (Tian et al., 2010b) for the sustained phonation speech tasks vary significantly in their place and manner of production.

The distance between the velar knee to the posterior pharyngeal wall showed variable differences across subjects between the upright and supine positions. This finding is not consistent with that of Perry (2011b) for adult females, where all subjects showed narrowing of the retrovelar space in the supine position. These differences could be due to variations in the adenoid pad size in the velopharyngeal cavity that are common in children who are in this age range. One subject presented with a mild gap during phonation of /i/. Because all subjects were judged to have clinically normal resonance, it is possible that, unknown to the researcher, this subject took a breath during the scan.

Levator Veli Palatini Muscle Measure

The length of the levator muscle was found to be shorter in the upright versus the supine position only for production of /s/, although differences were not statistically significant. This

minimal effect of gravity on levator muscle length (shortening) was observed at rest position primarily instead of during speech production tasks. This is consistent with findings by Perry (2011b). The percentage of contraction for both /i/ and /s/ productions were greater in the upright than in the supine position. The smaller percentage of contraction demonstrated for /i/ and /s/ productions in the supine position could be due to the caudal displacement of the soft palate and epiglottis when moving from the upright to the supine position as described as Suttipraporn et al (2008). In a similar study (supine position only) on Chinese children, only the extravelar lengths were reported (Tian et al., 2010a). The present study is the first study to provide the complete levator muscle length measurement for children in this age group. The levator muscle length obtained in this study is lesser than that reported by Ettema et al. (2002) on adult male and female subjects (Table A4). Although Kuehn et al. (2004) analyzed the levator muscle in children using MRI, no quantitative data were reported.

Table A4.

Comparison of group means for levator muscle morphology analyses between current study and similar studies using MRI

| | Current study | Perry (2010) | Ettema et al. (2002) |
|-----------------------------------|----------------------|------------------------------------|---|
| <i>Subject</i> | <i>N</i> | 4 | 10 |
| <i>Demographics</i> | <i>Population</i> | <i>Adult females (30-36 years)</i> | <i>Adults males & females (21-53 years)</i> |
| | <i>Age</i> | <i>White</i> | |
| | <i>Race</i> | <i>Black and White</i> | <i>White</i> |
| Angle of origin (°) | | | |
| | Rest | 60.04 | 58 |
| | /i/ | 54.25 | 48 |
| | /s/ | 5.60 | 44 |
| Levator muscle length (mm) | | | |
| | Rest | 32.9 | 44 |
| | /i/ | 29.53 | 37 |
| | /s/ | 28.41 | 36 |
| Muscle contraction (%) | | | |
| | /i/ | 10.3 | 17 |
| | /s/ | 13.7 | 21 |

The findings for angles of origin (Table A4) were similar to that observed on levator muscle length (Ettema et al., 2002; Perry, 2011b). There was a decrease in angles of origin for rest position and production of /i/ in the supine position. Although nonsignificant, decrease in the angle was observed only for /s/ production. The mean levator angles of origin (mean, 55.06) and the levator origin widths (mean, 45.30) were similar to those reported in a previous study (mean, 52.23; mean, 55.0, respectively) on Chinese children (Tian et al., 2010b).

Clinical Implications

The findings of this study provide applications to clinical practice. No studies have

examined the feasibility of using upright MRI imaging to assess the velopharyngeal area in young children. In cleft palate, the major muscle of interest is the levator. MRI enables direct visualization of the levator muscle. Traditional supine imaging has been associated with the feeling of claustrophobia. Younger children (under 4 years of age) have to be sedated. However, modifications to the imaging protocol such as acclimating the subject to the process involved (through audio samples, rehearsals, and consistent reinforcement) can achieve successful results. In the present study, children as young as four years of age were imaged without any sedation at rest and during speech tasks. Magnetic resonance imaging is a promising diagnostic tool for enabling pre-surgical decisions in young children (Perry et al., 2011; Kuehn et al., 2000).

Limitations of the Study

Although the magnetic resonance images were obtained with good resolution, motion artifacts were present. In instances where motion artifacts might have affected the image clarity for analysis, the scans were repeated. This was more evident on the sustained phonation tasks than for the scans taken at rest. Noise was noticeable on the sagittal and oblique coronal images. However, the levator muscle sling and the velar muscle boundaries could still be identified. It is likely that the scan time needs to be reduced to less than 5 seconds to be applicable to younger (3-4 years) populations. There is a trade-off however between spatial and temporal resolution that must be addressed to provide a more useful clinical protocol. Poor image quality can lead to less clear anatomical boundaries, which may not be useful when there is just a small gap. Another limitation of the study is the unequal division of subjects on the basis of race. There are more black subjects when compared to white subjects. Perry et al. (2013) reported no racial differences for the levator muscle length and angle of origin.

CONCLUSION

In cleft palate research, the primary population for secondary surgery is children. This is the first study to provide normative levator muscle lengths for children between 4-8 years of age. This study provides successful imaging of children in an upright magnetic resonance scanner. The modified child-friendly protocol utilized in this study enabled successful scanning of all enrolled subjects. The results from this study indicate that positional variations do not significantly affect the velopharyngeal structures and musculature. Overall, the effect of gravity on velar (length, thickness, and height) and levator (length and angle of origin) muscle measures were minimal. Data obtained on a supine imaging scanner can be applied to an upright activity such as speech. Further benefits of upright imaging should be investigated in the difficult-to-test population.

REFERENCES

- Badin P, Bailly G, Reveret L, Bacin M, Segebarth C, Savariaux C. Three-dimensional linear articulatory modeling of tongue, lips, and face based on MRI and video images. *J Phon.* 2002; 30:533–553.
- Buchaillard S, Perrier P. A biomechanical model of cardinal vowel production: muscle activations and the impact of gravity on tongue positioning. *J Acoust Soc Am.* 2009; 126:2033–2051.
- Ettema SL, Kuehn DP, Perlman AL, Alperin N. Magnetic resonance imaging of the levator veli palatini muscle during speech. *Cleft Palate Craniofac J.* 2002; 39:130–144.
- Hoit J. Influence of body position on breathing and its implications for the evaluation and treatment of speech and voice disorders. *J Voice.* 1994; 09:341–347.
- Ingman T, Nieminen T, Hurmerinta K. Cephalometric comparison of pharyngeal changes in subjects with upper airway resistance syndrome or obstructive sleep apnea in upright and supine positions. *Eur J Orthod.* 2004; 26:321–326.
- Kitamura T, Takemoto H, Honda K, Shimada Y, Fujimoto I. Difference in vocal tract shape between upright and supine postures: observations by an open-type MRI scanner. *Acoust Sci Technol.* 2005; 26:465–468.
- Kuehn DP, Ettema SL, Goldwasser MS, Barkmeier JC. Magnetic resonance imaging of the levator veli palatini muscle before and after primary palatoplasty. *Cleft Palate Craniofac J.* 2004; 41:584–592.
- Kuehn DP, Ettema SL, Goldwasser MS, Barkmeier JC, Wachtel JM. Magnetic resonance imaging in the evaluation of occult submucous cleft palate. *Cleft Palate Craniofac J.* 2000; 38:421–431.
- Moon J, Canady J. Effects of gravity on velopharyngeal muscle activity during speech. *Cleft Palate Craniofac J.* 1995; 32:371–375.
- Perry JL. Anatomy and physiology of the velopharyngeal mechanism. *Semin Speech Lang.* 2011a; 32:83–92.
- Perry JL. Variations in velopharyngeal structures between upright and supine positions using upright magnetic resonance imaging. *Cleft Palate Craniofac J.* 2011b; 48:123–133.
- Perry JL, Bae Y, Kuehn DP. Effect of posture on deglutitive biomechanics in healthy individuals. *Dysphagia.* 2012; 27:70–80.
- Perry JL, Kuehn D, Sutton B, Gamage J. Anthropometric analysis of the velopharynx and related craniometric dimensions in three adult populations using MRI. *Cleft Palate Craniofac J.* 2013 in press.
- Perry JL, Kuehn DP, Sutton BP, Goldwasser MS, Jerez AD. Craniometric and velopharyngeal assessment of infants with and without cleft palate. *J Craniofac Surg.* 2011; 22:499–503.

- Stone M, Stock G, Bunin K, Kumar K, Epstein M. Comparison of speech production in the upright and supine position. *J Acoust Soc Am.* 2007; 122:532–541.
- Sutthiprapaporn P, Tanimoto K, Ohtsuka M, Nagasaki T, Lida Y, Katsumata A. Positional changes of oropharyngeal structures due to gravity in the upright and supine positions. *Dentomaxillofac Radiol.* 2008; 37:130–136.
- Tian W, Yin H, Li Y, Zhao S, Zheng Q, Shi B. Magnetic resonance imaging assessment of velopharyngeal structures in Chinese children after primary palatal repair. *J Craniofac Surg.* 2010a; 21:568–577.
- Tian W, Yin H, Redett R. Magnetic resonance imaging assessment of the velopharyngeal mechanism at rest and during speech in Chinese adults and children. *J Speech Lang Hear Res.* 2010b; 53:1595–1615.

CHAPTER 4

STUDY II

Racial Variations in Velopharyngeal and Craniometric Morphology in Children: An Imaging Study²

ABSTRACT

The purpose of this study is to examine craniometric and velopharyngeal anatomy among young children (4-8 years of age) with normal anatomy across two racial groups including Black and White. Thirty-two healthy children (16 White and 16 Black) with normal velopharyngeal anatomy participated and successfully completed the MRI scans. Measurements included 11 craniofacial and nine velopharyngeal measures. Two-way analysis of covariance (ANCOVA) was used to determine the effects of race and sex on velopharyngeal measures and all craniometric measures except head circumference. Head circumference was included as a covariate to control for overall cranial size. Sex did not have a significant effect on any of the craniometric measures. Significant racial differences were demonstrated for face height. A significant race effect was also observed for mean velar length, velar thickness, and velopharyngeal ratio. The present study provides separate craniofacial and velopharyngeal values for young Black and White children. Data from this study can be used to examine morphological variations with respect to race and sex.

² Kollara, L., Perry, J. L., & Hudson, S. (2016). Racial variations in velopharyngeal and craniometric morphology in children: An imaging study. *Journal of Speech, Language, and Hearing Research*, 59(1), 27-38.
<http://jslhr.pubs.asha.org/article.aspx?articleid=2469135&resultClick=3>

INTRODUCTION

The velopharyngeal mechanism is a muscular valve that includes the velum, lateral pharyngeal walls, and posterior pharyngeal wall. Velopharyngeal function is accomplished through the combined action of several muscles including the levator veli palatini (levator), superior pharyngeal constrictor, musculus uvulae, palatoglossus, and palatopharyngeus (Seaver & Kuehn, 1980). The levator muscle is the primary muscle responsible for velar retraction and elevation. The muscle originates from the base of the skull and courses in a medial, inferior, and anterior direction to the insert into the body of the velum (Huang, Lee, & Rajendran, 1998; Moon & Kuehn, 2004). Studies have examined the velopharyngeal muscles using dissection (Barsoumian, Kuehn, Moon, & Canady, 2009; Mehendale, 2004), histology (Kuehn & Kahane, 1990), electromyography (Kuehn & Moon, 1994), and muscle biopsy during surgery (Lindman, Paulin, & Stål, 2001). However, these are invasive methods for assessing muscle tissue and function. Magnetic resonance imaging (MRI) has been demonstrated to be a useful tool for imaging the velopharyngeal structures because of its ability to visualize the muscles, *in vivo* (Ettema, Kuehn, Perlman, & Alperin, 2002). There are currently no other imaging techniques that allow for a three-dimensional view of the velopharyngeal muscles *in vivo*.

Studies have demonstrated the use of MRI in assessing levator muscle characteristics in adults with normal velopharyngeal anatomy (Ettema et al., 2002; Bae et al., 2011; Perry et al., 2013) as well as in adults with repaired cleft palate and hypernasal speech (Ha et al., 2007). Ha et al. (2007) reported that subjects with residual hypernasality demonstrated levator muscle dimensions that were different from levator muscle features in adults without cleft palate. Perry, Kuehn, Sutton, and Gamage (2014) hypothesized that velopharyngeal structures vary based on sex and race among the adult population with normal anatomy. Velopharyngeal anatomy and

craniometric dimensions were assessed using a large sample size (N=89) distributed across three adult populations (Black, White, and Asian). Palate height, linear cranial base, face height and width, and levator length were found to have significant sex differences, with males demonstrating larger values compared to females. Craniometric measures including face width, linear base values, cranial base angle, and velar measures (velar length and thickness) were found to vary significantly based on race. The differences in mean levator muscle measures among three adult racial groups were not statistically significant; however, significant sex differences were noted across velopharyngeal muscles after removing the effect of the individual's head size. Race and sex were found to have a significant effect on velar length and thickness.

Studies using MRI in child populations have been slower to evolve due to decreased imaging speeds and difficulties in controlling motion artifacts. As such, MRI studies of the velopharyngeal anatomy among children with normal anatomy have been limited to small sample sizes (Tian et al., 2010a; Tian et al., 2010b; Tian et al., 2010c; Kollara & Perry, 2014). These studies have included White, Black, and Chinese child participants. However, no statistical analyses were conducted to examine velopharyngeal variations among different racial groups despite the significant racial differences found among adult participants (Perry et al., 2014). There is a dearth of research on the levator muscle variations among children from Black racial groups. No studies have addressed whether the race and sex differences reported by Perry et al. (2014) are consistent among the child population-

Research examining the effects of race and cranial morphology on velopharyngeal anatomy in children has been limited due to less advanced and slower imaging methods. Additionally, methods have not evaluated a child-friendly protocol on a large child data set using

behavioral and environmental modifications to limit motion artifacts. Research related to the anthropometric characteristics of the velopharyngeal mechanism in young children is important in providing insights that can guide our understanding of anatomic variations, such as in cleft palate anatomy. Anatomical data of the velopharyngeal mechanism in children are also valuable because this is the primary age group for determining secondary surgical needs related to velopharyngeal dysfunction.

Studies have emphasized the importance of understanding the racial and sex variations in the velopharyngeal anatomy (Chung & Kau, 1985; Chung, Runck, Bilben, & Kau, 1986, Perry et al., 2014). More specifically, studies have discussed the use of pre-surgical anatomy data to guide proper surgical treatment options among children born with cleft lip and palate (Inouye, Pelland, Lin, Borowitz, & Blemker, in press). Finite element modeling of the velopharyngeal mechanism has provided support for pre-surgical planning that is guided by patient pre-surgical anatomy. Inouye et al. (in press) used computational modeling to demonstrate how variations in surgical maneuvers used in primary cleft palate repair can influence the outcome for proper muscle function. Inouye et al. (in press) further demonstrated how variations in pre-surgical anatomy influence the muscle function outcomes using a single surgical technique in cleft palate repair. Farkas, Katic, and Forrest (2007) highlighted the need for separate norms across different racial groups to guide and tailor craniofacial surgery. The paucity of normative three-dimensional data is a significant obstacle for surgical stimulation procedures (Altobelli et al., 1993). Perry et al. (2014) proposed that the racial and sex variations in velopharyngeal anatomy found among adults may indicate that a patient's race and sex be features that inform the surgical treatment decisions in cleft palate care. Investigations of race and sex variations, however, have been limited to adult populations.

The purpose of this study was to examine the craniometric and velopharyngeal anatomy among young children (4-8 years of age) with normal velopharyngeal anatomy across two racial groups including Black and White. This study aims to provide preliminary data to improve our understanding of the velopharynx and cranial anthropometry across two racial groups. Consistent with the comparable adult findings (Perry et al., 2014), it was hypothesized that race would have a significant effect on craniofacial and velar structures in children. Given that the cranium houses the internal musculature, the predictive ability of cranial features in determining orientation and morphology of the levator muscle was also assessed.

METHOD

Participants

In accordance with the approved Institutional Review Board proposal, 32 healthy children (16 White and 16 Black) were recruited. The participant group consisted of equal male and female groups by race including eight White males, eight White females, eight Black males, and eight Black females. All participants self-reported the same ancestry (African American or European American) across three generations (i.e., both parents and all four grandparents having the same race). Self-report is considered the gold standard for racial classification (Kaufman & Cooper, 2001). Participants were between four and eight years of age ($M = 6.06$, $SD = 1.4$), with mean height 46.4 inches ($SD = 5.0$) and mean weight 51.7 pounds ($SD = 15.6$). Black participants were on average 12 months older and of greater height (5.2 inches) and weight (18.84 pounds) compared to White participants. However, mean body mass index (BMI) between White and Black participant groups differed by an index of less than 1.5. Height ($p = .003$), weight ($p = .001$), and BMI ($p = .044$) were found to be significantly different for Black

and White groups based on paired *t*-test results. For these reasons, analyses of covariance were used, as described below in statistical analyses.

The typical age for determining secondary surgical requirements in a child with repaired cleft palate and residual hypernasality is between four and eight years of age. This is also an important period for speech, language, and communication development. Nine years has been reported to be the onset time for significant growth in the thickness of mid-facial tissue in Black children (Williamson et al., 2002). Hence, children between four and eight years of age were selected to participate in the study. The demographics of the participants are presented in Table B1.

Table B1.

Subject demographics with mean and standard deviation in parentheses

| | No. of Subjects | Mean Age years | Mean weight pounds | Mean Height inches | Mean head circumference millimeters | Mean Body Mass Index (BMI) |
|-----------------|------------------------|--------------------------|------------------------------|------------------------------|---|-----------------------------------|
| Subjects | <i>n</i> | <i>M (SD)</i> | <i>M (SD)</i> | <i>M (SD)</i> | <i>M (SD)</i> | <i>M (SD)</i> |
| White Males | 8 | 5.54 (1.1) | 42.09 (5.3) | 44.07(4.6) | 521.25 (20.3) | 15.28 (1.5) |
| White Females | 8 | 5.55 (1.5) | 43.25 (9.8) | 43.04 (3.6) | 504.48 (11.5) | 15.96 (1.69) |
| Black Males | 8 | 6.32 (1.6) | 67.10 (18.9) | 49.06 (5.9) | 517.05 (30.1) | 17.71 (2.61) |
| Black Females | 8 | 6.80 (1.1) | 58.32 (16.7) | 49.06 (4.3) | 499.38 (26.1) | 16.81 (2.02) |

Participants were recruited through flyers placed in the community. Participants' parents reported no history of congenital syndromes, neurological disorders, craniofacial anomalies, musculoskeletal disorders, or swallowing disorders that could potentially affect the regions that were investigated for the study. No children had a history of tonsillectomy or adenoidectomy. The participants were all native English speakers. A speech language pathologist administered an oral mechanism examination on all participants to assess the structural integrity of the articulators and to ensure all participants had normal oral structures and function. In addition, a perceptual rating scale was used to evaluate nasality. All participants were formally rated by two speech language pathologists (first and second authors) with experience in resonance using a 4-point scale (0 = normal resonance; 3 = severe hypernasality) and determined to have normal oral-to-nasal balance as indicated by a score of 0 on the rating scale. A perceptual evaluation was also conducted to rule out articulation errors for the targeted speech sounds for the study.

Pre-scan training

All participants underwent training before starting the MRI exam. An established child-friendly protocol was used to familiarize the participants with the scanning process (Kollara & Perry, 2014). In brief, all participants were given MRI coloring sheets specifically designed for children to introduce them to the MRI study process. Participants were given the opportunity to explore the MRI machine with their parent and the investigator a few minutes before their respective MRI scans. Participants were encouraged to watch the participant being imaged before their assigned study time. To eliminate coercion, all participants were given time (5-10 minutes) to adapt to the new environment. The investigator proceeded with the study only if the participants were fully comfortable with the procedure. The parent was in the scanning room for the duration of the scan. The investigator communicated with the participants throughout the

exam via a speaker-microphone system between the scanning and control rooms. The participants were frequently asked about their comfort level and were given a panic button. To minimize distractions, participants were allowed to listen to music during the duration of the scan. Small foam cushions were placed in the head coil on either side of the participant's head to minimize motion artifacts.

Magnetic Resonance Imaging

Participants were scanned using two different scanners with the same MRI protocol. All participants were imaged at rest in the supine position. Magnetic resonance images were acquired on 19 participants using a 1.5 Tesla Philips Intera scanner (Philips, Eindhoven, Netherlands). A high resolution, T1- weighted turbo-spin-echo (TSE) 3D anatomical scan called SENSE was utilized. The remaining 13 participants were imaged using a 3.0 Tesla General Electronics scanner. The protocol used for this scanner included a three-plane localizer, midsagittal T2-fluid attenuation inversion recovery (FLAIR), and coronal, oblique coronal, and axial Fast Spin Echo (FSE) sequences. Scanning sequence protocols were designed to display similar image in-plane resolution using the same matrix (256 X 256), slice thickness (1.5 mm), spacing (0 mm), and pulse sequences (TE = 17 ms; TR = 3000 ms). This enabled comparison between MRI data obtained across the two study sites.

Image analyses

The MRI images were transferred into Amira 4 Visualization Volume Modeling software (Visage Imaging GmbH, Berlin, Germany). Amira has native Digital Imaging and Communication in Medicine (DICOM) support program that enables preservation of original geometry of the data.

Eleven craniofacial measures were obtained from the MRI data in the midsagittal and coronal image planes. A description and demonstration of each measure is provided in Table B2 and Figure B1. The craniofacial measures include head circumference, nasion to sella, sella to basion, basion to opisthion, nasion to basion, hard palate length, pharyngeal depth, nasion-sella-basion (NSB) angle, sella-basion-opisthion (SBO) angle, face height, and face width.

Table B2.

Description of the 11 craniometric measures

| Measure | Definition |
|-------------------------------------|--|
| Head Circumference | The maximal diameter of the head, measured around the frontal forehead and occiput, just above the brow line. |
| Nasion to sella | Linear distance from nasion to sella |
| Sella to basion | Linear distance from sella to basion |
| Basion to opisthion | Linear distance from basion to opisthion |
| Nasion to basion | Linear distance from nasion to basion |
| Hard palate length (ANS to PNS) | Distance from the anterior nasal spine to the posterior nasal spine |
| Pharyngeal depth (PNS to basion) | Distance from the posterior nasal spine to the basion |
| NSB angle | Inner angle formed between two intersecting lines, one connecting the nasion to sella and the other connecting basion to sella |
| SBO angle | Inner angle formed between two intersecting lines, one connecting sella to basion and the other connecting opisthion to basion |
| Face height | Distance from nasion to menton |
| Face Width | Distance between the most lateral portions of the zygomatic arches |

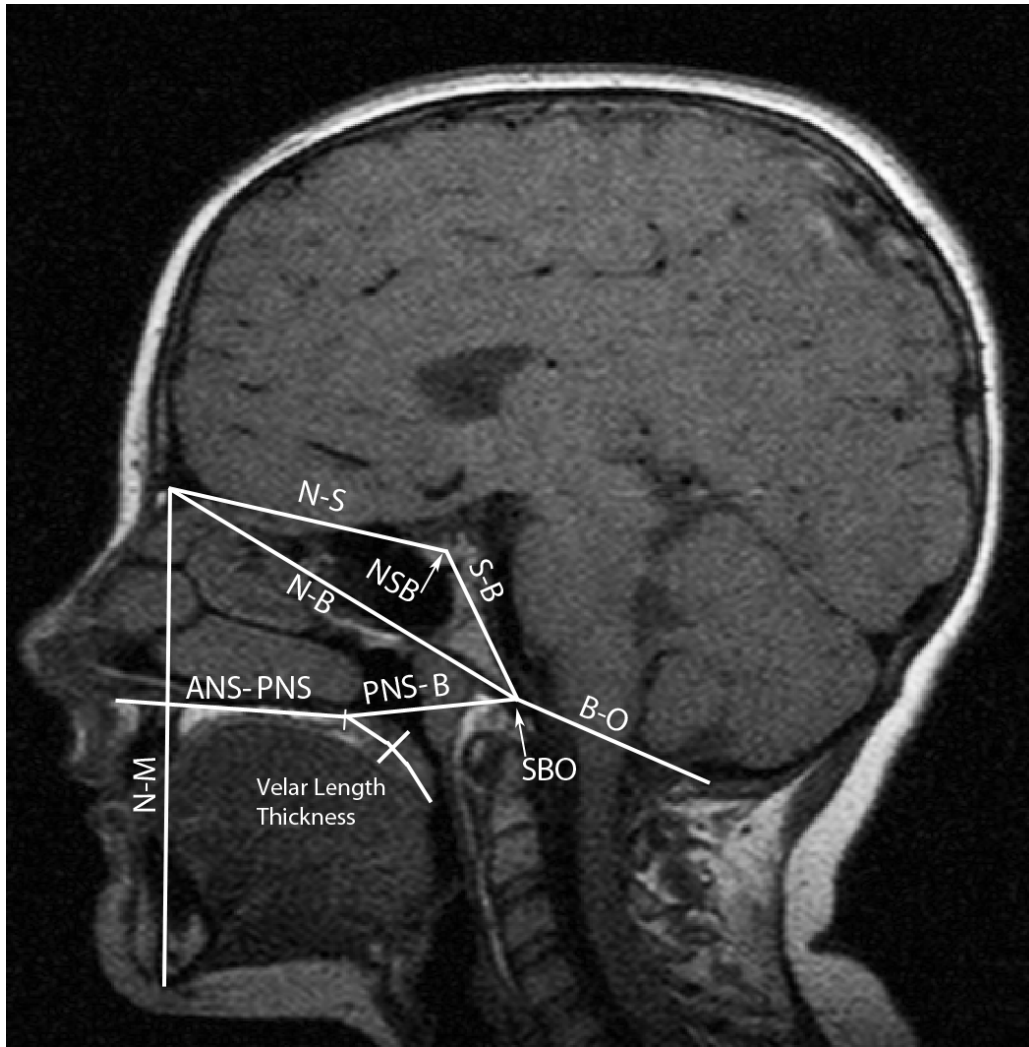


Figure B1. Craniometric measures obtained in the midsagittal plane. Where N = nasion, S = sella, B = basion, O = opisthion, NSB = nasion-sella-basion angle, SBO = sella-basion-opisthion angle, ANS = anterior nasal spine, PNS = posterior nasal spine, M = menton

Nine velopharyngeal measures were obtained in the midsagittal and oblique coronal image planes. The oblique coronal plane that displays the levator muscle sling in its entirety was obtained by resampling the midsagittal image. These measures included levator muscle length, extravelar length, intravelar length, origin to origin, velar insertion, angles of origin, velar length,

velar thickness, and velopharyngeal ratio (ratio of velar length to pharyngeal depth). The measures are described in Table B3 and demonstrated in Figures B1 and B2. The measurement procedures have been described previously (Kollara & Perry, 2014).

Table B3.

Description of the nine velopharyngeal measures

| Measure | Definition |
|-------------------|--|
| Levator length | Distance from the origin of the muscle at the base of the skull, through the middle of the muscle belly, and to the midline insertion at the velum. |
| Extravelar length | Distance of the levator veli palatini muscle from its origin at the base of the skull to its insertion into the body of the velum. |
| Intravelar length | Distance of the levator veli palatini muscle that is within the body of the velum. |
| Origin to origin | Distance between the points of origin of the levator veli palatini muscle on the right and left sides. |
| Velar insertion | Distance between where the levator veli palatini muscle inserts into the body of the velum on the right and left sides. |
| Angles of origin | Angle created between a reference line connecting the two origins of the levator muscle and the line drawn to measure the levator muscle length. |
| Velar length | Distance of a curvilinear line starting at the posterior nasal spine, coursing through the middle of the cross sectioned velum, to the tip of the uvula. |
| Velar thickness | Distance from the velar knee to the velar dimple. |
| VP ratio | Velar length/Pharyngeal depth |

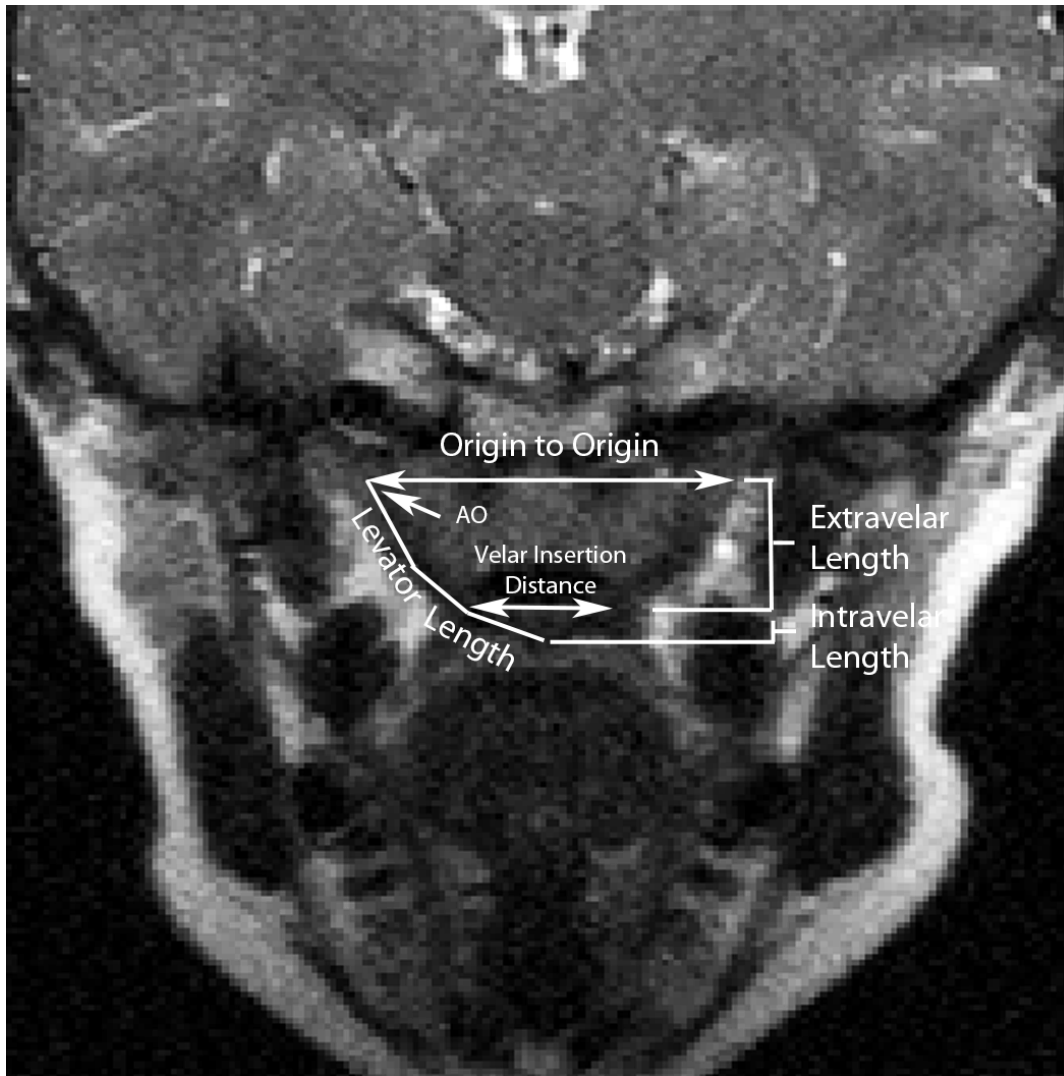


Figure B2. Oblique coronal image demonstrating levator muscle. AO = Angle of origin

Statistical Analyses

Statistical analyses were conducted on 32 participants to determine racial and gender variations among the 11 craniometric and nine velopharyngeal measures and to determine the associations between the variables. The assumption of normality was adequately met for all group combinations of race and gender, as assessed by formal tests (Shapiro-Wilk's test) and graphical representation (Q-Q plots). Homogeneity of variance was reasonably met for all

combinations of race and gender as assessed by the Levene's test of homogeneity of variance and graphical representation (scatterplot of residuals versus predicted values). A two-way analysis of covariance (ANCOVA) was conducted to determine the relationship between race and sex and the means of the velopharyngeal and craniometric measures.

Statistical analysis revealed a significant correlation between head circumference and height ($r = .437, p = .012$) and weight ($r = .49, p = .004$). The correlation between height and weight was also noted to be significant and highly correlated ($r = .88, p = .000$). Because the variables of height, weight, and head circumference were correlated, it was determined that it would be redundant to use all three variables as covariates as they are all examining similar features related to overall size of the subject. During changes in body weight, head circumference remains as a valid and reliable measure regardless of the individual's overall size. Therefore, only the measure of head circumference was included as a covariate. Additionally, this variable was used because it is the closest anatomic structure to the dependent variables that can be measured reliably and then used to remove the effect of differences in individual size between participants. We excluded individuals who were obese (having a body mass index over 30) due to the known increased velar thickness due to fatty tissue around the velar body (Horner et al., 1989). In the present study, fat pads were not observed in non-obese individuals despite their variations in height and weight. To determine how well craniometric measures could predict velopharyngeal muscle measures, multiple regression analyses were conducted. Given that the cranium serves as the muscle attachment, the analysis aimed to determine which fixed and bony craniofacial markers could best predict the arrangement and orientation of the respective soft muscle velopharyngeal measures. The Bonferroni method was used to adjust the significance level in order to account for multiple comparisons. The adjusted significance levels

used were the significance level (.05) divided by 20 for the analyses of covariance and by eight for the regression analyses since there were 20 analyses of covariances and eight regression analyses conducted.

Intra-rater and inter-rater reliability measures were established using the Pearson product moment correlation ($\alpha = .05$). Both primary and secondary authors had experience in 3D MRI data processing. Reliability measurements were performed by measuring all variables from 13 randomly selected participants two months after the first measurements were obtained. Intra-rater and inter-rater reliability ranged from $r = .70$ to $r = .97$. Paired t -tests were conducted to determine intra-rater and inter-rater differences. There were no statistically significant differences ($p > .05$) between the first and second measures by the primary author. For intra-rater reliability, the mean differences for the measures ranged from .02 mm to 1mm. There were also no statistically significant differences ($p > .05$) between the measures from the two authors. The mean differences for the measures ranged from .05 mm to 1.2 mm across raters.

RESULTS

Magnetic resonance images were obtained on all participants with 100% success rate. Group estimated marginal means for craniometric and velopharyngeal measures (differentiated by race and gender) are reported in Tables B4 and B5. A two-way analysis of covariance (ANCOVA) was used to determine the effects of race and sex on velopharyngeal measures and all craniometric measures except head circumference (Tables B6 and B7).

Table B4.

Estimated (adjusted for head circumference) marginal means and standard deviations (in parenthesis) for each craniometric measures. Values are noted in millimeters, with the exception of the angle measures (in degrees).

| Measures | White | | Mean | Black | | Mean | Combined Mean | |
|--------------------|----------------|----------------|----------------|----------------|----------------|----------------|----------------|----------------|
| | Male | Female | | Male | Female | | Male | Female |
| Head circumference | 521.2 (7.9) | 504.4 (7.9) | 512.8 (5.5) | 517.5 (7.9) | 498.1 (5.5) | 507.8 (5.5) | 519.3 (5.5) | 501.3 (5.5) |
| Nasion-sella | 55.0 (1.4) | 55.5 (1.4) | 55.3 (1.0) | 56.0 (1.4) | 52.3 (1.5) | 54.1 (1.0) | 55.5 (1.0) | 53.9 (1.0) |
| Sella-basion | 32.8 (0.7) | 32.8 (0.7) | 32.8 (0.5) | 35.0 (0.7) | 35.1 (0.8) | 35.1 (0.5) | 33.9 (0.5) | 34 (0.5) |
| Basion-opisthion | 38.7 (1.3) | 39.0 (1.3) | 38.9 (0.9) | 36.0 (1.3) | 39.0 (1.4) | 37.5 (0.9) | 37.3 (1.0) | 39.0 (1.0) |
| Nasion-basion | 80.1 (1.4) | 80.5 (1.3) | 80.3 (0.9) | 82.4 (1.3) | 80.03 (1.4) | 81.2 (0.9) | 81.2 (1.0) | 80.2 (1.0) |
| Hard palate length | 42.9 (2.4) | 45.8 (2.3) | 44.4 (1.6) | 40.9 (2.3) | 43.56 (2.4) | 42.2 (1.6) | 41.9 (1.7) | 44.6 (1.7) |
| Pharyngeal depth | 39.2 (1.4) | 39.5 (1.3) | 39.3 (0.9) | 44.6 (1.3) | 41.9 (1.4) | 43.3 (0.9) | 41.9 (1.0) | 40.7 (1.0) |
| NSB angle | 130.9 (2.7) | 129.8 (2.6) | 130.3 (1.8) | 131.6 (2.6) | 132.2 (2.7) | 131.9 (1.8) | 131.3 (1.9) | 131.0 (1.9) |
| SBO angle | 224.3 (3.0) | 222.4 (2.9) | 223.3 (2.0) | 222.5 (2.9) | 228.0 (3.0) | 225.3 (2.0) | 223.4 (2.1) | 225.2 (2.1) |
| Face height | 86.1 (1.9) | 88.8 (1.9) | 87.5 (1.3) | 97.4 (1.9) | 96.3 (1.9) | 96.9 (1.3) | 91.8 (1.4) | 92.6 (1.4) |
| Face width | 110.4 (2.3) | 115.5 (2.2) | 112.9 (1.6) | 113.8 (2.2) | 109.2 (2.3) | 111.5 (1.6) | 112.1 (1.6) | 112.4 (1.6) |

Table B5.

Estimated (adjusted for head circumference) marginal means and standard deviations (in parenthesis) for each muscle measures. Values are noted in millimeters, except for the angle measure (in degrees).

| Measures | White | | Mean | Black | | Mean | Combined Mean | |
|--------------------------|---------------|---------------|---------------|---------------|---------------|---------------|---------------|---------------|
| | Male | Female | | Male | Female | | Male | Female |
| Levator length | 33.6 (0.9) | 32.9 (0.8) | 33.2 (0.6) | 35.8 (0.8) | 34.2 (0.9) | 35.0 (0.6) | 34.7 (0.6) | 33.5 (0.6) |
| Extravelar length | 23.6 (0.9) | 24.2 (0.9) | 23.9 (0.6) | 25.9 (0.9) | 25.5 (0.9) | 25.7 (0.6) | 24.8 (0.6) | 24.8 (0.6) |
| Intravelar length | 17.9 (1.5) | 17.4 (1.5) | 17.7 (1.0) | 19.9 (1.5) | 18.2 (1.5) | 19.0 (1.0) | 18.9 (1.1) | 17.8 (1.1) |
| Origin-origin | 49.1 (1.5) | 46.7 (1.4) | 47.9 (1.0) | 50.5 (1.4) | 47.7 (1.5) | 49.1 (1.0) | 49.8 (1.0) | 47.3 (1.0) |
| Velar insertion distance | 18.5 (0.9) | 16.3 (0.9) | 17.4 (0.6) | 18.4 (0.9) | 16.3 (0.9) | 17.4 (0.6) | 18.5 (0.6) | 16.3 (0.6) |
| Angle of origin | 56.8 (1.7) | 57.8 (1.6) | 57.3 (1.1) | 55.4 (1.6) | 55.7 (1.7) | 55.5 (1.1) | 56.1 (1.2) | 56.7 (1.2) |
| Velar length | 21.8 (1.6) | 23.1 (1.6) | 22.4 (1.1) | 30.3 (1.6) | 31.7 (1.6) | 31.0 (1.1) | 26.0 (1.1) | 27.4 (1.1) |
| Velar thickness | 6.1 (0.3) | 6.5 (0.3) | 6.3 (0.2) | 8.8 (0.3) | 8.8 (0.3) | 8.8 (0.2) | 7.4 (0.2) | 7.7 (0.2) |
| VP Ratio | .58 (.07) | .57 (.04) | .57 (.05) | .68 (.11) | .73 (.07) | .70 (.09) | .63 (.10) | .65 (.09) |

Table B6.

Results from the ANCOVA models, analyzing the effects of sex and race on craniometric measures. Except for head circumference, test statistics represent the effect after adjusting for head circumference. * $p < .05/20 = .0025$. The eta-squared value (in parentheses) demonstrates the effect size for the data. Statistically significant results shown in bold font.

| Measures | Sex | Race | Interaction (Sex & Race) |
|---------------------|---|---|---|
| Head circumference | $F_{1,28} = 5.217$ $p = 0.030$ (.15) | $F_{1,28} = .408$ $p = 0.528$ (.01) | $F_{1,28} = .027$ $p = 0.160$ (.00) |
| Nasion to sella | $F_{1,27} = 1.074$ $p = 0.309$ (.03) | $F_{1,27} = .621$ $p = 0.437$ (.02) | $F_{1,27} = 2.086$ $p = 0.528$ (.07) |
| Sella to basion | $F_{1,27} = .001$ $p = 0.970$ (.00) | $F_{1,27} = 8.460$ $p = 0.007$ (.23) | $F_{1,27} = .007$ $p = 0.936$ (.00) |
| Basion to opisthion | $F_{1,27} = 1.304$ $p = 0.263$ (.04) | $F_{1,27} = 1.056$ $p = 0.313$ (.03) | $F_{1,27} = 1.031$ $p = 0.319$ (.03) |
| Nasion to basion | $F_{1,27} = 0.456$ $p = 0.505$ (.01) | $F_{1,27} = .433$ $p = 0.516$ (.01) | $F_{1,27} = 1.105$ $p = 0.303$ (.03) |
| Hard palate length | $F_{1,27} = 1.142$ $p = 0.295$ (.00) | $F_{1,27} = .836$ $p = 0.369$ (.22) | $F_{1,27} = .002$ $p = 0.966$ (.05) |
| Pharyngeal depth | $F_{1,27} = .647$ $p = 0.428$ (.02) | $F_{1,27} = 8.337$ $p = 0.008$ (.23) | $F_{1,27} = 1.255$ $p = 0.272$ (.04) |
| NSB Angle | $F_{1,27} = .008$ $p = 0.929$ (.00) | $F_{1,27} = .348$ $p = 0.560$ (.01) | $F_{1,27} = 0.097$ $p = 0.758$ (.00) |
| SBO Angle | $F_{1,27} = .311$ $p = 0.582$ (.01) | $F_{1,27} = .427$ $p = 0.519$ (.01) | $F_{1,27} = 1.591$ $p = 0.218$ (.05) |
| Face height | $F_{1,27} = .146$ $p = 0.706$ (.00) | $F_{1,27} = 23.993$ $p < 0.0005^*$ (.47) | $F_{1,27} = .956$ $p = 0.337$ (.03) |
| Face width | $F_{1,27} = .014$ $p = 0.905$ (.00) | $F_{1,27} = .386$ $p = 0.540$ (.01) | $F_{1,27} = 4.605$ $p = 0.041$ (.14) |

Table B7.

*Results from the ANCOVA models, analyzing the effects of sex and race on muscle measures. Test statistics represent the effect after adjusting for head circumference. * $p < .05/20 = .0025$. The eta-squared value (in parentheses) demonstrates the effect size for the data. Statistically significant results shown in bold font.*

| Measures | Sex | Race | Interaction (Sex & Race) |
|--------------------------|---|--|--|
| Levator length | $F_{1,27} = 1.491$ $p = 0.233$ (.05) | $F_{1,27} = 3.996$ $p = 0.056$ (.12) | $F_{1,27} = .256$ $p = 0.617$ (.00) |
| Extravelar length | $F_{1,27} = .002$ $p = 0.963$ (.00) | $F_{1,27} = 3.677$ $p = 0.066$ (.12) | $F_{1,27} = 0.267$ $p = 0.610$ (.01) |
| Intravelar length | $F_{1,27} = .439$ $p = 0.513$ (.01) | $F_{1,27} = .792$ $p = 0.381$ (.02) | $F_{1,27} = 0.173$ $p = 0.681$ (.006) |
| Velar insertion distance | $F_{1,27} = 4.873$ $p = 0.036$ (.15) | $F_{1,27} = .002$ $p = 0.968$ (.00) | $F_{1,27} = 0.006$ $p = 0.938$ (.00) |
| Origin-origin | $F_{1,27} = 2.605$ $p = 0.118$ (.08) | $F_{1,27} = .699$ $p = 0.411$ (.02) | $F_{1,27} = 0.015$ $p = 0.902$ (.00) |
| Angle of origin | $F_{1,27} = .119$ $p = 0.733$ (.00) | $F_{1,27} = 1.166$ $p = 0.290$ (.04) | $F_{1,27} = 0.039$ $p = 0.846$ (.00) |
| Velar length | $F_{1,27} = .599$ $p = 0.446$ (.02) | $F_{1,27} = 28.386$ $p < 0.0005^*$ (.51) | $F_{1,27} = 0.003$ $p = 0.960$ (.00) |
| Velar thickness | $F_{1,27} = .375$ $p = 0.545$ (.01) | $F_{1,27} = 55.4$ $p < 0.0005^*$ (.67) | $F_{1,27} = 0.379$ $p = 0.543$ (.01) |
| VP Ratio | $F_{1,27} = 3.610$ $p = 0.068$ (.11) | $F_{1,27} = 26.580$ $p < 0.0005^*$ (.49) | $F_{1,27} = 1.156$ $p = 0.292$ (.041) |

Effects of Sex and Race on Craniometric Measures

Except in the case of head circumference, subsequent sections of this paper report the effects after removing the effects of the covariate of cranial size (Tables B6 and B7). Sex did not have a significant effect on any of the craniometric measures at the adjusted significance level of .0025 (Table B6). A significant racial effect was evident only for face height ($F_{(1,27)} = 23.99$, $p < .0005$). Black participants had a significantly greater mean value for face height ($p < .0025$; 11%

increase) compared to White participants, as determined by the estimated marginal means. A small to moderate effect size (.47) was observed for face height.

Effects of Sex and Race on Velopharyngeal Measures

Sex did not have a significant effect on any of the velopharyngeal measures at the adjusted significance level of .0025 (Table B7). The extravelar segment of the levator muscle was found to be the same in males and females ($M = 24.8\text{mm}$) after removing the effect of head circumference. The levator muscle measures did not demonstrate a statistically significant effect for race ($p > .0025$). However, significant ($p < .0005$) racial differences were observed for mean velar length ($F_{(1,27)} = 28.3, p < .0005$) and thickness ($F_{(1,27)} = 55.4, p < .0005$). Black participants demonstrated a significantly longer (38% longer) and thicker (40% larger) velum compared to White participants after adjusting for head circumference. There were no significant interaction effects of sex and race on the muscle measures. There was a significant racial effect for velopharyngeal ratio ($p < .0005$), with Black participants demonstrating a larger ratio than White participants. Analyses showed a moderate to large effect size for velar length (.51) and thickness (.67). A small to moderate effect size was noted for velopharyngeal ratio (.49).

Craniometric and Muscle Prediction Models

Multiple linear regression models were used to determine whether craniometric measures could predict the levator muscle and velar configurations and shapes (Table D8). It was hypothesized that cranial features could predict levator muscle morphology and orientation given that the cranial base serves as the point of attachment of the levator muscle. Because some of the craniometric measures are strongly correlated, backward selection was used to obtain reduced regression models with fewer predictors. Four of the eight resulting models had significant predictive power (at adjusted significance level of $p < .00625$). These muscle measures include

velar length ($R^2 = .802$), velar thickness ($R^2 = .571$), levator length ($R^2 = .527$), and extravelar length ($R^2 = .382$). The three predictor model (hard palate length, PNS to basion, and NSB angle) model was able to account for 80.2% of the variability in the length of the velum, representing a strong model. The predictive model for extravelar length (hard palate length) could only account for 38.2% of the variability for this muscle measure, indicating a weak model. Hard palate length appeared to be the most common significant craniometric predictor, being present in two muscle prediction models which included extravelar length and velar length.

Table B8.

Results from the multiple linear regression analyses. R^2 value represents the proportion of variation in the dependent variable accounted for by the regression model. The regression equation represents the predictive model. * $p < .05/8 = .00625$. IV = independent variable. Coding for race: 0 = White, 1 = Black. Statistically significant results shown in bold font.

| Dependent variable | Regression Equation | R^2 | Predictors with abbreviation in parenthesis | p-value for IV |
|--------------------|--|-------|---|----------------|
| Levator Length | $\hat{y} = -104.455 + .076(\text{HC}) + 1.825(\text{NS}) + 1.557(\text{SB}) - 1.810(\text{NB}) + .711(\text{NSB})$ | .527 | Head circumference (HC) | .004 * |
| | | | Nasion to sella (NS) | .002 * |
| | | | Sella to basion (SB) | .003 * |
| | | | Nasion to basion (NB) | .004 * |
| | | | NSB angle (NSB) | .002 * |
| Extravolar Length | $\hat{y} = -9.696 + .043(\text{HC}) + .368(\text{HP})$ | .382 | Head circumference (HC) | .025 |
| | | | Hard palate length (HP) | .003 * |
| Origin-Origin | $\hat{y} = -99.821 + .109(\text{HC}) + 2.196(\text{NS}) - 2.439(\text{NB}) + .460(\text{HP}) + .774(\text{NSB})$ | .484 | Head circumference (HC) | .009 |
| | | | Nasion to sella (NS) | .019 |
| | | | Nasion to basion (NB) | .017 |
| | | | Hard palate length (HP) | .028 |
| | | | NSB angle (NSB) | .031 |
| Velar Insertion | $\hat{y} = -42.246 + 1.468(\text{NS}) + 1.310(\text{SB}) - 1.552(\text{NB}) + .459(\text{NSB})$ | .248 | Nasion to sella (NS) | .014 |
| | | | Sella to basion (SB) | .017 |
| | | | Nasion to basion (NB) | .016 |
| | | | NSB angle (NSB) | .035 |
| Velar Length | $\hat{y} = -4.151 + .535(\text{HP}) + .814(\text{PNS}) - .174(\text{NSB}) + 3.716(\text{race})$ | .827 | Hard palate length (HP) | .002 * |
| | | | PNS to basion (PNSB) | .000 * |
| | | | NSB angle (NSB) | .009 |
| | | | Race | .005 * |
| Velar Thickness | $\hat{y} = 3.869 + 2.208(\text{race})$ | .741 | Race | .000 * |

Multiple regression analyses were re-run for those muscle measures that demonstrated a statistically significant difference for race (based on ANCOVA results). The final regression

models are demonstrated in Table B8. These muscle measures included velar length and velar thickness. Race was included as a predictor in the regression models for both velar length and velar thickness. In the case of velar length, the R^2 increased to .827 and the nasion to basion predictor was replaced by race. Significant differences were observed in the regression model for velar thickness. With race included as an independent variable with the craniometric predictors, the regression model revealed that race was the only significant predictor for velar thickness ($p < .0005$). The R^2 value increased from .571 to .741. Thus, the regression model with just race as the predictor explains 74.1% of the variability in velar thickness.

Qualitative Differences

Magnetic resonance images demonstrating velopharyngeal anatomy in the midsagittal image plane are demonstrated in Figure B3. The top three images represent MRI data on Black participants and the bottom three images represent White participants. The most significant qualitative differences are a longer and thicker velum for the Black participants compared to the White participants. This finding is consistent with the quantitative findings from the present study. Consistent with the quantitative findings, no qualitative differences were observed for images in the oblique coronal image plane. All participants displayed a cohesive levator muscle sling with no separation of the levator muscle bundles from the velar midline (Figure B4).

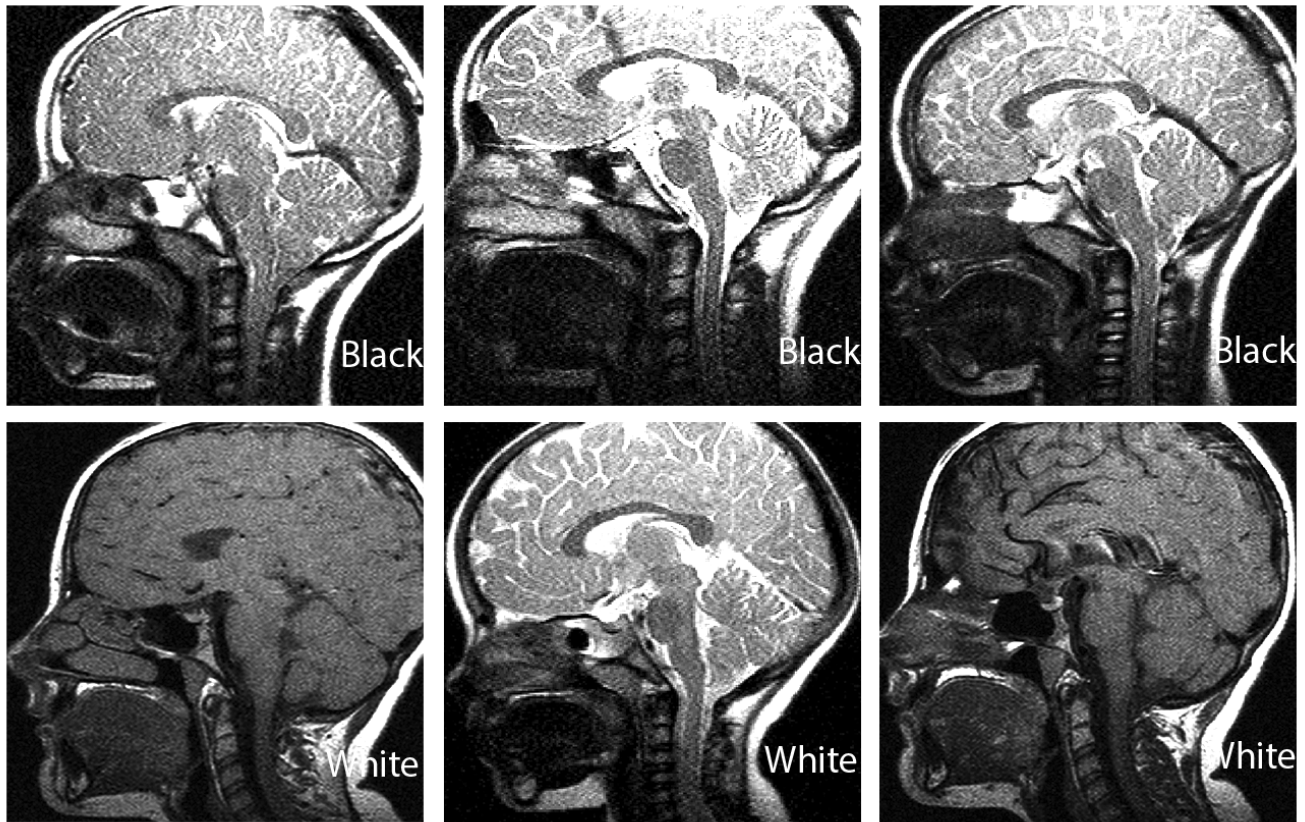

Figure B3. Magnetic resonance images demonstrating qualitative differences in velar length and thickness across different racial groups in the midsagittal plane. Top row (left –right): 7years/male; 6years/female; 5years/male. Bottom row (left-right): 7years/female; 4years/female; 5years/male

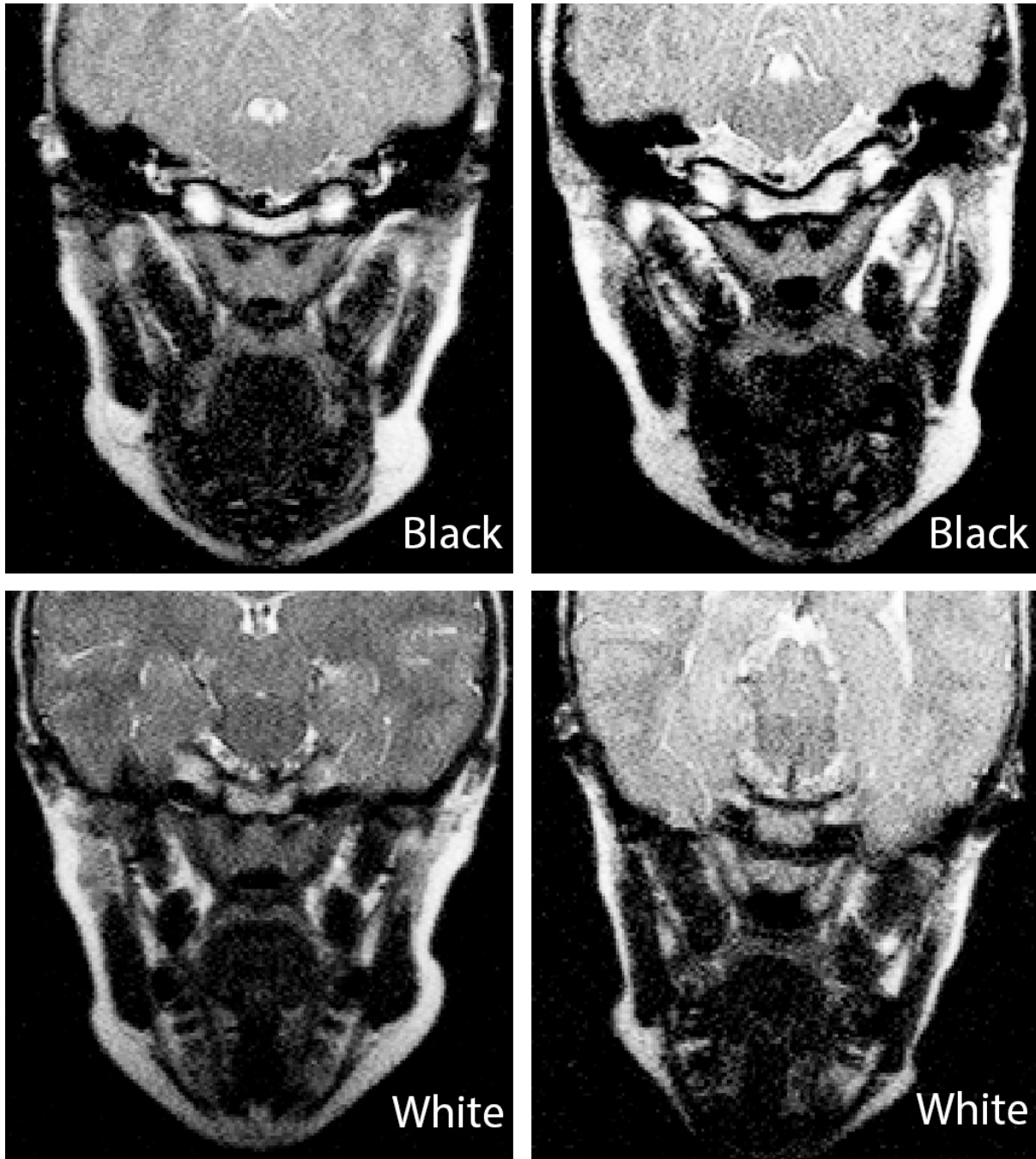


Figure B4. Magnetic resonance images demonstrating cohesive levator muscle sling in the oblique coronal plane.

DISCUSSION

The purpose of this study was to assess craniometric and velopharyngeal anatomy in young Black and White children using MRI. Magnetic resonance images were successfully obtained on all 32 children using a child-friendly scanning protocol with 100% success rate. Vannest et al. (2014) investigated the feasibility of successful completion of MRI scans in 158 children between the ages of 2.5 and 18 years without the use of sedation as part of a large-scale neuroimaging research protocol. Two scan sessions were assessed per subject. The success rates for each session were 0.739 and 0.847 for children aged 2.5 to 6 years. The success rates were higher (over 0.900 for both subjects) for children 7 years and older. Results from the present study demonstrate the feasibility and application of our MRI methodology in providing qualitative and quantitative data on craniometric and velopharyngeal structures in young children as young as four years, without the use of sedation.

Magnetic resonance imaging studies in children present with difficulties such as motion artifacts and behavioral constraints. As such, there is limited literature on craniometric and velopharyngeal structures among children across different racial groups without the use of sedation. Sedation adds significant cost as well as additional risks such as negative effects to anesthesia or sedation medication and suppression of normal breathing (Halliday and Kelleher, 2013). The use of a laryngeal airway mask during sedation may also distort the positioning of oral structures and the velum at rest, which would be disadvantageous for any studies aimed at assessing velopharyngeal structural differences.

Magnetic resonance imaging studies of the velopharyngeal anatomy for this population has been limited to small sample sizes (Tian et al., 2010a; Tian et al., 2010b; Tian et al., 2010c; Kollara & Perry, 2014). The present study improves on current literature by adding to the

craniofacial database on children, especially providing insight into the underrepresented Black child population. To our knowledge, this is the first study to demonstrate craniometric and velopharyngeal differences as a function of race in Black children between four and eight years of age.

Findings from the present study demonstrate that craniometric measures did not vary significantly based on sex and that only one craniometric predictor (face height) varied significantly based on race. Studies have indicated that sexual dimorphism in children is evident closer to 14 years of age for most skeletal cranial structures (Ursi, Trotman, McNamara, & Behrents, 1993). Consistent with previous reports, there were no differences based on sex for the measures of sella to basion and NSB angle across participants (Lewis & Roche, 1977; Ursi et al., 1993). Significant sexual dimorphism for the measure of nasion to sella was not observed as reported by Ursi et al. (1993). Anthropometric measures in the horizontal dimension such as facial width have been reported to differ significantly between older adult Black and White females, with Black females demonstrating greater facial width compared to White females (Porter & Olsen, 2001). No such significant race effects in the horizontal dimension were indicated in our data for the younger child population. The discrepant findings between children and adults regarding face width may be due to the effects of pubertal changes on craniofacial characteristics.

Findings in the younger population in the present study are not consistent with variations reported in the adult population (Perry et al., 2014). The cranial measures of nasion to sella (Japanese < Black < White), sella to basion (Black < White < Japanese), NSB angle (White/Japanese < Black), and face width (White < Japanese/Black) were found to vary significantly in adults based on race (Perry et al., 2014). In the present study, it was found that

only facial height differed across the racial groups of Black and White. It has been established that there is a strong pubertal effect for cranial measures (Roche & Lewis, 1974; Ursi et al., 1993). It is likely that data in the present study demonstrate a pre-pubertal effect of growth on skeletal and soft tissue measures in which differences seen in adults are not consistent with those among the pre-pubertal child population. Further studies should investigate the effects of sex and race differences as a function of pre- and post-pubertal growth changes. Contradictory findings on craniometric and velopharyngeal anatomy in adult and child populations further highlight the need for longitudinal data across the life-span on relevant craniometric and velopharyngeal measurements.

A consistent trend was observed for the measures of sella to basion, pharyngeal depth and anterior cranial base angle (NSB angle), with Black participants having larger values for all three measures, thus contributing to a larger pharyngeal dimension. Black participants also demonstrated significantly greater face height values. In a similar study on adults (Perry et al., 2014), it was hypothesized that although Black participants showed greater anterior to posterior distances, the increased length and thickness of the velum would counteract any differences in the velopharyngeal port dimensions. The authors, however, did not report objective measures regarding the velopharyngeal port ratio. Similarly, in the present study, it was thought that the increased length and thickness demonstrated by these participants would counteract any effects of race on the dimensions of the velopharyngeal port, as measured by the velopharyngeal ratio. However, a statistically significant racial effect was observed for this measure, which could be due to the pre-pubertal growth effects on the skeletal and pharyngeal morphology.

Anthropometric studies have suggested that anatomic variations may predispose certain racial groups to clefting (Chung & Kau, 1985). Chung and Kau (1985) hypothesized that clefting

may be related to these morphological cranial variations, which in turn could be related to inherent craniofacial variations based on race. Current research aims to identify the relationship of genetics to cleft markers (Lidral & Moreno, 2005; Vieira et al., 2015). However, to our knowledge, no studies have investigated gene association related to clefting, across different racial groups.

Velopharyngeal measures are consistent with data reported by previous studies (Kollara & Perry, 2014). Kollara and Perry (2014) reported data on similar velopharyngeal measures (velar length, velar thickness, levator length, and angles of origin), however, data were not separated by race or sex. In a similar study on adults (Perry et al., 2014), it was found that adult males demonstrated significantly longer extravelar and intravelar muscle segments compared to females. However, in the present study it was noted that males and females presented with the same extravelar length in this age group ($M = 24.8\text{mm}$), after removing the effects of cranial size. As such, there were no significant effects of sex on any of the velopharyngeal measures among the young child population. The effects of growth on the levator muscle measures warrants further investigation. Consistent with reported findings in adult participants (Perry et al., 2014), Black participants were observed to have a significantly longer and thicker velum in comparison to White participants. Future studies investigating similar velar variables may thus need to control for race but not sex.

The levator muscle origin is bound by craniofacial structures and we anticipated that variations in skeletal craniofacial structures may affect the positioning of the levator muscle. As such, it was hypothesized that regression models could predict soft muscle measures from hard tissue (craniometric) structures. Predictive models with high R^2 values were however only present for velar length and thickness. There are no significant predictive models for the levator

muscle measures. Hard palate length was observed to be the more common craniometric predictor, as it was present in two muscle prediction models - extravelar length and velar length. The multiple linear regression analyses demonstrated in the present study may serve as a preliminary indicator of the potential utility of craniometric markers in assessing muscle morphology in clinical populations. It may be particularly relevant in clinically challenging populations such as in individuals with 22q11.2 deletion syndrome, where abnormal craniofacial and velopharyngeal characteristics are exhibited, but the relationship or effect that one may have on the other is not well understood. For example, studies have documented variations in hard palate length, cranial base angle, and velar length among this clinical population (Arvystas & Shprintzen, 1984; Heliovaara & Hurmerinta 2006; Ruotolo et al., 2006). Punjabi, Holshouser, D'Antonio, and Kuehn (2002) observed individuals with 22q11.2 deletion syndrome to have an abnormal levator muscle characterized as being thin and hypoplastic. However, no studies have determined if the abnormal levator muscle variables are correlated to abnormal cranial base values or if a shorter hard palate could result in a shorter velum. Further studies should investigate how prediction models can be incorporated into modeling and analysis of the biomechanics of the velopharyngeal port.

It has been established that understanding normal anatomy is necessary in evaluating and determining dysmorphic anatomy (Perry, Kuehn, & Sutton, 2013). As such there is a need for continued research regarding the anatomy and function of the velopharyngeal mechanism. Recent work on computational modeling (Inouye et al., in press) has discussed the potential of using normal anatomical data to systematically investigate *in vivo* function of the velopharyngeal mechanism. The computational model in that study was built using MRI data from previously reported investigations and was used to determine how surgical parameters could be altered

using patient pre-surgical anatomy. Data from this study may add to the normative velopharyngeal and craniofacial database for children.

Limitations of present study

Limitations of the present study include a small sample size and the inclusion of only two racial groups (Black and White). Height and weight were not included as covariates (in addition to head circumference) due to the small sample size and the correlation among variables of height, weight, and head circumference. Horner et al. (1989) demonstrated obesity (BMI greater than 30) is associated with fatty tissue around the velum. Adult control participants who were not obese, yet showed variations in weight, did not display differences in velar thickness. No participants in the present study were classified as obese. However, studies have not demonstrated whether weight or height is correlated to any velar or pharyngeal measures among the child population. Another limitation of the study is the lack of muscle activity data during speech tasks. A limitation of these anatomical structural data is the lack of functional variations of the velopharyngeal musculature. Our laboratory is currently investigating the functional variations among child populations using dynamic MRI.

CONCLUSION

The MRI imaging methodology detailed in this study describes an effective means to assess craniofacial and velopharyngeal characteristics in young children without the use of sedation. Future investigations may adopt the behavioral protocol outlined in this study across larger study groups and for clinically challenging populations such as children with 22q11.2 deletion syndrome. The present study provides separate craniofacial and velopharyngeal values for young Black and White children. Although there was no significant race effect on the levator muscle, significant racial variations were noted for velar length and thickness. The paucity of

normative three-dimensional data is an obstacle for surgical stimulation procedures (Altobelli et al., 1993). Data from this study will add to the growing database of craniometric and velopharyngeal measurements for use in three-dimensional reconstruction and modeling, and can be used to examine morphological variations with respect to race and sex.

REFERENCES

- Altobelli, D. E., Kikinis, R., Mulliken, J. B., Cline, H., Lorensen, W., & Jolesz, F. (1993). Computer-assisted three-dimensional planning in craniofacial surgery. *Plastic and Reconstructive Surgery*, 92(4), 576-585.
- Arvystas, M., & Shprintzen, R. J. (1984). Craniofacial morphology in the velo-cardio-facial syndrome. *Journal of Craniofacial Genetics and Developmental Biology*, 4(1), 39-45.
- Barsoumian, R., Kuehn, D. P., Moon, J. B., & Canady, J. W. (1998). An anatomic study of the tensor veli palatini and dilatator tubae muscles in relation to eustachian tube and velar function. *Cleft Palate-Craniofacial Journal*, 35(2), 101-110.
- Bae, Y., Kuehn, D. P., Sutton, B. P., Conway, C. A., & Perry, J. L. (2011). Three-dimensional magnetic resonance imaging of velopharyngeal structures. *Journal of Speech, Language, and Hearing Research*, 54(6), 1538-45.
- Chung, C. S., & Kau, M. C. W. (1985). Racial differences in cephalometric measurements and incidence of cleft lip with or without cleft palate. *Journal of Craniofacial Genetics and Developmental Biology*, 5, 341-349.
- Chung, C. S., Runck, D. W., Bilben, S. E., & Kau, M. C. (1986). Effects of interracial crosses on cephalometric measurements. *American Journal of Physical Anthropology*, 69(4), 465-472.
- Ettema S. L., Kuehn D. K., Perlman, A. L., & Alperin, N (2002). Magnetic resonance imaging of the levator veli palatini muscle during speech. *Cleft Palate-Craniofacial Journal*, 39(2), 130-144.
- Farkas, L. G., Katic, M. J., & Forrest, C. R. (2007). Comparison of craniofacial measurements of young adult African-American and North American white males and females. *Annals of Plastic Surgery*, 59(6), 692-698.
- Ha, S., Kuehn, D. P., Cohen, M., & Alperin, N. (2007). Magnetic resonance imaging of the levator veli palatini muscle in speakers with repaired cleft palate. *Cleft Palate-Craniofacial Journal*, 44(5), 494-505.
- Halliday, M., & Kelleher, J. (2013). Question 1: Is sedation necessary for MRI in an infant? *Archives of Disease in Childhood*, 98(10), 825-828.
- Heliovaara, A., & Hurmerinta, K. (2006). Craniofacial cephalometric morphology in children with CATCH 22 syndrome. *Orthodontics & Craniofacial Research*, 9(4), 186-192.
- Horner, R. L., Mohiaddin, R. H., Lowell, D. G., Shea, S. A., Burman, E. D., Longmore, D. B., & Guz, A. (1989). Sites and sizes of fat deposits around the pharynx in obese patients with

- obstructive sleep apnea and weight matched controls. *European Respiratory Journal*, 2(7), 613-622.
- Huang, M. H., Lee, S. T., & Rajendran, K. (1998). Anatomic basis of cleft palate and velopharyngeal surgery: Implications from a fresh cadaveric study. *Plastic and Reconstructive Surgery*, 101(3), 613-627.
- Inouye, J. M., Pelland, C. M., Lin, K. Y., Borowitz, K. C., & Blemker S.S. (in press). A Computational Model of Velopharyngeal Closure for Simulating Cleft Palate Repair. *Journal of Craniofacial Surgery*.
- Kaufman, J.S., & Cooper, R. S. (2001). Commentary: Considerations for use of racial/ethnic classification in etiologic research. *American Journal of Epidemiology*, 154(4), 291-298.
- Kollara, L., & Perry, J. L. (2014). The effects of gravity on the velopharyngeal structures in children using upright magnetic resonance imaging. *Cleft Palate-Craniofacial Journal*. Advance online publication. doi: 10.1597/13-107.
- Kuehn, D. P., & Kahane, J. C. (1990). Histologic study of the normal human adult soft palate. *Cleft Palate-Craniofacial Journal*, 27(1), 26-35.
- Kuehn, D. P., & Moon, J. B. (1994). Levator veli palatini muscle activity in relation to intraoral air pressure variation. *Journal of Speech, Language, and Hearing Research*, 37(6), 1260-1270.
- Lewis, A. B., & Roche, A. F. (1977). The saddle angle: constancy or change? *Angle Orthodontist*, 47(1), 46-54.
- Lindman, R., Paulin, G., & Stål, P. S. (2001). Morphological characterization of the levator veli palatini muscle in children born with cleft palates. *Cleft Palate-Craniofacial Journal*, 38(5), 438-448.
- Lindral, A.C., & Moreno, L. M. (2005). Progress toward discerning the genetics of cleft lip. *Current Opinion in Pediatrics*, 17(6), 731-739.
- Mehendale, F. V. (2004). Surgical anatomy of the levator veli palatini: a previously undescribed tendinous insertion of the anterolateral fibers. *Plastic and Reconstructive Surgery*, 114(2), 307-315.
- Moon, J. B., & Kuehn, D.P. Anatomy and physiology of normal and disordered velopharyngeal function for speech. In: Bzoch KR eds. *Communication Disorders Related to Cleft Lip and Palate*, 5th ed. Austin, TX: Pro-ed; 2004:67-98.
- Perry, J. L., Kuehn, D., & Sutton, B. (2013). Morphology of the levator veli palatini muscle using magnetic resonance imaging. *Cleft Palate Craniofacial Journal*, 50 (1), 64-75.

- Perry, J. L., Kuehn, D., Sutton, B., & Gamage, J. (2014). *Anthropometric analysis of the velopharynx and related craniometric dimensions in three adult populations using MRI*. Manuscript submitted for publication.
- Porter, J. P., & Olson, K. L. (2001). Anthropometric facial analysis of the African American woman. *Archives of Facial Plastic Surgery*, 3(3), 191-197.
- Punjabi, A. P., Holshouser, B.A., D'Antonio, L. L., & Kuehn, D.P. (2002, May). *Magnetic resonance imaging of the velopharynx in patients with velocardiofacial syndrome*. Paper session presented at the meeting of of the American Cleft Palate–Craniofacial Association, Seattle, Washington.
- Roche, A. F., & Lewis, A. B. (1974). Sex Differences in the elongation of the cranial base during pubescence. *Angle Orthodontist*, 44 (4), 279-294.
- Ruotolo, R. A., Veitia, N.A., Corbin, A., McDonough, J., Solot, C.B., McDonald-McGinn, D.,... . Kirschner, R. E. (2006). Velopharyngeal anatomy in 22q11.2 deletion syndrome: a three-dimensional cephalometric analysis. *Cleft Palate Craniofacial Journal*, 43(4), 446-56.
- Seaver, E. J., & Kuehn, D. P. (1980). A cineradiographic and electromyographic investigation of velar positioning in non-nasal speech. *Cleft Palate Journal*, 17(3), 216-226.
- Tian, W., Li, Y., Yin, H., Zhao, S., Li, S., Wang, Y., & Shi, B. (2010a). Magnetic resonance imaging assessment of velopharyngeal motion in Chinese children after primary palatal repair. *Journal of Craniofacial Surgery*, 21(2), 578-587.
- Tian, W., Yin, H., Li, Y., Zhao, S., Zheng, Q., & Shi, B. (2010b). Magnetic resonance imaging assessment of velopharyngeal structures in Chinese children after primary palatal repair. *Journal of Craniofacial Surgery*, 21(2), 568-577.
- Tian, W., Yin, H., Redett, R. J., Shi, B., Shi, J., Zhang, R., & Zheng, Q. (2010c). Magnetic resonance imaging assessment of the velopharyngeal mechanism at rest and during speech in Chinese adults and children. *Journal of Speech, Language, and Hearing Research*, 53(6), 1595-1615.
- Ursi, W.J., Trotman, C.A., McNamara, J. A., & Behrents, R. G. (1993). Sexual dimorphism in normal craniofacial growth. *Angle Orthodontist*, 63 (1), 47-56.
- Vannest, J., Rajagopal A., Cicchino, N.D., Franks-Henry, J., Simpson, S.M., Lee, G.,...CMIND Authorship Consortium (2014). *Neuropediatrics*, 45(6), 370-377.
- Vieira, A. R., de Carvalho, F. M., Johnson, L., DeVos, L., Swailes, A. L., Weber, M. L., & Deeley, K. (2015). Fine Mapping of 6q23.1 Identifies *TULP4* as Contributing to Clefts. *Cleft Palate-Craniofacial Journal*, 52 (2)128-134

Williamson, M. A., Nawrocki, S. P., & Rathbun, T. A. (2002). Variation in midfacial tissue thickness of African-American children. *Journal of Forensic Science*, 47(1), 25

CHAPTER 5

STUDY III

Examining A New Method to Studying Velopharyngeal Structures in A Child with 22q11.2 DS³

ABSTRACT

To date, no studies have imaged the velopharynx in children with 22q11.2 deletion syndrome (22q11.2 DS) without the use of sedation. Dymorphology in velopharyngeal structures has been shown to have significant negative implications on speech among these individuals. This single case study was designed to assess the feasibility of a child-friendly MRI scanning protocol in this clinically challenging population and to determine the utility of this MRI protocol for future work in this area. One 6-year-old White female diagnosed with 22q11.2 DS was imaged using a child-friendly, non-sedated MRI protocol. Quantitative and qualitative measures of the velopharyngeal area and associated structures were evaluated and comparisons were made to age-matched control subjects with normal velopharyngeal anatomy. Magnetic resonance imaging data were successfully obtained using the child-friendly scanning protocol in the subject in the present study. Quantitative and qualitative differences of the levator muscle and associated velopharyngeal structures were noted. Using these MRI and structural analyses methods, insights related to muscle morphology can be obtained and considered as part of the research and clinical examination of children with 22q11.2 DS. The imaging protocol described in this study presents an effective means to counteract difficulties in imaging young children.

³ Kollara, L., Schenck, G. C., Perry, J. L., & Jaskolka, M. (2016). Examining A New Method to Studying Velopharyngeal Structures in A Child with 22q11.2 DS. Manuscript accepted with minor revisions for publication in the Journal of Speech, Language, and Hearing Research.

INTRODUCTION

Approximately 75% of individuals with 22q11.2 deletion syndrome (22q11.2 DS) demonstrate structural velopharyngeal abnormalities (Chegar, Tatum, Marrinan, & Shprintzen, 2006). The most common forms of palatal abnormalities reported are submucous cleft palate (44%), occult submucous cleft palate (38%), and overt cleft palate (18%) (Shprintzen, 2008; Veerapandiyan et al., 2011). Limited studies have investigated the characteristics of the velum and velar muscles in individuals with 22q11.2 DS. In a lateral cephalometry investigation, (Veerapandiyan et al., 2011) reported subjects with 22q11.2 DS to have decreased velar length, and an abnormal anterior location of velar dimple (normal anatomy = 80% of length of velum during phonation; 22q11.2 DS = 57.3%). Conversely, (Ruotolo et al., 2006) found no significant variations in velar length and thickness. These studies, however, have primarily used two dimensional assessment methods that cannot provide a view of velopharyngeal muscles. Additionally, radiation exposure during cephalometry limits the repeatability for use in the pediatric population.

Magnetic resonance imaging (MRI) offers a significant benefit to understanding the complex velopharyngeal system because it is the only imaging modality that enables visualization of the internal musculature *in vivo*. The levator veli palatini (levator) muscle has been described as being thin and hypoplastic at rest in individuals with 22q11.2 DS (Punjabi, Holshouser, D'Antonio, & Kuehn, 2002). However, these findings have not been published and there are no quantitative data on the morphologic differences that exist in the levator muscle for this population when compared to individuals with normal velopharyngeal anatomy. Although morphological variations have been suggested in individuals with 22q11.2 DS, the exact nature and extent of this dysmorphology is still unknown. (Park, Ahn, Jeong, & Baek, 2015) presented a

quantitative analysis of the levator muscle thickness and symmetry in 17 children with 22q11.2 DS. The authors compared findings among the study group to measures from children with submucous cleft palate, thus limiting the applicability of the results. Additionally, the study investigated only two variables (i.e., levator thickness and levator symmetry) and the MRI methods included the use of sedation. Sedation and the use of a laryngeal airway mask often distorts the positioning of the velum and oropharyngeal structures at rest. Obvious limitations of sedation further limit the use of MRI with sedation for research and clinical methods. Thus, a non-sedated imaging protocol that enables visualization of the velopharyngeal port and musculature without distorting the oral and pharyngeal structures is beneficial for advancing our knowledge and understanding of the muscle morphology and implications on speech outcomes among children with 22q11.2 DS.

Behavioral constraints and motion artifacts are two core issues that limit the utility of MRI studies in the pediatric population, particularly for use in complex clinical cases such as in individuals with 22q11.2 DS. The utility of imaging protocols in children with normal velopharyngeal anatomy and children with cleft palate without craniofacial disorders syndromes has been described (Kollara & Perry, 2014; Kollara, Perry, & Hudson, 2016; Tian, Yin et al., 2010; Tian, Li et al., 2010). However, no studies have attempted to translate a similar protocol across clinically complex cases such as children with 22q11.2 DS. Specific aversions, including those related to natural environment (e.g., loud noises and claustrophobia) are increasingly more common in children with 22q11.2 DS compared to children without such diagnosed syndromes (Antshel et al., 2006) which further limits the utility of MRI. These individuals also present with an increased risk of many psychiatric issues such as anxiety disorders, psychosis, mood

disorders, and attention deficit hyperactivity disorder (Tang et al., 2014). As such, traditionally, MRI data have been obtained in this population only with the use of sedation.

Sedation, as commonly used during MRI, can be associated with adverse effects including a limited time window to complete the scan while under anesthesia, suppression of normal breathing, and additional medication side effects (Halliday & Kelleher, 2013). Additionally, as previously stated, the use of a laryngeal airway mask could distort the oropharyngeal areas of interest. To our knowledge, no studies to date have utilized MRI without sedation in young children with 22q11.2 DS to examine velopharyngeal muscle morphology and associated structures. The purpose of this study was to assess the feasibility of a child-friendly MRI scanning protocol to visualize the velopharyngeal musculature in a young child diagnosed with 22q11.2 DS, without the use of sedation. Additionally, results from this case study provide preliminary quantitative data of velopharyngeal structures and muscles in a young child with 22q11.2 DS in comparison to an age matched non-cleft control group.

METHOD

Participant

In accordance with the Institutional Review Board at East Carolina University (Greenville, NC), one 6-year-old White female diagnosed with 22q11.2 DS was recruited to participate in the study. The patient was initially referred to the Department of Communication Sciences and Disorders at East Carolina University for concerns related to articulation and resonance. The patient presented with a complicated surgical history, including multiple pressure equalization tubes, tonsillectomy and adenoidectomy completed at 3 years of age, and additional surgical procedures completed at a later age to remove residual regrowth of adenoidal tissue.

Adenoidectomy was reportedly done to alleviate recurrent respiratory infections. At the time of the referral, the patient was receiving speech therapy through her local school district for her articulation disorder. However, her speech-language pathologist had concerns related to resonance and minimal progress noted in speech therapy. Based on a comprehensive evaluation of articulation and resonance evaluation at our clinic, it was determined that the patient presented with compensatory articulation errors (i.e., primarily glottal stops), severe hypernasality (i.e., rating of 3 on a 4-point scale where 0=normal, 1=mild, 2=moderate, and 3=severe), and consistent audible nasal air emission. Results of the evaluation are provided below:

Orofacial examination

An orofacial examination revealed multiple characteristic features of 22q11.2 DS including a thin upper lip, bulbous nasal tip, protuberant ears, narrow palpebral fissures, and a straight facial profile. An oral mechanism exam revealed an intact palate with no signs of a submucous cleft palate (no bifid uvula, bony notch on posterior margin of hard palate, or zona pellucida). During sustained phonation of the vowel /a/, velar elevation appeared minimal.

Perceptual articulation and resonance assessments

The patient demonstrated severe hypernasality across all speech tasks. Audible nasal air emission and facial/nasal grimacing during production of multiple pressure consonants were noted. The patient presented with cleft-specific compensatory articulation errors including glottal stops, mid-dorsum palatal stops, pharyngeal fricatives, and a posterior nasal fricative. Speech intelligibility was considerably affected based on the severity of velopharyngeal dysfunction and compensatory articulation errors.

Aerodynamic pressure flow

The PERCI SARS pressure flow system (Microtronics, Chapel Hill, NC) was utilized to calculate mean velopharyngeal orifice size area in centimeters squared during the production of the single, bi-syllabic word “hamper”. The patient presented with a mean velopharyngeal orifice size area of 0.10 cm², representing borderline-inadequate closure based on values defining adequate versus inadequate closure for oral consonants.

MRI Behavioral Training

To avoid negative side effects related to sedation, the MRI examination was performed without sedation using an established child-friendly behavioral protocol (Kollara & Perry, 2014; Kollara et al., 2016). The first step in the behavioral protocol was to familiarize the patient with the scanning process. The patient explored the MRI machine and scanning room with the parent before the exam. The MRI scanning experience was described to the child as a feeling of being in a spaceship to lessen the fear of participating in a medical exam. There was no coercion, and the investigator proceeded with the study only after determining that the patient was comfortable with the scanning process. The parent was in the scanning room for the entire duration of the scan. The investigator communicated with the patient throughout the exam via a speaker-microphone system between the scanning and control rooms. The patient was frequently asked about her comfort level and given a panic button. The patient listened to music through headphones during the MRI study to minimize distraction and to increase patient comfort. Small foam cushions were placed in the head coil on either side of the patient’s head and the patient had her hand wrapped around a pillow to minimize motion artifacts.

Imaging protocol

The patient was scanned in the supine position. Magnetic resonance images were acquired using a 1.5 Tesla Philips Intera scanner and a high resolution, T1- weighted turbo-spin-echo (TSE) 3D anatomical scan utilizing SENSE (Sensitivity Encoding) technology. The total time in the MRI magnet for the scan session was approximately 20 minutes. Anatomical scans were obtained in the sagittal and oblique coronal image planes at rest. The MRI images were transferred into Amira 5 Visualization Volume Modeling software (Visage Imaging GmbH, Berlin, Germany). Amira has a native Digital Imaging and Communication in Medicine (DICOM) support program that enables preservation of original geometry of the data.

The quantitative measures included levator muscle length, origin to origin distance, levator muscle angle origin, velar length, velar thickness, and the posterior nasal spine (PNS) to posterior pharyngeal wall distance (PPW). The measures were chosen based on comparable studies in literature (Kollara et al., 2016; Perry, Kollara, Kuehn, Sutton, & Fang, 2016; Ruotolo et al., 2006; Veerapandiyan et al., 2011). The measures are described in detail in Kollara et al. (2016) and (Perry et al., 2016). In brief, the levator muscle length refers of the length of the levator muscle measured from its origin at the base of the skull to its insertion into the velum. Origin to origin is measured as the distance between the points of origin of the levator muscle on the right and left sides. Levator muscle angle origin is the angle at which the levator muscle descends from the base of the skull. The length of the velum is measured from the PNS to the tip of the uvula and its thickness is the distance from the velar knee to the velar dimple.

RESULTS AND DISCUSSION

Magnetic resonance imaging data were successfully obtained using the child-friendly scanning protocol in the young participant with 22q11.2DS. Behavioral imaging protocols have been found to be effective in non-syndromic children and children with cleft palate (Kollara & Perry, 2014). Results from this study indicate that this protocol can be translated to a population with known psychiatric issues such as anxiety disorders and psychosis. A non-sedated imaging protocol has advantages such as minimizing significant medical costs and eliminating risks such as adverse effects to sedation medication. Studies have expressed concerns that anesthesia may have a negative effect on neurologic development and function (Loepke & Soriano, 2008; Sun, 2010). As such, the applications of a non-sedated imaging protocol as described in this case report may be advantageous across various clinical settings.

Using this described MRI protocol, the levator muscle was visualized in the oblique coronal image plane and multiple image planes provide additional views of the velopharyngeal portal and musculature. These are insights that cannot be obtained using traditional imaging methods commonly used in this clinical population, such as nasopharyngoscopy and cephalometry. Qualitatively, the levator appeared as a small U-shaped muscle arrangement with no suspected attachment of a segment of the levator fibers to the posterior margin of the hard palate (Figure C1).

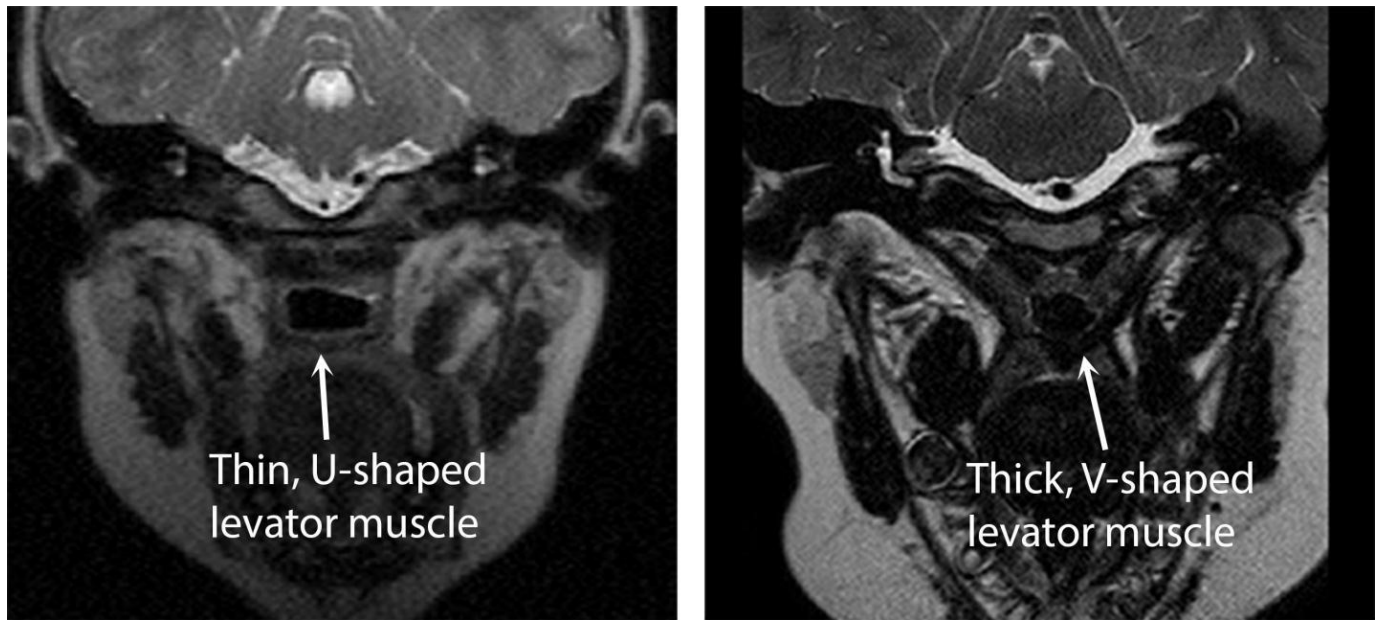


Figure C1. Side-by-side comparison of the levator muscle in the oblique coronal image plane. The patient (left image) demonstrates a thinner, U-shaped levator muscle compared to an age- and sex-matched control (right image).

However, the muscle appeared thin and reduced in overall size (length) compared to an age- and sex-matched control on the oblique coronal image (Kollara et al., 2016; Perry et al., 2016). Quantitative data obtained in the oblique-coronal and midsagittal image planes were compared to an age-matched normative cohort reported by Perry et al. (2016) (Table C1).

Table C1.

Velopharyngeal measures in comparison to an age matched cohort. Mean for all velopharyngeal variables represented in mm with the exception of angle of origin degree (represented in degrees)

| Measures | Patient's values | 6 year old cohort (Perry et al., 2015) |
|--------------------------------|-------------------------|---|
| Levator muscle length | 23.20 | 35.0 (4.7) |
| Origin to origin | 27.89 | 56.0 (4.8) |
| Levator muscle angle of origin | 80.4 | 55.8 (4.2) |
| Velar length | 16.5 | 27.0 (3.3) |
| Velar thickness | 5.3 | 7.4 (1.4) |
| PNS to PPW | 25.1 | 19.1 (4.8) |

Quantitative analyses revealed the levator muscle to be substantially shorter (23.20 mm) in the patient with 22q11.2 DS compared to the normative data (M = 35.0, SD = 4.7). A decreased distance between levator muscle origins (27.89 mm) at the cranial base was also noted (mean for control group = 56.0 mm). It was of interest to note that the angle at which the levator muscle descends from the skull base was closer to 90 degrees rather than the typical acute angle value seen in control subjects (M = 55.8, SD = 4.2). This observation may be due to cranial base variations that are commonly reported in the 22q11.2 DS population (Arvystas & Shprintzen, 1984; Ruotolo et al., 2006).

Additional velopharyngeal measures were analyzed in the midsagittal image plane (Figure C2). Consistent with findings reported in previous investigations (Veerapandiyam et al., 2011), the velum was shorter (16.5 mm) and thinner (5.3 mm) in the patient with 22q11.2 DS compared to the normative cohort group. These findings are not consistent with reports by (Ruotolo et al., 2006), where no significant variations in velar length and thickness were noted

for 5 children across dissimilar periods of growth (2.9-7.9 years) with 22q11.2 DS. The PNS to PPW distance was greater (25.1 mm) in the study subject with 22q11.2 DS compared to the normative cohort (M = 19.1, SD = 4.8), suggesting a larger pharyngeal depth.

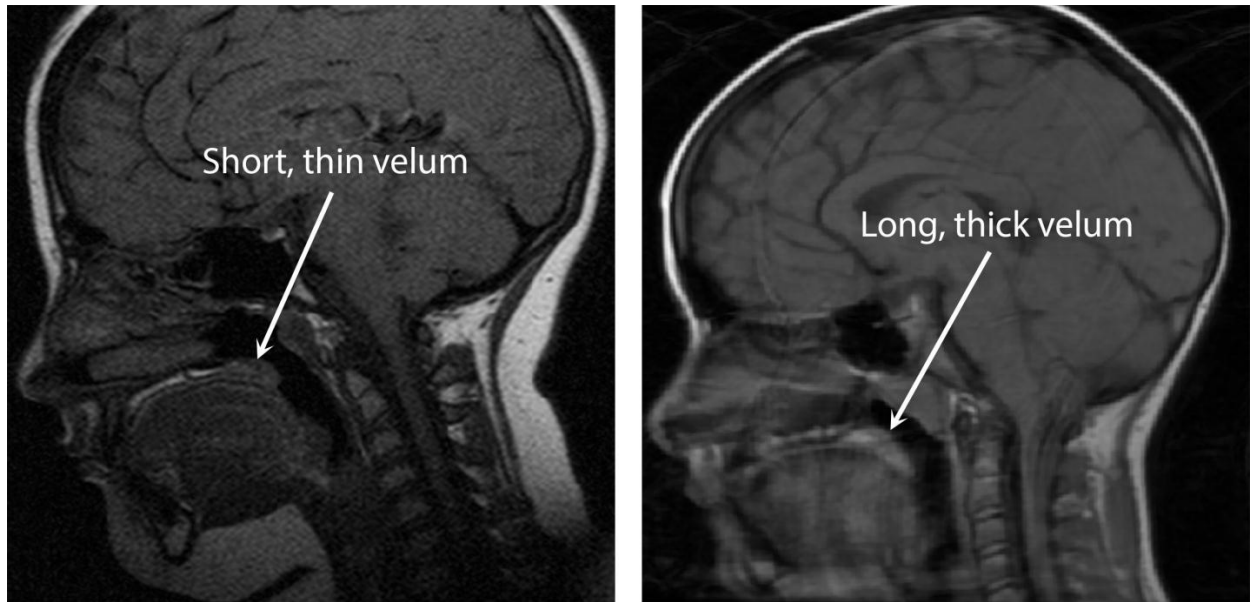


Figure C2. Side-by-side comparison of velopharyngeal structures in the sagittal image plane.

The patient (left image) demonstrates a short, thin velum compared to an age- and sex-matched control (right image).

Limitations of this investigation include the lack of statistical comparisons to a normative cohort and a limited sample size. Future studies should assess the feasibility of this protocol across a larger group of children with 22q11.2 DS and across other clinically challenging populations. Using this described MRI and structural analysis methods described in this report provide a qualitative and quantitative approach to investigating muscle dysmorphology among a challenging clinical population. It is likely that muscle variations among this group may explain

the clinical speech findings and inform the surgical outcomes among this particular clinical population. The behavioral protocol outlined above can also be used to obtain functional data across speech tasks to assess the integrity of the velopharyngeal musculature and the velopharyngeal port characteristics during speech production. Given the increased risk of psychiatric morbidity in these patients, a behaviorally friendly protocol is beneficial in the area of MRI assessment for this population.

CONCLUSION

This innovative clinical report describes a safe and effective method to obtain MRI data in a clinically challenging population without the use of sedation. Preliminary results from this investigation indicate that individuals with 22q11.2 DS may present with unique velopharyngeal variations, particularly related to muscle dysmorphology. Future studies may adopt the behavioral and clinical protocol outlined in this investigation across larger study samples.

REFERENCES

- Antshel, K. M., Fremont, W., Roizen, N. J., Shprintzen, R., Higgins, A. M., Dhamoon, A., & Kates, W. R. (2006). ADHD, major depressive disorder, and simple phobias are prevalent psychiatric conditions in youth with velocardiofacial syndrome. *Journal of the American Academy of Child and Adolescent Psychiatry*, 45(5), 596-603. doi:10.1097/01.chi.0000205703.25453.5a [doi]
- Arvystas, M., & Shprintzen, R. J. (1984). Craniofacial morphology in the velo-cardio-facial syndrome. *Journal of Craniofacial Genetics and Developmental Biology*, 4(1), 39-45.
- Chegar, B. E., Tatum, S. A., 3rd, Marrinan, E., & Shprintzen, R. J. (2006). Upper airway asymmetry in velo-cardio-facial syndrome. *International Journal of Pediatric Otorhinolaryngology*, 70(8), 1375-1381. doi: S0165-5876(06)00059-0 [pii]
- Halliday, M., & Kelleher, J. (2013). Question 1: Is sedation necessary for MRI in an infant? *Archives of Disease in Childhood*, 98(10), 825-828. doi:10.1136/archdischild-2013-304898 [doi]
- Kollara, L., & Perry, J. L. (2014). Effects of gravity on the velopharyngeal structures in children using upright magnetic resonance imaging. *Cleft Palate-Craniofacial Journal*, 51(6), 669-676. doi:10.1597/13-107 [doi]
- Kollara, L., Perry, J. L., & Hudson, S. (2016). Racial variations in velopharyngeal and craniometric morphology in children: An imaging study. *Journal of Speech, Language, and Hearing Research*, 59(1), 27-38. doi:10.1044/2015_JSLHR-S-14-0236 [doi]
- Loepke, A. W., & Soriano, S. G. (2008). An assessment of the effects of general anesthetics on developing brain structure and neurocognitive function. *Anesthesia and Analgesia*, 106(6), 1681-1707. doi:10.1213/ane.0b013e318167ad77 [doi]
- Park, M., Ahn, S. H., Jeong, J. H., & Baek, R. M. (2015). Evaluation of the levator veli palatini muscle thickness in patients with velocardiofacial syndrome using magnetic resonance imaging. *Journal of Plastic, Reconstructive & Aesthetic Surgery*, doi: S1748-6815(15)00191-6 [pii]
- Perry, J. L., Kollara, L., Kuehn, D. P., Sutton, B. P., & Fang, X. (2016). Examining sexual and racial dimorphism among young children using magnetic resonance imaging. *Manuscript Submitted for Publication*,
- Punjabi, A., Holshouser, B. A., D'Antonio, L. L., & Kuehn, D. P. (2002). Magnetic resonance imaging of the velopharynx in patients with velocardiofacial syndrome. *American Cleft Palate Craniofacial Association Annual Meeting*, Seattle, WA.
- Ruotolo, R. A., Veitia, N. A., Corbin, A., McDonough, J., Solot, C. B., McDonald-McGinn, D., . . . Kirschner, R. E. (2006). Velopharyngeal anatomy in 22q11.2 deletion syndrome: A three-

dimensional cephalometric analysis. *Cleft Palate-Craniofacial Journal*, 43(4), 446-456. doi:04-193R [pii]

- Shprintzen, R. J. (2008). Velo-cardio-facial syndrome: 30 years of study. *Developmental Disabilities Research Reviews*, 14(1), 3-10. doi:10.1002/ddrr.2 [doi]
- Sun, L. (2010). Early childhood general anaesthesia exposure and neurocognitive development. *British Journal of Anaesthesia*, 105 Suppl 1, i61-8. doi:10.1093/bja/aeq302 [doi]
- Tang, S. X., Yi, J. J., Calkins, M. E., Whinna, D. A., Kohler, C. G., Souders, M. C., . . . Gur, R. E. (2014). Psychiatric disorders in 22q11.2 deletion syndrome are prevalent but undertreated. *Psychological Medicine*, 44(6), 1267-1277. doi:10.1017/S0033291713001669 [doi]
- Tian, W., Li, Y., Yin, H., Zhao, S. F., Li, S., Wang, Y., & Shi, B. (2010). Magnetic resonance imaging assessment of velopharyngeal motion in chinese children after primary palatal repair. *Journal of Craniofacial Surgery*, 21(2), 578-587. doi: 10.1097/SCS.0b013e3181d08bee [doi]
- Tian, W., Yin, H., Redett, R. J., Shi, B., Shi, J., Zhang, R., & Zheng, Q. (2010). Magnetic resonance imaging assessment of the velopharyngeal mechanism at rest and during speech in chinese adults and children. *Journal of Speech, Language, and Hearing Research*, 53(6), 1595-1615. doi:10.1044/1092-4388(2010/09-0105) [doi]
- Veerapandiyan, A., Blalock, D., Ghosh, S., Ip, E., Barnes, C., & Shashi, V. (2011). The role of cephalometry in assessing velopharyngeal dysfunction in velocardiofacial syndrome. *Laryngoscope*, 121(4), 732-737. doi:10.1002/lary.21449 [doi]

CHAPTER 6

STUDY IV

Variations in Craniofacial and Velopharyngeal Structures among Children with 22q11.2 Deletion Syndrome

INTRODUCTION

22q11.2 deletion syndrome (22q11.2 DS) also known as velocardiofacial syndrome, is the most common genetic cause of velopharyngeal dysfunction (Shprintzen, 2008).

Velopharyngeal dysfunction may be caused due to structural or neurologic issues which adversely affects the closure of the velopharyngeal mechanism. Several factors have been hypothesized to predispose an individual with 22q11.2 DS to velopharyngeal dysfunction, including platybasia (abnormal obtuse angulation of the skull base), palatal anomalies, thin velar and pharyngeal tissues, abnormal palatal and pharyngeal fibers, and adenoid hypoplasia.

Variable findings have been reported related to the bony facial and cranial structures in individuals with 22q11.2 DS (Arvystas & Shprintzen, 1984; Dalben Gda, Richieri-Costa, & Taveira, 2010; Heliovaara & Hurmerinta, 2006; Ruotolo et al., 2006; Shprintzen & Golding-Kushner, 2008). Shprintzen (2008) reported individuals with 22q11.2 DS to have a flattened skull base resulting in a greater pharyngeal depth. Other reports have found no significant differences in the depth of the bony pharynx, nasopharynx, or oropharynx (Dalben Gda et al., 2010; Ruotolo et al., 2006). Numerous studies have demonstrated a more obtuse cranial base angle in individuals with 22q11.2 DS compared to normative control groups (Arvystas & Shprintzen, 1984; Heliovaara & Hurmerinta, 2006; Ruotolo et al., 2006) while other studies found no such variation (Dalben Gda et al., 2010; Glander & Cisneros, 1992; Veerapandiyan et

al., 2011). Cervical abnormalities including cervical vertebrae 1 (C1) anterior arch absence or hypoplasia, shorter cervical height (C1 to C2) and length measures have been reported to be present among individuals with 22q11.2 DS (Veerapandiyan et al., 2011)

Velopharyngeal structural abnormalities are observed in approximately 75% of individuals with 22q11.2 DS (Chegar, Tatum, Marrinan, & Shprintzen, 2006). Ruotolo et al. (2006) observed a greater velopharyngeal width (distance between lateral pharyngeal walls), increased osseous pharyngeal depth (posterior nasal spine to C1), and increased ratio of osseous pharyngeal depth to velar length among children with 22q11.2 DS compared to non-syndromic age-matched control participants. Additional findings include reduced adenoid tissue in the nasopharyngeal cavity, tonsillar hypertrophy, and reduced movement of the lateral pharyngeal walls (Ysunza, Carmen Pamplona, & Santiago Morales, 2011). Veerapandiyan et al. (2011) reported velar findings including a short and thin velum, however, Ruotolo et al. (2006) did not observe such variations.

Heliovaara and Hurmerinta (2006) observed individuals with 22q11.2 DS to have a wide nasopharyngeal area (Veerapandiyan et al., 2011), narrow hypopharyngeal area, delayed development and reduced length of hyoid bone, and larger hyoidal gaps (fusion of hyoidal cornu major and base) compared to age- and sex-matched controls using cephalometric analyses. Conversely, data on 18 Brazilian individuals with 22q11.2 DS compared to age- and sex-matched control groups indicated individuals with 22q11.2 DS have no significant differences in depth of the bony pharynx (distance between posterior nasal spine and basion), nasopharynx, and oropharynx (Dalben Gda et al., 2010). Due to lack of correlation between findings, it is difficult to fully ascertain if velopharyngeal insufficiency can be attributed to larger pharyngeal dimensions as postulated by Arvystas and Shprintzen (1984).

Little is known about the internal velar musculature among individuals with 22q11.2 DS. Conference proceedings (Kuehn, 2003; Punjabi, Holshouser, D'Antonio, & Kuehn, 2002) have suggested the possibility of hypoplasia of the levator veli palatini (levator) muscle and anteriorly attached levator muscle fibers. The levator muscle is the primary muscle responsible for velar elevation, aiding in velopharyngeal closure. However, these findings have not been published. A recent investigation on the thickness and symmetry of the levator muscle in individuals with 22q11.2 DS revealed these individuals have thin and asymmetrical levator muscle bundles (Park, Ahn, Jeong, & Baek, 2015). However, findings among individuals with 22q11.2 DS were compared to a non-syndromic submucous cleft palate group and not a normative age-matched non-cleft cohort. This study also did not examine additional velopharyngeal and muscle features nor provide a description of how these features relate to levels of resonance disorder. Lastly, Park et al. (2015) used sedation which is known to have adverse side effects such as a limited time window to complete the scan while under anesthesia, suppression of normal breathing, and additional medication side effects (Halliday & Kelleher, 2013). Although not stated, the use of a laryngeal mask airway commonly used with sedation, distorts the oral and pharyngeal spaces and can produce variations in velar measures (Perry, Kuehn, Sutton, Goldwasser, & Jerez, 2011). No published studies to date have utilized MRI to image this clinically challenging group, 22q11.2 DS, without the use of sedation.

Surgical options for velopharyngeal dysfunction in individuals with 22q11.2 DS may include Wardill push-back, Furlow palatoplasty, palatopharyngoplasty (using minimal levator veli palatini incisions), pharyngeal flaps, and sphincter pharyngoplasties, and less common options including fat injections (Ysunza, Pamplona, Ortega, & Prado, 2008; Ysunza, Pamplona, Molina, & Hernandez, 2009). Pharyngeal flap techniques have shown to be less effective in

individuals in 22q11.2 DS when compared to non-syndromic cleft palate groups (Losken, Williams, Burstein, Malick, & Riski, 2006). In individuals with 22q11.2 DS, the revision rates for sphincter pharyngoplasty were reported to be twice as high when compared to non-syndromic cleft palate cases (Witt, Cohen, Grames, & Marsh, 1999). In a retrospective review of four individuals with 22q11.2 DS who underwent Furlow double-opposing Z-palatoplasty for primary repair, it was reported that none demonstrated adequate velopharyngeal closure (D-Antonio, Davio, Zoller, Punjabi, & Hardesty, 2001). Milczuk, Smith, and Brockman (2007) observed speech improvements following surgery for velopharyngeal dysfunction, however, results were consistently far worse compared to individuals with non-syndromic cleft palate. This discordance in outcomes highlights the significant need for research related to the morphological variations that exist for this population.

The cranium serves as the point of attachment for the levator muscle. Certain craniometric measures may have an influence on velopharyngeal parameters due to close anatomic proximity to the velopharyngeal port. Perry, Kuehn, Sutton, Gamage, and Fang (2016) and Kollara, Perry, and Hudson (2016) hypothesized that craniofacial markers may predict velopharyngeal structures and muscles in adults and children with normal velopharyngeal anatomy. A limitation of commonly used imaging modalities such as nasopharyngoscopy, multi-view videofluoroscopy and computed tomography include a limited viewpoint to visualize a three-dimensional velopharyngeal port. No studies to date have examined the interaction of craniometric variables relative to the velopharyngeal mechanism in children with 22q11.2 DS. The aims of this study were: 1) to examine craniofacial and velopharyngeal characteristics among children with 22q11.2 DS in comparison to a non-syndromic cohort using a non-sedated MRI scanning protocol (Kollara et al., 2016) and 2) to determine whether craniometric measures

can predict velopharyngeal structure and muscle configurations in children with 22q11.2 DS and in an age and sex-matched comparative cohort group of children with normal velopharyngeal anatomy.

METHOD

Participants

In accordance with the approved Institutional Review Board proposals at East Carolina University and Nationwide Children's Hospital, a total of 30 participants completed the study. The 22q11.2 DS group consisted of 15 children (six males; nine females) diagnosed with a 22q11.2 deletion as confirmed by fluorescence *in situ* hybridization analysis or microarray. The mean age for this groups was 8.04 years (SD = 2.7). Exclusion criteria for the participants with 22q11.2 DS included evidence of an overt cleft palate or history of cleft palate surgery that could potentially affect the regions that were investigated for the study. These participants also did not have any other genetic diagnoses and were no less than six months post adenoidectomy or tonsillectomy. The control group consisted of 15 children (six males; nine females) with normal velopharyngeal anatomy. The mean age for this group was 7.53 years (SD = 2.1). These control participants had no reported history of congenital syndromes or craniofacial anomalies.

In a child with repaired cleft palate and residual hypernasality, the typical age for determining secondary surgical requirements is between four and eight years of age. This is also an important period for speech, language, and communication development. In children with 22q11.2 DS, surgical decisions for velopharyngeal dysfunction are often delayed due to associated medical issues or significant speech-language delays. This investigation also represents the first large scale attempt to image children with 22q11.2 DS without sedation. For these reasons, children between four and 12 years of age were recruited for this study and age

effects were controlled in the statistical analyses. All participants were native English speakers. The control group was sex matched to the 22q11.2 DS group to control for the effects of sex on the variables. Resonance was rated for all participants on a 4-point scale (0 = normal resonance, 1 = mild hypernasality, 2 = moderate hypernasality, 3 = severe hypernasality) by two trained speech language pathologists. All participants in the control group demonstrated normal resonance (rated as a 0 on the 4-point scale). Out of the 15 participants in the 22q11.2 DS group, five participants had normal resonance, seven participants had mild hypernasality, one participant had moderate hypernasality, and two participants had severe hypernasality.

The MRI procedures were systematically conducted as described below:

Behavioral Adaptations

First, it was determined if an MRI exam would be feasible with the participant using the MRI simulator. The MRI simulator is a smaller mockup of the MRI scanner. The scanner bed can move in and out of the tunnel so participants can lay in it and experience what it would be like to be in the MRI scanner. The simulator makes the noises made by the MRI scanner. A small motion tracking device goes around the participant's head and lets the researchers know how much the participant is moving. Each of the participants were in the scanner for 3-5 minutes and the researchers determined whether or not the participant could tolerate the noises while holding still. Once it was determined that the child could undergo the MRI exam, the actual MRI exam was initiated. The MRI simulator procedure was conducted in collaboration with the child life specialists team at Nationwide Children's Hospital. Child life specialists are pediatric health care professionals that help children and families cope with the challenges of hospitalization and prepare for medical procedures. The utilization of child life interventions may decrease the number of pediatric MRI patients who require sedation (Durand, Young, Nagy, Tekes, &

Huisman, 2015). In the present study, the use of child life interventions was an additional benefit to children with 22q11.2 DS who appeared to have a propensity to anxiety as evidenced in the mock scanner.

There was no use of sedation for any of these MRI exams. We utilized a child-friendly MRI protocol (Kollara & Perry, 2014; Kollara, Schenck, Perry, & Jaskolka, 2016; Kollara et al., 2016) which outlines steps to prevent potential pitfalls associated with MRI. In brief, numerous steps were taken to ensure comfort of the participants throughout the exam. All participants were acclimated to the MRI exam by having them watch a video of a child undergoing a non-sedated MRI exam. Participants were also encouraged to explore the MRI scanner (e.g., walking around, practice being wheeled in and out of the scanner). All participants had a foam pad in their lap to wrap their hands around and a foam wedge to place their feet during the scan to minimize artifacts related to motion. An adult (family or researcher) was in the scanning room with the participant during the duration of the MRI scan. Participants watched a movie that they picked out and communicated with the researcher through headphones and a speaker microphone during the scanning process.

MRI Study

Preliminary studies have demonstrated the validity and reliability of using MRI protocols in young children with normal anatomy (Kollara et al., 2016; Perry, Kuehn, Sutton, & Fang, 2016; Tian, Yin, et al., 2010; Tian, Li, et al., 2010). No significant differences have been reported regarding the position (upright versus supine) in which MRI data are collected (Kollara & Perry, 2014; Perry, 2011). A Velcro-fastened elastic strap was positioned above the level of the glabella and fastened to the head coil to minimize motion artifacts during the scan.

Behavioral modifications were in place to ensure accurate data collection. Measures were obtained while the participant was at rest during nasal breathing.

Participants were imaged across three MRI sites using MRI sequences with comparable imaging parameters. MRI site one used a Siemens 3 Tesla Trio system (Erlangen, Germany) and a 3D turbo-spin-echo (TSE) sequence called Sampling Perfection with Application optimized Contrasts using different flip angle Evolution (SPACE) with repetition time of 2,500 ms, echo time of 268 ms, echo train length of 171, 0 mm spacing, and .8 mm slice thickness. MRI site two used a Siemens 3 Tesla Skyra system (Erlangen, Germany) and a similar 3D turbo-spin-echo (TSE) sequence called SPACE with repetition time of 2,500 ms, echo time of 266 ms, 0 mm spacing, and .8 mm slice thickness. MRI site three utilized a 3 Tesla General Electric scanner and used a T2-fluid attenuation inversion recovery (FLAIR; same specifications as the TSE), and coronal and oblique coronal Fast Spin Echo (FSE) sequences.

Image Analyses

All MRI images were transferred into Amira 6 Visualization Volume Modeling software (Visage Imaging GmbH, Berlin, Germany) after data collection. Amira has a native Digital Imaging and Communication in Medicine (DICOM) support program. The DICOM support system enables preservation of original geometry of the data.

Eight craniofacial measures were selected based on their proximity to the velopharyngeal port, relationship to velopharyngeal musculature, and comparative studies in the literature. The measures include: nasion-to-sella, sella-to-basion, basion-to-opisthion, nasion-to-basion, ANS-to-PNS, NSB angle, SBO angle, and face height. The measures are described in Table D1 and demonstrated in Figure D1.

Table D1.

Description of craniofacial and velopharyngeal measures

| Measure | Description |
|--------------------------|--|
| Nasion - sella | Linear distance from nasion to sella |
| Sella - basion | Linear distance from sella to basion |
| Basion - opisthion | Linear distance from basion to opisthion |
| Nasion - basion | Linear distance from nasion to basion |
| ANS - PNS | Distance from the anterior nasal spine to the posterior nasal spine |
| NSB angle | Inner angle formed between two intersecting lines, one connecting the nasion to sella and the other connecting basion to sella |
| SBO angle | Inner angle formed between two intersecting lines, one connecting sella to basion and the other connecting opisthion to basion |
| Face height | Distance from nasion to menton |
| Velar length | Length of the velum from the posterior nasal spine to the tip of the uvula |
| Effective velar length | Distance from the PNS to the middle of the levator sling where it inserts into the body of the velum |
| Velar thickness | Distance from the velar knee to the velar dimple |
| Pharyngeal depth | Distance from the posterior nasal spine (PNS) to the posterior pharyngeal wall (PPW) along the palatal plane |
| Velar knee-PPW | Distance from the velar knee to the posterior pharyngeal wall |
| PP to C1 | Distance from the anterior tubercle of the first cervical vertebrae to the palatal plane reference line, measured parallel to the pharyngeal wall |
| VP depth at C1 | Depth of the velopharyngeal port measured at the level of the first cervical vertebrae |
| Adenoid thickness | Determined by measuring the nasopharyngeal margin of the adenoid tissue to the intersection of two reference lines – horizontal line through palatal plane and vertical line along the posterior pharyngeal wall |
| Sagittal angle | Angle created by drawing a line along the anterior boundaries of vertebrae three and four and a line coursing along the sagittal plane of the levator muscle. This angle represents the steepness of the levator muscle as it converges toward the velum from the muscle origin. |
| VP ratio | Velar length/Pharyngeal depth |
| SPC thickness | The average of the thickness of the superior pharyngeal constrictor muscle measured at three points – the level of the first cervical vertebra, the midpoint of the second cervical vertebra, and the inferior aspect of the second cervical vertebra |
| Levator length | Length of the levator muscle from its origin at the base of the skull to its insertion at the velum |
| Levator thickness | The thickness of the levator muscle measured on the lateral one-fourth point, midpoint, and medial one-fourth point |
| Origin to origin | Distance between the right and left points of origin of the levator muscle |
| Velar insertion distance | Distance between where the levator muscle inserts into the body of the velum on the right and left sides |
| Levator angles of origin | Angle created between a reference line connecting the two origins of the levator muscle and the line drawn to measure the levator muscle length. |
| Nasovelar surface | Thickness of the area between the nasal surface of the velum and the intravelar fibers |

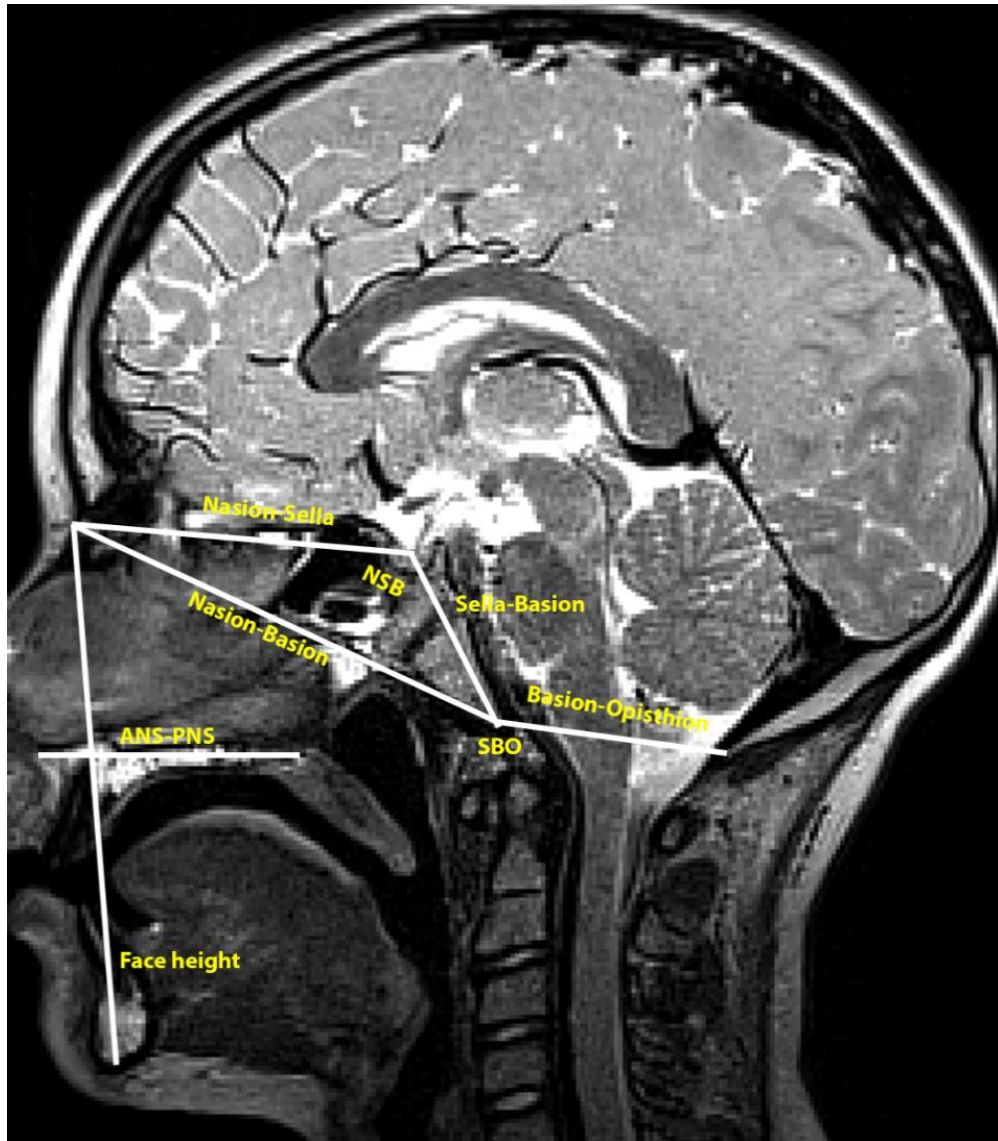


Figure D1. Craniofacial measures

Seventeen velopharyngeal measures were obtained from the MRI data in the midsagittal and oblique coronal image planes. The measures are described in Table D1 and demonstrated in Figure D2. The measures were selected based on comparable studies in the literature. The measures obtained in the midsagittal image plane include: velar length, effective velar length, velar thickness, pharyngeal depth, velar knee-posterior pharyngeal wall (PPW), palatal plane

(PP) to C1 (first cervical vertebrae), velopharyngeal depth at C1, adenoid thickness, sagittal angle, velopharyngeal ratio (ratio of velar length to pharyngeal depth), and superior pharyngeal constrictor (SPC) thickness.

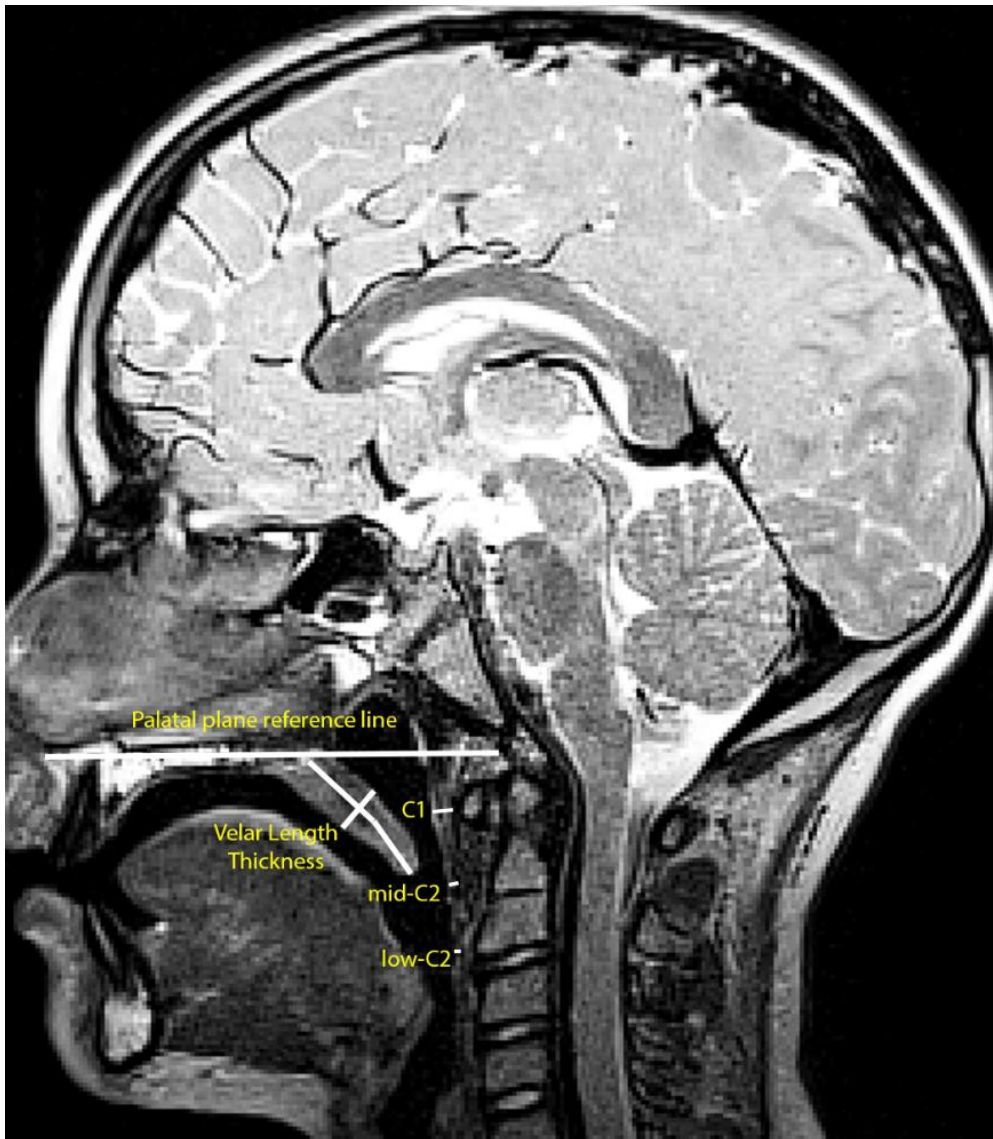


Figure D2. Velopharyngeal measures demonstrated in the midsagittal image plane

The measures obtained in the oblique-coronal image plane include: levator length, levator thickness, origin-to-origin, velar insertion distance, levator angle of origin, and nasovelar surface. The oblique coronal image plane is visualized by resampling the midsagittal image. It displays the levator muscle in it's entirely from its origin at the cranial base to its insertion into the body of the velum. These measures are demonstrated in Figure D3.

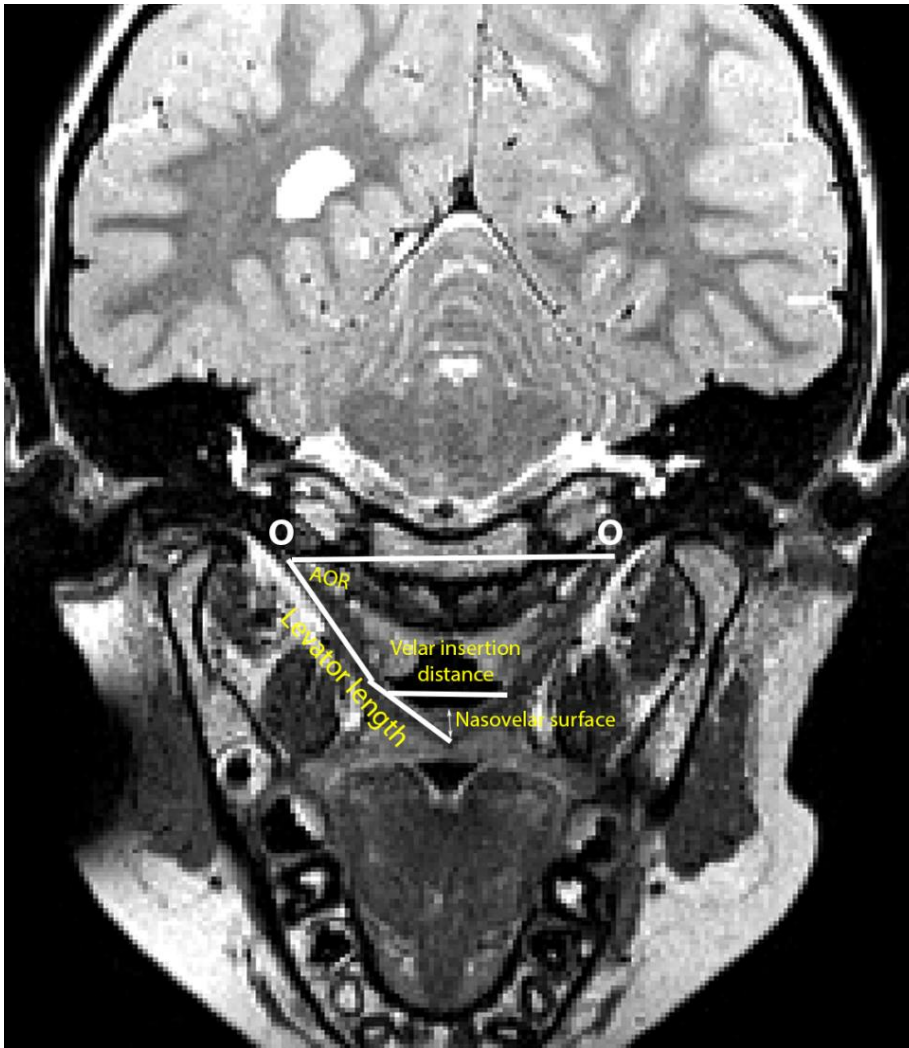


Figure D3. Levator and velopharyngeal measures demonstrated in the oblique coronal image plane

Statistical Analyses

All statistical analyses were conducted in IBM SPSS Version 22 (IBM Corporation, Armonk, NY). For aim one, analysis of covariance (ANCOVA) was used to compare differences between the experimental (22q11.2 DS) and control (children with normal anatomy) groups for the variables of interest. Both age and weight were included as covariates for all of the analyses to control for the effects of dissimilar ages and body size. The assumptions of normality were adequately met for all measures as assessed by formal tests (Shapiro-Wilks's test) and graphical representation (Q-Q plots). Homogeneity of variance was reasonably met as assessed by Levene's test of homogeneity of variance. A p -value of $< .05$ was considered to be statistically significant. For aim two, given that the cranium houses the velopharyngeal port and serves as the point of attachment for the levator muscle, multiple linear regression models were used to assess whether craniometric measures could predict velar and levator muscle configurations. The velopharyngeal measures were the dependent variables (DV) and the craniofacial measures were the independent variables (IV).

Inter-rater reliability and intra-rater measures were established using the Pearson product moment correlation ($\alpha = .05$). Both primary and secondary raters had at least five years of experience in 3D MRI data processing. Reliability measurements were performed by measuring all variables from 12 randomly selected participants three months after the first measurements were obtained. Intra-rater and inter-rater reliability ranged from $r = .70$ to $r = .94$. Paired t -tests were conducted to determine inter-rater and intra-rater differences. There were no statistically significant differences ($p > .05$) between the first and second measures by the primary and secondary raters.

RESULTS

Magnetic resonance images were successfully obtained on all 30 participants. Group means for craniofacial measures are reported in Table D2 and group means for velopharyngeal measures are reported in Tables D3.

Table D2.

Means and standard deviations for craniofacial variables for the 22q group and normative control group.

Note. Values are noted in millimeters

| Variables | 22q11.2 DS group | Control group |
|--------------------|-------------------------|----------------------|
| Nasion - sella | 58.1(5.2) | 60.0 (3.4) |
| Sella - basion | 32.5 (4.3) | 36.5 (2.4) |
| Basion - opisthion | 37.4 (4.1) | 37.1 (3.5) |
| Nasion - basion | 83.6 (7.1) | 86.9 (5.2) |
| ANS - PNS | 47.4 (4.5) | 48.5 (4.7) |
| NSB angle | 134.0 (8.1) | 126.9 (5.3) |
| SBO angle | 218.7 (11.6) | 223.7 (8.0) |
| Face height | 95.0 (10.9) | 90.3 (6.1) |

Table D3.

Means and standard deviations for velopharyngeal structures and muscles for the 22q group and normative control group

Note. Values are noted in millimeters, except for the angle measure (in degrees). VP = velopharyngeal

| Variables | 22q11.2 DS group | Control group |
|--------------------------|-------------------------|----------------------|
| Velar length | 25.4 (4.3) | 26.4 (3.0) |
| Effective velar length | 10.8 (1.6) | 10.9 (2.0) |
| Velar thickness | 6.5 (1.0) | 8.0 (1.2) |
| Pharyngeal depth | 21.9 (4.5) | 18.2 (3.94) |
| Velar knee-PPW | 10.1 (3.57) | 9.6 (2.40) |
| PP to C1 | -3.1 (5.94) | -5.2 (3.98) |
| VP depth at C1 | 10.3 (3.62) | 9.2 (2.60) |
| Adenoid thickness | 3.6 (2.6) | 3.9 (2.2) |
| Sagittal angle | 57.2 (11.49) | 55.8 (8.81) |
| VP ratio | 1.19 (.24) | 1.50 (.31) |
| SPC thickness | 2.2 (.32) | 2.2 (.31) |
| Levator length | 32.7 (3.26) | 35.6 (4.3) |
| Levator thickness | 1.5 (.40) | 1.8 (.38) |
| Origin to origin | 40.9 (3.6) | 47.6 (3.8) |
| Velar insertion distance | 21.6 (3.49) | 21.2 (1.00) |
| Levator angle of origin | 66.4 (5.6) | 58.9 (4.3) |
| Nasovelar surface | 3.3 (1.44) | 3.7 (1.48) |

AIM 1: Craniofacial and velopharyngeal variations

Nasion-to-sella and nasion-to-basion were found to be significantly different in children with 22q11.2 DS compared to the non-syndromic cohort (Table D4). The distance from nasion-to-sella (58.1 mm in 22q11.2 DS versus 60.0 mm in controls, $p = .037$) and nasion-to-basion (83.6 mm in 22q11.2 DS versus 86.9 mm in controls, $p = .012$) was significantly shorter in the 22q11.2 DS group compared to the control group. The sella-to-basion measure was highly significantly shorter (32.5 mm in 22q11.2 DS versus 36.5 mm in controls, $p < .0005$) in children

with 22q11.2 DS compared to the control group. The NSB (anterior cranial base) angle was found to significantly more obtuse (134 degrees in 22q11.2 DS versus 126.9 degrees in controls, $p = .011$) in the 22q11.2 DS group compared to the control group (Table 4).

Table D4.

*Results from the ANCOVA models, analyzing the differences in craniofacial structures among the 22q group and normative control group. Covariates = age, weight. The eta-squared value (in parentheses) demonstrates the effect size for the data. Significance level determined at $*p < .05$. Statistically significant results shown in bold font.*

| Variable | p-value (with both covariates included) |
|--------------------|--|
| Nasion - sella | $F_{1,26} = 4.815$ $p = \mathbf{.037 (.156)}$ |
| Sella - basion | $F_{1,26} = 22.144$ $p < \mathbf{.0005 (.460)}$ |
| Basion - opisthion | $F_{1,26} = 0.000$ $p = .991 (.000)$ |
| Nasion - basion | $F_{1,26} = 7.246$ $p = \mathbf{.012 (.218)}$ |
| ANS - PNS | $F_{1,26} = 2.215$ $p = .149 (.079)$ |
| NSB angle | $F_{1,26} = 7.488$ $p = \mathbf{.011 (.224)}$ |
| SBO angle | $F_{1,26} = 1.727$ $p = .200 (.062)$ |
| Face height | $F_{1,26} = 2.038$ $p = .165 (.073)$ |

Velar thickness was highly significant demonstrating differences in children with 22q11.2 DS compared to the control group (6.5 mm in 22q11.2 DS versus 8.0 mm in controls, $p < .0005$) (Table D5). Children with 22q11.2 DS demonstrated a velum that was significantly thinner (23% thinner) compared to children with normal velopharyngeal anatomy. Statistically significant differences were also noted for pharyngeal depth (21.9 mm in 22q11.2 DS versus 18.2 mm in controls, $p = .007$) and velopharyngeal ratio (1.1 in 22q11.2 DS versus 1.5 in controls, $p = .004$). The 22q11.2 DS group had a significantly larger (20% larger) pharyngeal depth compared to the control group.

Table D5.

Results from the ANCOVA models, analyzing the differences in velopharyngeal structures and muscles among the 22q group and normative control group. Covariates include both age and weight. The *et-squared* value (in parentheses) demonstrates the effect size for the data.

Significance level determined at $*p < .05$. Statistically significant results shown in bold font.

| Variable | p-value (with both covariates included) |
|--------------------------|--|
| Velar length | $F_{1,26} = 1.22$ $p = .278 (.045)$ |
| Effective velar length | $F_{1,26} = 0.067$ $p = .797 (.003)$ |
| Velar thickness | $F_{1,26} = 17.431$ $p < .0005 (.401)$ |
| Pharyngeal depth | $F_{1,26} = 8.490$ $p = .007 (.246)$ |
| Velar knee-PPW | $F_{1,26} = .365$ $p = .551 (.014)$ |
| PP to C1 | $F_{1,26} = 0.793$ $p = .381 (.030)$ |
| VP depth at C1 | $F_{1,26} = 1.063$ $p = .312 (.039)$ |
| Adenoid thickness | $F_{1,26} = .034$ $p = .855 (.001)$ |
| Sagittal angle | $F_{1,26} = .222$ $p = .641 (.008)$ |
| VP ratio | $F_{1,26} = 10.035$ $p = .004 (.278)$ |
| SPC thickness | $F_{1,26} = 0.012$ $p = .915 (.000)$ |
| Levator length | $F_{1,26} = 4.839$ $p = .037 (.157)$ |
| Levator thickness | $F_{1,26} = 5.681$ $p = .025 (.179)$ |
| Origin to origin | $F_{1,26} = 25.144$ $p < .0005 (.492)$ |
| Velar insertion distance | $F_{1,26} = 0.802$ $p = .723 (.005)$ |
| Levator angle of origin | $F_{1,26} = 14.492$ $p = .001 (.358)$ |
| Nasovelar surface | $F_{1,26} = 1.435$ $p = .242 (.052)$ |

The length and thickness of the levator muscle was found to be significantly different in children with 22q11.2 DS compared to the control group (Table D5). The levator length was significantly shorter (32.7 mm in 22q11.2 DS versus 35.6 mm in controls, $p = .037$; 8% shorter) in children with 22q11.2 DS compared to children with normal velopharyngeal anatomy. The levator muscle was significantly thinner in children with 22q11.2 DS (1.5 mm in 22q11.2 DS versus 1.8 mm in controls, $p = .025$; 20% thinner) compared to the control group. The levator origin-to-origin distance was found to be significantly different for the 22q11.2 DS group compared to the control group (40.9 mm in 22q11.2 DS versus 47.6 mm in controls, $p < .0005$). The origin-to-origin distance was 16% smaller among the 22q11.2 DS group compared to the control group. The levator angles of origin were also found to be different between the groups. The 22q11.2 DS group demonstrated a larger (66.4 degrees in 22q11.2 DS versus 58.9 degrees in controls, $p = .001$; 12% larger) levator angle in comparison to the control group.

Qualitatively, a distinctive trend for structural variations across the four resonance categories was not evident for the 22q11.2 DS group. The anterior cranial base angle was abnormally larger (platybasia) or smaller (kyphosis) in the three participants with moderate to severe hypernasality. Velar thickness was also reduced for these three participants compared to the control group. There were two participants in the 22q11.2 DS group that had C1 placement above the level of the palatal plane. There was no apparent pattern in velopharyngeal muscle measures across the 22q11.2 DS group. For example, there were participants in both mild and severe resonance categories that exhibited a few similar features, but a clear pattern of velopharyngeal muscle dysmorphology across the three progressive abnormal resonance groups (mild, moderate, severe) was not evident.

AIM II: Prediction models

Multiple linear regression models were utilized to predict whether craniofacial structures could predict velopharyngeal and levator muscle configurations. Separate regression analyses were conducted for the 22q11.2 DS group and the control group. Age and weight were included as covariates. A backwards selection was used to obtain reduced regression models with fewer predictors as some of the craniofacial measures were strongly correlated.

For the control group, out of the 18 velopharyngeal measures, 12 measures demonstrated significant prediction models with craniofacial markers. The measures with significant prediction models for the control group are demonstrated in Table D6. Superior pharyngeal constrictor thickness had a strong prediction model (R-square= 97.5%) for this group with predictors such as weight, nasion-to-sella, sella-to-basion, ANS-to-PNS, and SBO angle. The prediction model for levator thickness could only account for 36.6% of the variability for this muscle measure, indicating a weak model. For the 22q11.2 DS group, out of the 18 velopharyngeal measures, 12 measures demonstrated significant prediction models with craniofacial markers. The measures with significant prediction models for the 22q11.2 DS group are demonstrated in Table D7. Pharyngeal depth had a strong prediction model (R-square= 87.9%) for this group with predictors such as NSB angle, SBO angle, and face height. The prediction model for levator length could only account for 33.8% of the variability for this muscle measure, indicating a weak model.

Table D6.

Results from the multiple linear regression analysis for the control group

| Velopharyngeal measure (DV) | R-square | ANOVA (p-values) | Craniofacial predictor (IV) | p-value for IV |
|------------------------------------|-----------------|-------------------------|------------------------------------|-----------------------|
| Velar length | 71.4 | .025 | ANS-PNS | .008 |
| | | | NSB angle | .012 |
| | | | Face height | .035 |
| Velar thickness | 79.4 | .006 | B-O | .014 |
| | | | NSB angle | .028 |
| | | | Face height | .039 |
| Pharyngeal depth | 87.6 | .000 | N-S | .025 |
| | | | ANS-PNS | .002 |
| | | | Face height | .049 |
| PP-C1 | 97.1 | .003 | N-S | .03 |
| | | | S-B | .022 |
| | | | N-B | .039 |
| | | | ANS-PNS | .032 |
| | | | SBO angle | .024 |
| | | | Face height | .011 |
| VP depth at C1 | 93 | .000 | N-S | .001 |
| | | | B-O | .013 |
| | | | NSB angle | .011 |
| | | | SBO angle | .001 |
| | | | Face height | .004 |
| VP ratio | 91.7 | .000 | NSB angle | .003 |
| | | | Face height | .000 |
| SPC thickness | 97.5 | .000 | N-S | .000 |
| | | | S-B | .009 |
| | | | ANS-PNS | .002 |
| | | | SBO angle | .000 |
| Levator length | 79.8 | .002 | B-O | .005 |
| | | | ANS-PNS | .005 |
| | | | NSB angle | .009 |
| | | | SBO angle | .007 |
| Levator thickness | 36.6 | .017 | Face height | .017 |
| Origin-origin | 68.5 | .014 | B-O | .013 |
| | | | ANS-PNS | .046 |
| | | | NSB | .012 |
| | | | SBO | .033 |
| Velar insertion distance | 41.1 | .010 | N-B | .010 |
| Nasovelar surface | 93.2 | .000 | S-B | .000 |
| | | | B-O | .010 |
| | | | SBO | .000 |

Table D7.

Results from the multiple linear regression analysis for the 22q11.2 DS group

| Velopharyngeal measure (DV) | R-square | ANOVA (p-values) | Craniofacial predictor (IV) | p-value for IV |
|--|-----------------|-----------------------------|--|---------------------------|
| Velar length | 70.2 | .003 | Sella-basion | .006 |
| | | | Basion-opisthion | .005 |
| Effective velar length | 79.8 | .018 | S-B | .028 |
| | | | N-B | .027 |
| | | | ANS-PNS | .003 |
| | | | NSB angle | .038 |
| Velar thickness | 85.2 | .006 | N-S | .029 |
| | | | S-B | .014 |
| | | | N-B | .022 |
| | | | NSB angle | .006 |
| Pharyngeal depth | 87.9 | .001 | NSB angle | .001 |
| | | | SBO angle | .008 |
| | | | Face height | .000 |
| PP-C1 | 71.3 | .003 | N-S | .002 |
| Adenoid thickness | 62.2 | .003 | N-S | .019 |
| VP ratio | 45.2 | .006 | NSB angle | .006 |
| Levator length | 33.8 | .023 | S-B | .023 |
| Origin-origin | 64.4 | .024 | S-B | .005 |
| | | | B-O | .040 |
| | | | NSB angle | .015 |
| Velar insertion distance | 42.8 | .035 | N-S | .021 |
| | | | N-B | .011 |
| Levator angle of origin | 47.1 | .022 | B-O | .036 |
| | | | N-B | .013 |
| Nasovelar surface | 83.3 | .025 | N-S | .020 |
| | | | S-B | .045 |
| | | | B-O | .034 |
| | | | N-B | .024 |
| | | | NSB angle | .013 |
| | | | SBO angle | .047 |

DISCUSSION

The first aim of this study was to examine variations in craniofacial and velopharyngeal structures and muscles among children with 22q11.2 DS in comparison to a non-syndromic cohort with normal velopharyngeal anatomy. MRI data were successfully obtained for both groups of participants. No studies to date have utilized MRI without sedation in young children with 22q11.2 DS to examine velopharyngeal muscle morphology and associated structures. MRI offers excellent delineation between hard and soft tissue structures and is the only imaging modality that allows visualization of the internal velopharyngeal musculature *in vivo*. Commonly used clinical methods for assessing the velopharyngeal mechanism include nasopharyngoscopy and multiview videofluoroscopy. These imaging methods have limitations such as invasiveness, distorted depth cues, and the use of ionizing radiation. Additionally, the imaging viewpoints are limited for these two modalities.

MRI is noninvasive, easily repeatable, and enables multiple views of underlying musculature (Perry et al., 2016). However, commonly in pediatric MRI, sedation and the use of a laryngeal airway mask often distorts the positioning of the velum and oropharyngeal structures at rest. Specific aversions, such as those related to the natural environment (e.g., loud noises and claustrophobia) are also increasingly more common in children with 22q11.2 DS compared to children without such diagnosed syndromes (Antshel et al., 2006). As such, a non-sedated imaging protocol as detailed in this study could prove advantageous in advancing the knowledge base related to the anatomic structural and morphologic differences among children with 22q11.2 DS.

Craniofacial Observations

Findings from the present study demonstrate that the length from nasion-to-sella, sella-to-basion, and nasion-to-basion was significantly shorter in children with 22q11.2 DS compared to non-syndromic children. Wang et al. (2009) investigated craniofacial phenotype variations in children with 22q11.2 DS and children with cleft palate using computed tomography. The results were consistent with findings from the present study where the children with 22q11.2 DS demonstrated shorter nasion-to-sella and sella-to-basion lengths. Dalben Gda et al. (2010) also reported individuals with 22q11.2 DS to have a shorter sella-to-basion length. In a cephalometric study on 41 children with 22q11.2 DS (Heliovaara & Hurmerinta, 2006), it was found that children with 22q11.2 DS had a shorter posterior cranial base length (sella-to-basion); however, the anterior cranial base length (nasion-to-sella) was found to be longer for this group compared to age and sex matched controls. Consistent with previous studies (Dalben Gda et al., 2010), the nasion-to-basion distance was found to be significantly shorter in children with 22q11.2 DS compared to the control group. The shorter lengths for the nasion-to-sella, sella-to-basion, and nasion-to-basion all lead to an anterior compartment that may be smaller in the 22q11.2 DS population. Future studies should investigate the effects that these craniofacial variations could have on the development on the velopharyngeal port and its dimensions.

Conflicting findings have been reported regarding hard palate length in individuals with 22q11.2 DS. Studies have indicated individuals with 22q11.2 DS to have a decreased hard palate length (Ruotolo et al., 2006; Wang et al., 2009) as well as an increased hard palate length (Heliovaara & Hurmerinta, 2006). Different racial groups were assessed across these studies and as such the discrepancy in findings may be due to the effects of race on bony craniofacial structures. Dalben Gda et al. (2010) assessed craniofacial morphology in 18 individuals with

22q11.2 DS and compared findings to age- and sex-matched controls with no morphofunctional alterations. Our findings are consistent with those reported in this study (Dalben Gda et al., 2010), with individuals with 22q11.2 DS not demonstrating a statically significant difference in the length of the hard palate.

Skull base anomalies in 22q11.2 DS may affect the relative positions of the facial bones to one another. The midface and resulting facial profile are recessed in relation to the forehead and as such appear flat (Shprintzen & Golding-Kushner, 2008). Vertical maxillary excess is referred to as a longer than normal lower third of the face. This is a commonly reported characteristic in individuals with 22q11.2 DS (Shprintzen & Golding-Kushner, 2008). Compared to non-syndromic control participants, individuals with 22q11.2 DS have been reported to have increased overall face length (Heliovaara & Hurmerinta, 2006), decreased overall face length (Wang et al., 2009), increased superior facial height (Wang et al., 2009), and increased anterior facial height (Arvystas & Shprintzen, 1984). Findings in the present study revealed children with 22q11.2 DS to have a longer, but not significantly different facial height compared to children with normal velopharyngeal anatomy.

The human cranium has a flexion along the skull base that differentiates its anterior and posterior aspects. The anterior portion supports the facial bones and the posterior portion contains the posterior part of the brain and the spinal cord. The angulation of the skull base is measured as the angle from the nasion to the sella turcica to the basion. This angle is typically 128 degrees with a standard deviation of approximately 4 degrees (Shprintzen & Golding-Kushner, 2008). Arvystas and Shprintzen (1984) hypothesized that platybasia results in deepening of the velopharyngeal port which may result in velopharyngeal dysfunction. Discordant findings have been reported regarding the presence of platybasia in individuals with

22q11.2 DS. Studies have reported children with 22q11.2 DS to have a confirmed diagnosis of platybasia utilizing diagnostic methods such as lateral cephalometry and MRI (Arvystas & Shprintzen, 1984; Heliovaara & Hurmerinta, 2006; Ruotolo et al., 2006). Other studies have indicated a trend toward platybasia, but not statistically significant, utilizing diagnostic methods such as lateral cephalometry and computed tomography (Dalben Gda et al., 2010; Glander & Cisneros, 1992; Wang et al., 2009). Studies have also reported the non-existence of platybasia in these individuals (Veerapandiyan et al., 2011). Consistent with reports by (Arvystas & Shprintzen, 1984; Heliovaara & Hurmerinta, 2006; Ruotolo et al., 2006), findings in the present study indicated that children with 22q11.2 DS demonstrate a significantly larger anterior cranial base angle, resulting in platybasia. Spruijt, Kon, and Mink van der Molen et al. (2014) assessed the relationship between cranial base angles and speech resonance in 24 individuals with 22q11.2 DS using retrospective chart reviews. It was determined that groups of individuals with hypernasal speech have a trend toward more obtuse cranial base angles. However, no significant relationship was determined between resonance ratings and cranial base angles. As such, the clinical significance of platybasia is still uncertain.

Velopharyngeal Observations

Findings from the present study demonstrate that velar thickness, pharyngeal depth, and velopharyngeal ratio are significantly different in children with 22q11.2 DS compared to non-syndromic children with normal velopharyngeal anatomy. A lateral cephalometry investigation on 26 individuals demonstrated individuals with 22q11.2 DS to have decreased velar length and an abnormal anterior location of the velar dimple (Veerapandiyan et al., 2011). Conversely, an MRI study on five individuals in 22q11.2 DS found no significant variations in velar length and thickness among this clinical population in comparison to 123 individuals without 22q11.2 DS

(Ruotolo et al., 2006). Findings in the present study indicate children with 22q11.2 DS have a significantly thinner velum compared to the control group, using age and weight as covariates to remove the effects of growth and body size. It is unknown if a thin velum could cause increased transpalatal transmission of sound and lead to an increased perception of hypernasality in individuals with 22q11.2 DS. No significant difference was noted for velar length in the present study. In individuals with normal velopharyngeal anatomy, velar bulging during a speech task is due to the presence of the musculus uvulae (Shprintzen & Golding-Kushner, 2008). When the musculus uvula contracts during speech activity, it creates a velar bulge at its muscle belly because it is not firmly attached at its distal end. The musculus uvulae can be observed *in vivo* using MRI (Perry, Kuehn, Sutton, Gamage, & Fang, 2016). In the current study, the nasovelar surface was measured as the thickness of the area between the nasal surface of the velum and the intravelar fibers. It was anticipated that this measure would be thinner and sparse in children with 22q11.2 DS, which may have an effect on the velum to PPW contact. However, no significant difference was noted. It is unknown if the reduced velar thickness is due the absence of the musculus uvulae for the 22q11.2 DS population. In the present study, the presence of the musculus uvulae fibers were inconsistent across participants. Although image resolution was optimal (0.8 mm), it is possible that the fibers were present and hypoplastic and not visible using the current imaging parameters. Diffusion tensor imaging (DTI) may be beneficial to examine the muscle fibers in the velar midline.

Velopharyngeal closure is dependent on the morphology of the velopharyngeal port in addition to the neuromuscular function of the velum and associated musculature. Findings from the present study indicate that children with 22q11.2 DS have a significantly larger pharyngeal depth compared to children with normal velopharyngeal anatomy. These findings are consistent

with cephalometric (Heliovaara & Hurmerinta, 2006; Veerapandiyan et al., 2011) and MRI (Ruotolo et al., 2006) studies that have reported individuals with 22q11.2 DS to have a wide nasopharyngeal area, increased (but not statistically significant) osseous pharyngeal depth (distance between posterior nasal spine and anterior body of C1), increased osseous pharyngeal depth to velar length ratio, more obtuse angle of superior-anterior quadrant, and increased velopharyngeal width (distance between lateral pharyngeal walls). Ruotolo et al. (2006) also found the airway to be significantly more obtuse and voluminous in the 22q11.2 DS group. Nasoendoscopic investigations in individuals with 22q11.2 DS revealed these individuals to have reduced adenoid tissue, tonsillar hypertrophy, and reduced movement of lateral pharyngeal walls (Ysunza et al., 2011). These findings are inconsistent with findings on 18 Brazilian participants with 22q11.2 DS compared to age- and sex-matched control groups where individuals with 22q11.2 DS were found to have no significant differences in depth of bony pharynx (distance between posterior nasal spine and basion), nasopharynx, and oropharynx (Dalben Gda et al., 2010). Other velopharyngeal portal measures such the velar knee to PPW distance and the velopharyngeal depth at C1 were found to not significantly differ between the two groups for this study. The potential role of the adenoid pad in preserving velopharyngeal closure and normal resonance even in children with 22q11.2 DS with abnormal craniofacial features warrants further investigation. Additional data analyses are in progress to determine the relationship between volumetric and linear correlates of the velopharynx and its effects on velopharyngeal port mechanics in the 22q11.2 DS population.

The C1 is an important, palpable intraoperative landmark often used to determine placement during surgical treatment of velopharyngeal dysfunction. Studies have reported cervical abnormalities in the 22q11.2 DS population compared to non-syndromic controls

groups. It has been reported that individuals with 22q11.2 DS demonstrate a thin/small C1 compared to normative control groups (Heliovaara & Hurmerinta, 2006). The location of the palatal plane on the PPW is the point of contact of the velum on the PPW for velopharyngeal closure for oral sound production. It was hypothesized that due to the reported presence of C1 abnormalities in the 22q11.2 DS population, the C1 to palatal plane distance would differ between the 22q11.2 DS group and the control group. However, statistically significant differences were not noted for this measure. This is the first study to report on the palatal plane to C1 distance in children with 22q11.2 DS. Given the hypoplasticity of the velopharynx in individuals with 22q11.2 DS, future studies should utilize imaging data during speech tasks to determine if the level of closure of the velum against the PPW is at a different level for this clinical population compared to the norm.

Velopharyngeal Muscle Observations

The thickness and histologic and histochemical properties of the superior pharyngeal constrictor have been analyzed in individuals with 22q11.2 DS using MRI and biopsy specimens. Zim et al. (2003) noted that the superior pharyngeal constrictor muscle thickness was found to be significantly less in 26 individuals with 22q11.2 DS (2.03 mm) compared to age- and sex-matched controls without 22q11.2 DS (2.85 mm). Findings in the present study indicated comparable values (22q 11.2 DS group = 2.2 mm, control group = 2.2 mm); however, no significant differences were found between the two groups. Zim et al. (2003) study included a wide age range of participants (3-29 years) which may not account for the effects of growth on the superior pharyngeal constrictor muscle. It may be that pharyngeal hypotonia is more evident at a later time in the lifespan, after going through pubertal growth. Additionally, the measure noted as the point of the inferior aspect of the second cervical vertebrae was instead the midpoint

of the second cervical vertebrae. Future studies should investigate the etiology and extent of pharyngeal hypotonia in the 22q11.2 DS population. A thin and hypoplastic superior pharyngeal constrictor muscle could lead to an increased velopharyngeal portal depth. The overall diameter of the port would be larger and the formation of a strong and complete seal of the velum against the pharyngeal wall which is necessary for the normal speech resonance would be harder to achieve. An inefficient velopharyngeal closure mechanism will enable resonating sound to escape into the nasopharynx.

In an MRI investigation of the levator muscle in children with 22q11.2 DS, the mean levator muscle thickness was found to be significantly thinner in 22q11.2 DS individuals compared to the non-syndromic submucous cleft palate individuals (Park et al., 2015). Findings in the current study demonstrate the levator muscle to be significantly thinner in children with 22q11.2 DS compared to non-syndromic children with normal velopharyngeal anatomy. This finding is consistent with unpublished conference reports of the levator sling being thin and hypoplastic in individuals with 22q11.2 DS (Kuehn, 2003; Punjabi et al., 2002). The present study is the first study to report that the length of the levator muscle is significantly shorter in the 22q11.2 DS population compared to children with normal velopharyngeal anatomy. There is not enough data to determine if levator dysmorphology is a direct cause of velopharyngeal dysfunction for these participants. Future studies should assess the relationship between velopharyngeal muscle dysmorphology and its effects on perceptual speech characteristics.

The levator origin-to-origin distance was found to be significantly less in children with 22q11.2 DS compared to those with normal velopharyngeal anatomy. This may be due to the long and narrow facial profile that is a common characteristic for individuals with 22q11.2 DS. The angle at which the levator muscle descends from the base of the skull was significantly

larger in the 22q11.2 DS group compared to those with normal velopharyngeal anatomy. This could be due to the shorter distance between levator muscle origins in the 22q11.2 DS population. Greater angle of origins would indicate a more lateral insertion into the velar body. Given that the velopharyngeal muscles that are responsible for velopharyngeal closure have its origins in the cranial base and posterior pharynx, abnormalities in these bony craniofacial structures may have a subsequent effect on muscle form and function (Kollara et al., 2016; Nachmani et al., 2013). The functional alterations that these anatomic variations could have on overall levator muscle configuration and movement remain unknown. Modeling studies could help demonstrate how shorter a muscle origin distance and an increased angle of descent could alter levator muscle contraction and configuration. The interaction of craniometric variables relative to the velopharyngeal mechanism warrants investigation for this clinically complex population. A limitation of the present study is the focus on the levator muscle, however data pertinent to the lateral pharyngeal wall and posterior pharyngeal wall may also prove to have a significant relationship to velopharyngeal dysfunction findings in this population. Qualitatively, cranial and muscle dysmorphology features across and within different resonance categories was found to be variable among the 22q11.2 DS group. In the present study, it is of interest to note that many significant craniofacial and velopharyngeal variations were evident in a group that predominantly consisted of individuals with minimal to no symptoms of velopharyngeal dysfunction. Future investigations should quantitatively assess logistical categories of perceptual severity that may be correlated to muscle dysmorphology features.

Relationship between Craniometric and Velopharyngeal Variables

The second aim of this study was to determine whether craniometric measures could predict velopharyngeal structure and muscle configurations in children with 22q11.2 DS and in

children with normal velopharyngeal anatomy. Studies have hypothesized that abnormalities in bony craniofacial structures may have a subsequent effect on muscle form and function, which may influence velopharyngeal dysfunction (Kollara et al., 2016; Nachmani et al., 2013; Perry et al., 2016). However, previous studies did not assess the predictive ability that one could have on the other in children with 22q11.2 DS, thus limiting the comparison of the present results with those of other authors. In the present study, the two velopharyngeal measures that did not have significant craniofacial prediction models across the 22q11.2 Ds group and control group are velar knee-to -PPW and sagittal angle. Twelve prediction models were significant for both 22q11.2 DS and control groups, with a different set of predictors for each of them, which made comparison across groups difficult. For the control group, the most common craniofacial predictor was face height, as it was present in six prediction models. The least common predictor was nasion-to-basion. For the 22q11.2 DS group, the most common predictors were NSB angle and sella-to-basion, as they were present in six prediction models. The least common craniofacial predictors were hard palate length and facial height. Computational modeling studies could incorporate prediction models and assess how craniofacial and velopharyngeal anatomical parameters affect one another and how they could conjointly affect the biomechanics of the velopharyngeal port.

Dysmorphology in velopharyngeal structures has been shown to have significant negative implications on speech among individuals with 22q11.2 DS (Baylis, Munson, & Moller, 2008; Kirschner, 2005; Ysunza et al., 2011). It has been noted that individuals with 22q11.2 DS display severe hypernasality in the presence of a small velopharyngeal gap, demonstrating an incompetent velopharyngeal system cannot exclusively explain the cause of hypernasal speech (Baylis, Watson, & Moller, 2009). A limitation of the present study is the lack of velar and

levator muscle activity data during speech tasks. Future studies should aim to investigate velopharyngeal structural and functional variations and its relationship to perceptual speech correlates in children with 22q11.2 DS.

The goal of speech surgery is to eliminate velopharyngeal insufficiency and hypernasality and to create a normal valving system for speech and resonance. Surgery for velopharyngeal dysfunction in the 22q11.2 DS population may be challenging due to the complex underlying morphological variations in this population. Individuals with 22q11.2 DS demonstrate a significantly higher need for secondary surgery for velopharyngeal dysfunction (Basta et al., 2014; D-Antonio et al., 2001; Losken et al., 2006; Witt et al., 1999) compared to non-22q11.2 DS cohorts. These individuals also demonstrate poorer speech outcomes (Milczuk, Smith, & Brockman, 2007) compared to those without 22q11.2 DS. Results from the present study highlight the many velopharyngeal and levator variations that exist for individuals with 22q11.2 DS. There is a need for continued research regarding the morphological variations and functional dynamics that characterize the velopharynx and associated structures for this population. Computational modeling studies using patient specific data of the linear and volumetric features of the velopharynx could ultimately help tailor surgical needs in children with 22q11.2 DS.

FUTURE DIRECTIONS

The results of this study demonstrate the successful utilization of MRI in obtaining 3D imaging data of craniofacial and velopharyngeal structures in children as young as four years with 22q11.2 DS, without the use of sedation. This study offers the foundation for multiple opportunities to further research focused to better understand variations between individuals with 22q11.2 DS, in comparison to cleft palate groups, other syndromic populations, and those with normal velopharyngeal anatomy. Further research is needed to investigate the effects of surgery

on the velopharyngeal port in individuals with 22q11.2 DS. More research should be focused on the functional variations of the velopharyngeal musculature and portal during speech activity in individuals with 22q11.2 DS. Computational modeling studies that can help demonstrate the synergistic effects of disordered anatomy on the velopharyngeal port could also be of utility. Future studies should assess the relationship between perceptual severity and anatomical features. Volumetric investigations of the nasopharyngeal port and cerebellum and its effects of linear measures such as cranial base angles could shed insight regarding the dimensions of the velopharynx and vocal tract in individuals with 22q11.2 DS.

CONCLUSION

In summary, children with 22q11.2 DS have several craniofacial and velopharyngeal characteristics that are significantly different compared to children with normal velopharyngeal anatomy. Children with 22q11.2 DS demonstrate multiple anatomic variations that may contribute to velopharyngeal dysfunction by altering the natural characteristics of the velopharyngeal port and its associated structures. The MRI methodology detailed in this study provides an effective and efficient means to evaluate the velopharynx and levator muscle in the pediatric 22q11.2 DS population. The discordant findings that have been reported in the literature may be related to the genetic variability of the syndrome. However, it also highlights the importance of the need for patient-specific intervention in this unique and complex population. There are multiple anatomic parameters and its variations to consider when deciding surgical intervention for velopharyngeal dysfunction in the 22q11.2 DS population. Future studies should have a larger sample of participants with 22q11.2 DS with equal number of participants per each resonance category.

REFERENCES

- Antshel, K. M., Fremont, W., Roizen, N. J., Shprintzen, R., Higgins, A. M., Dhamoon, A., & Kates, W. R. (2006). ADHD, major depressive disorder, and simple phobias are prevalent psychiatric conditions in youth with velocardiofacial syndrome. *Journal of the American Academy of Child and Adolescent Psychiatry*, 45(5), 596-603. doi: 10.1097/01.chi.0000205703.25453.5a [doi]
- Arvystas, M., & Shprintzen, R. J. (1984). Craniofacial morphology in the velo-cardio-facial syndrome. *Journal of Craniofacial Genetics and Developmental Biology*, 4(1), 39-45.
- Basta, M. N., Silvestre, J., Stransky, C., Solot, C., Cohen, M., McDonald-McGinn, D., . . . Jackson, O. A. (2014). A 35-year experience with syndromic cleft palate repair: Operative outcomes and long-term speech function. *Annals of Plastic Surgery*, 73 Suppl 2, S130-5. doi:10.1097/SAP.0000000000000286 [doi]
- Baylis, A. L., Munson, B., & Moller, K. T. (2008). Factors affecting articulation skills in children with velocardiofacial syndrome and children with cleft palate or velopharyngeal dysfunction: A preliminary report. *Cleft Palate-Craniofacial Journal*, 45(2), 193-207. doi:10.1597/06-012.1 [doi]
- Baylis, A. L., Watson, P. J., & Moller, K. T. (2009). Structural and functional causes of hypernasality in velocardiofacial syndrome. A pilot study. *Folia Phoniatrica Et Logopaedica*, 61(2), 93-96. doi:10.1159/000209252 [doi]
- Chegar, B. E., Tatum, S. A., 3rd, Marrinan, E., & Shprintzen, R. J. (2006). Upper airway asymmetry in velo-cardio-facial syndrome. *International Journal of Pediatric Otorhinolaryngology*, 70(8), 1375-1381. doi: S0165-5876(06)00059-0 [pii]
- Dalben Gda, S., Richieri-Costa, A., & Taveira, L. A. (2010). Craniofacial morphology in patients with velocardiofacial syndrome. *Cleft Palate-Craniofacial Journal*, 47(3), 241-246. doi:10.1597/08-278.1 [doi]
- D-Antonio, L. L., Davio, M., Zoller, K., Punjabi, A., & Hardesty, R. A. (2001). Results of furrow Z-plasty in patients with velocardiofacial syndrome. *Plastic and Reconstructive Surgery*, 107(4), 1077-1079.
- Durand, D. J., Young, M., Nagy, P., Tekes, A., & Huisman, T. A. (2015). Mandatory child life consultation and its impact on pediatric MRI workflow in an academic medical center. *Journal of the American College of Radiology : JACR*, 12(6), 594-598. doi: 10.1016/j.jacr.2014.12.015 [doi]
- Glander, K., 2nd, & Cisneros, G. J. (1992). Comparison of the craniofacial characteristics of two syndromes associated with the pierre robin sequence. *Cleft Palate-Craniofacial Journal*, 29(3), 210-219. doi:10.1597/1545-1569(1992)0292.3.CO;2 [doi]

- Halliday, M., & Kelleher, J. (2013). Question 1: Is sedation necessary for MRI in an infant? *Archives of Disease in Childhood*, 98(10), 825-828. doi:10.1136/archdischild-2013-304898 [doi]
- Heliovaara, A., & Hurmerinta, K. (2006). Craniofacial cephalometric morphology in children with CATCH 22 syndrome. *Orthodontics & Craniofacial Research*, 9(4), 186-192. doi:OCR373 [pii]
- Kirschner, R. E. (2005). Palatal anomalies and velopharyngeal dysfunction associated with chromosome 22q11.2 microdeletions. In K. Murphy, & P. Scramble (Eds.), *VCFS: Understanding microdeletion disorders*. Cambridge: Cambridge University Press.
- Kollara, L., & Perry, J. L. (2014). Effects of gravity on the velopharyngeal structures in children using upright magnetic resonance imaging. *Cleft Palate-Craniofacial Journal*, 51(6), 669-676. doi:10.1597/13-107 [doi]
- Kollara, L., Perry, J. L., & Hudson, S. (2016). Racial variations in velopharyngeal and craniometric morphology in children: An imaging study. *Journal of Speech, Language, and Hearing Research*, 59(1), 27-38. doi:10.1044/2015_JSLHR-S-14-0236 [doi]
- Kollara, L., Schenck, G. C., Perry, J. L., & Jaskolka, M. (2016). Examining A New Method to Studying Velopharyngeal Structures in A Child with 22q11.2 DS. *Manuscript in Preparation*
- Kuehn, D. P. (2003). MRI investigation of VCFS. *American Cleft Palate Craniofacial Association Annual Meeting*, Greenville, SC.
- Losken, A., Williams, J. K., Burstein, F. D., Malick, D. N., & Riski, J. E. (2006). Surgical correction of velopharyngeal insufficiency in children with velocardiofacial syndrome. *Plastic and Reconstructive Surgery*, 117(5), 1493-1498. doi:10.1097/01.prs.0000206377.14083.ce [doi]
- Milczuk, H. A., Smith, D. S., & Brockman, J. H. (2007). Surgical outcomes for velopharyngeal insufficiency in velocardiofacial syndrome and nonsyndromic patients. *The Cleft Palate-Craniofacial Journal : Official Publication of the American Cleft Palate-Craniofacial Association*, 44(4), 412-417. doi:05-136 [pii]
- Nachmani, A., Aizenbud, D., Berger, G., Berger, R. L., Hazan-Molina, H., & Finkelstein, Y. (2013). The prevalence of platybasia in patients with velopharyngeal incompetence. *Cleft Palate-Craniofacial Journal*, 50(5), 528-534. doi:10.1597/11-265 [doi]
- Park, M., Ahn, S. H., Jeong, J. H., & Baek, R. M. (2015). Evaluation of the levator veli palatini muscle thickness in patients with velocardiofacial syndrome using magnetic resonance imaging. *Journal of Plastic, Reconstructive & Aesthetic Surgery*, doi:S1748-6815(15)00191-6 [pii]

- Perry, J. L. (2011). Variations in velopharyngeal structures between upright and supine positions using upright magnetic resonance imaging. *Cleft Palate-Craniofacial Journal*, 48(2), 123-133. doi:10.1597/09-256 [doi]
- Perry, J. L., Kuehn, D. P., Sutton, B. P., & Fang, X. (2016). Velopharyngeal structural and functional assessment of speech in young children using dynamic magnetic resonance imaging. *The Cleft Palate-Craniofacial Journal : Official Publication of the American Cleft Palate-Craniofacial Association*, doi:10.1597/15-120 [doi]
- Perry, J. L., Kuehn, D. P., Sutton, B. P., Gamage, J. K., & Fang, X. (2016). Anthropometric analysis of the velopharynx and related craniometric dimensions in three adult populations using MRI. *The Cleft Palate-Craniofacial Journal : Official Publication of the American Cleft Palate-Craniofacial Association*, 53(1), e1-e13. doi:10.1597/14-015 [doi]
- Perry, J. L., Kuehn, D. P., Sutton, B. P., Goldwasser, M. S., & Jerez, A. D. (2011). Craniometric and velopharyngeal assessment of infants with and without cleft palate. *Journal of Craniofacial Surgery*, 22(2), 499-503. doi:10.1097/SCS.0b013e3182087378 [doi]
- Punjabi, A., Holshouser, B. A., D'Antonio, L. L., & Kuehn, D. P. (2002). Magnetic resonance imaging of the velopharynx in patients with velocardiofacial syndrome. *American Cleft Palate Craniofacial Association Annual Meeting*, Seattle, WA.
- Ruotolo, R. A., Veitia, N. A., Corbin, A., McDonough, J., Solot, C. B., McDonald-McGinn, D., . . . Kirschner, R. E. (2006). Velopharyngeal anatomy in 22q11.2 deletion syndrome: A three-dimensional cephalometric analysis. *Cleft Palate-Craniofacial Journal*, 43(4), 446-456. doi:04-193R [pii]
- Shprintzen, R. J. (2008). Velo-cardio-facial syndrome: 30 years of study. *Developmental Disabilities Research Reviews*, 14(1), 3-10. doi:10.1002/ddrr.2 [doi]
- Shprintzen, R. J., & Golding-Kushner, K. (2008). *Velo-cardio-facial syndrome volume I* Plural Publishing.
- Spruijt, N. E., Kon, M., & Mink van der Molen, A. B. (2014). Platybasia in 22q11.2 deletion syndrome is not correlated with speech resonance. *Archives of Plastic Surgery*, 41(4), 344-349. doi:10.5999/aps.2014.41.4.344 [doi]
- Tian, W., Li, Y., Yin, H., Zhao, S. F., Li, S., Wang, Y., & Shi, B. (2010). Magnetic resonance imaging assessment of velopharyngeal motion in chinese children after primary palatal repair. *Journal of Craniofacial Surgery*, 21(2), 578-587. doi: 10.1097/SCS.0b013e3181d08bee [doi]
- Tian, W., Yin, H., Redett, R. J., Shi, B., Shi, J., Zhang, R., & Zheng, Q. (2010). Magnetic resonance imaging assessment of the velopharyngeal mechanism at rest and during speech in chinese adults and children. *Journal of Speech, Language, and Hearing Research : JSLHR*, 53(6), 1595-1615. doi:10.1044/1092-4388(2010/09-0105) [doi]

- Veerapandiyan, A., Blalock, D., Ghosh, S., Ip, E., Barnes, C., & Shashi, V. (2011). The role of cephalometry in assessing velopharyngeal dysfunction in velocardiofacial syndrome. *Laryngoscope*, *121*(4), 732-737. doi:10.1002/lary.21449 [doi]
- Wang, K., Yang, Y., Shen, F., Tao, J., Xu, H., Portnof, J. E., . . . Salyer, K. E. (2009). Utilization of three-dimensional computed tomography for craniofacial phenotypic analysis in children with velocardiofacial syndrome. *Journal of Craniofacial Surgery*, *20*(6), 2013-2019. doi:10.1097/SCS.0b013e3181bd2e34 [doi]
- Witt, P., Cohen, D., Grames, L. M., & Marsh, J. (1999). Sphincter pharyngoplasty for the surgical management of speech dysfunction associated with velocardiofacial syndrome. *British Journal of Plastic Surgery*, *52*(8), 613-618. doi:10.1054/bjps.1999.3168 [doi]
- Ysunza, A., Carmen Pamplona, M., & Santiago Morales, M. A. (2011). Velopharyngeal valving during speech, in patients with velocardiofacial syndrome and patients with non-syndromic palatal clefts after surgical and speech pathology management. *International Journal of Pediatric Otorhinolaryngology*, *75*(10), 1255-1259. doi:10.1016/j.ijporl.2011.07.001 [doi]
- Ysunza, A., Pamplona, M. C., Molina, F., & Hernandez, A. (2009). Surgical planning for restoring velopharyngeal function in velocardiofacial syndrome. *International Journal of Pediatric Otorhinolaryngology*, *73*(11), 1572-1575. doi:10.1016/j.ijporl.2009.08.007 [doi]
- Ysunza, A., Pamplona, M. C., Ortega, J. M., & Prado, H. (2008). Video fluoroscopy for evaluating adenoid hypertrophy in children. *International Journal of Pediatric Otorhinolaryngology*, *72*(8), 1159-1165. doi:10.1016/j.ijporl.2008.03.022 [doi]
- Zim, S., Schelper, R., Kellman, R., Tatum, S., Ploutz-Snyder, R., & Shprintzen, R. (2003). Thickness and histologic and histochemical properties of the superior pharyngeal constrictor muscle in velocardiofacial syndrome. *Archives of Facial Plastic Surgery*, *5*(6), 503-510. doi:10.1001/archfaci.5.6.503 [doi]

CHAPTER 7

GENERAL CONCLUSION

Limited information exists regarding the velopharyngeal muscle characteristics for children with 22q11.2 DS. No studies to date have utilized MRI without sedation in young children with 22q11.2 DS to examine velopharyngeal muscle morphology and associated structures. The overarching aims of this investigation were to examine craniofacial and velopharyngeal features among children with 22q11.2 DS and to determine whether craniofacial measures could predict velopharyngeal structure and muscle configurations in this population. A series of experiments were designed to explore and validate the use of our research methodology on normal control participants and a single participant with 22q11.2 DS, before initiating the study on a larger sample of children with 22q11.2 DS.

Study I validated the use of a supine MRI scanner over an upright scanner to obtain data of interest. Gravity was found to have a non-significant effect on the velopharyngeal structures of interest. This study was also instrumental in the development of a child-friendly MRI scanning protocol.

Study II was focused on the application of the child-friendly MRI protocol to ensure data collection on the child participants without the use of sedation. The effects that race and sex may have on the variables of interest were also investigated. No significant sex effects were noted for the craniometric and velopharyngeal variables of interest. Significant racial differences were noted for velar thickness, velar length, and velopharyngeal ratio. The child-friendly MRI scanning protocol from Study I was successfully implemented with 100% success rate on 32

children. Hard palate length was found to be the most common craniometric predictor for the velopharyngeal muscle prediction models.

Study III confirmed feasibility of our non-sedated MRI protocol in a single participant with 22q11.2 DS (the targeted clinical population). Preliminary data regarding velopharyngeal muscle variations for this population were also reported. The participant with 22q11.2 DS was found to have a short, U- shaped levator muscle arrangement in the oblique coronal image plane. In the mid sagittal image plane, the velum was found to be short and thin and an increased pharyngeal depth was also noted.

Study IV (final dissertation study) assessed variations in craniofacial and velopharyngeal structures in a larger sample of children with 22q11.2 DS using a supine MRI scanner and by utilizing our established child-friendly MRI protocol. This study represents the first large scale attempt to image children with 22q11.2 DS without sedation. Children with 22q11.2 DS were found to have several craniofacial and velopharyngeal characteristics that are significantly different compared to children with normal velopharyngeal anatomy. This is the first study to report that the length of the levator muscle is significantly shorter in the 22q11.2 DS population and the first to assess the predictive ability of bony craniofacial structures on muscle form and function in children with 22q11.2 DS. This study offers the foundation for multiple opportunities to further research focused to better understand variations between individuals with 22q11.2 DS, in comparison to cleft palate groups, other syndromic populations, and those with normal velopharyngeal anatomy.

APPENDIX A: INSTITUTIONAL REVIEW BOARD APPROVAL FOR EAST CAROLINA UNIVERSITY



EAST CAROLINA UNIVERSITY
University & Medical Center Institutional Review Board Office
4N-70 Brody Medical Sciences Building · Mail Stop 682
600 Moye Boulevard · Greenville, NC 27834
Office 252-744-2914 · Fax 252-744-2284 · www.ecu.edu/irb

Notification of Amendment Approval

From: Biomedical IRB
To: [Jamie Perry](#)
CC: [Jamie Perry](#)
[Jamie Perry](#)
Date: 2/11/2016
Re: [Ame11 UMCIRB 11-001103](#)
[UMCIRB 11-001103](#)
Variations in VP structure between upright and supine MRI in children and adults

Your Amendment has been reviewed and approved using expedited review for the period of 2/10/2016 to 12/1/2016 . It was the determination of the UMCIRB Chairperson (or designee) that this revision does not impact the overall risk/benefit ratio of the study and is appropriate for the population and procedures proposed.

Please note that any further changes to this approved research may not be initiated without UMCIRB review except when necessary to eliminate an apparent immediate hazard to the participant. All unanticipated problems involving risks to participants and others must be promptly reported to the UMCIRB. A continuing or final review must be submitted to the UMCIRB prior to the date of study expiration. The investigator must adhere to all reporting requirements for this study.

Approved consent documents with the IRB approval date stamped on the document should be used to consent participants (consent documents with the IRB approval date stamp are found under the Documents tab in the study workspace).

The approval includes the following items:

| Document | Description |
|--|-------------------------------------|
| ECU Phone Call (Shriners Patients)(0.01) | Recruitment Documents/Scripts |
| Initial Letter (Shriners)(0.01) | Recruitment Documents/Scripts |
| Shriners Phone Script(0.01) | Recruitment Documents/Scripts |
| The Research Protocol - amendment 11(clean copy).docx(0.10) | Study Protocol or Grant Application |
| The Research Protocol - amendment 11(tracked changes).docx(0.11) | Study Protocol or Grant Application |

The Chairperson (or designee) does not have a potential for conflict of interest on this study.

APPENDIX B: INSTITUTIONAL REVIEW BOARD APPROVAL FOR NATIONWIDE CHILDREN'S HOSPITAL

Page 1 of 2



August 27, 2015

Adriane Baylis
Plastic Surgery

Study ID: IRB15-00580

Study Name: MRI Investigation of Velopharyngeal Closure for Speech in 22q11.2 Deletion Syndrome

The Institutional Review Board Expedited Committee has reviewed and approved the response to modifications for the above study application on 8/25/2015. **STUDY APPROVED**

Date of Approval: 8/14/2015

Date of Expiration: 8/13/2016

(the expiration date is the last day that the study has IRB approval)

Expedited Review Category: 4,5 and 6

Risk Level: The IRB assigned a Risk Level 1 - no greater than minimal risk (45 CFR 46.404; 21 CFR 50.51).

Waivers Granted: None

Please note the following responsibilities:

AMENDMENTS: The Principal Investigator (PI) is responsible for notifying the IRB of any changes in the protocol, procedures, recruitment, consent forms, etc. This approval is based on the information as submitted. New procedures cannot be initiated until IRB approval has been given. If you wish to change any aspect of this study, please submit an amendment providing as justification for each change.

CONTINUING REVIEW: The PI is responsible for submitting a Continuing Review to the IRB at least 30 days prior to the expiration date listed above. Please note that study procedures may only continue into the next year if the IRB has reviewed and granted re-approval prior to the expiration date.

UNANTICIPATED PROBLEMS: The PI is responsible for reporting unanticipated problems involving risks to participants or others promptly to the IRB according to the current reporting policy found on our website. (SEE SOP IRB-12)

STUDY COMPLETION: Please complete a Final Report when the research, including data analysis, has been completed.

LEAVING THE INSTITUTION: You must notify the IRB of the disposition of all research studies when you leave NCH.

OTHER INFORMATION:

- IRB Policy requires that provisions are made for assent of subjects age nine and older.
- The Federalwide Assurance number assigned to the IRB at Nationwide Children's Hospital is **FWA000002860**.

If we can provide additional assistance, please do not hesitate to call the IRB office at 614-722-2708.

Sincerely,

Karen A. White, Ph.D., Chair
Institutional Review Board

APPENDIX C: INSTITUTIONAL REVIEW BOARD APPROVAL FOR UNIVERSITY OF ILLINOIS AT URBANA-CHAMPAIGN

RECEIVED
NOV 09 2011
VICE CHAN FOR RES



Federal Wide Assurance: FWA00008584
IRB 2 Registration: IRB00007613

Institutional Review Board (No. 2) Authorization Agreement

1. Identification of Parties.

1.1. Name of Institution Providing IRB Review: University of Illinois at Urbana-Champaign, IRB No. 2 ("Illinois No. 2")

1.2. Name of Institution Relying on the Illinois IRB: East Carolina University ("Institution B")
FWA #: FWA0000658
Address: 600 Mowbray Blvd, Brody Medical Sciences Building, Brody 1L-09, Greenville, NC 27834

2. Identification of Human Subjects Research. The parties agree that Institution B may rely on Illinois No. 2 for review and continuing oversight of Institution B's human subjects research described as follows ("Research"):

Name of Research Project: MRI of head in Children
Name of Principal Investigator: UIUC IRB# 11099; Brad Sutton/UIUC, Jamie Perry/ECU
Sponsor or Funding Agency: _____
Award Number, if any: _____
Other information: _____

This agreement applies to the described Research only and to no other research in which Institution B may be engaged now or in the future.

3. Request to Consider Alteration to or Waiver of HIPAA Authorization. By checking this box, Institution B states that: (a) it is a covered entity as defined by the Health Information Portability and Accountability Act ("HIPAA") and its regulations; (b) the Research may require Institution B to use or disclosure protected health information ("PHI") as defined by HIPAA; and (c) pursuant to 45 CFR §164.512(l)(A), Institution B requests that Illinois No. 2 approve either an alteration to, or waiver, in whole or in part, of the HIPAA authorization required for Institution B's use or disclosure of PHI for the Research.

4. Institution B Representations. Institution B represents that it: (a) has designated the Illinois No. 2 on its FWA; (b) shall remain responsible for ensuring compliance with the Illinois No. 2's determinations, with the terms of Institution B's OHRP-approved FWA, and with all laws governing the Research; (c) and shall immediately report to Illinois No. 2 in writing upon becoming aware of any new or continuing noncompliance with any relevant contract, law or institutional policy governing the Research, including but not limited to human subject protections, conflicts of interest, and research misconduct. Institution B's obligation to report under 4(c) is in addition to, and in no way replaces, a principal investigator's duty to report any matters such as unanticipated problems involving risks to subjects and others. Institution B shall make all such reports to the Director of Illinois No. 2.

5. Illinois No. 2's Representations. In performing its review and continuing oversight of the Research, Illinois No. 2 represents that it shall: (a) comply with the requirements of the Common Rule as codified in regulation; (b) meet the human subject protection requirements of Institution B's OHRP-approved FWA; (c) follow written procedures for reporting its findings and actions to appropriate officials at Institution B; and (d) make available to Institution B upon its request relevant minutes of IRB meetings.

6. Notice of Agency Action. Each party will immediately report to the other if any oversight agency or organization initiates any action or investigation that may adversely affect the Research.

RECEIVED
NOV 09 2011
VICE CHAN FOR RES

7. **Record Retention.** Each party shall keep this document on file for no less than six years after completion of the Research and shall provide a copy of it to OHRP upon request.

8. **Liability.** Neither party assumes liability for the acts or omissions chargeable to the other party unless otherwise imposed by law.

For ILLINOIS:

By: Ravi K. Jain Date: 9-14-2011
FWA Signatory Official

The Board of Trustees of the University of Illinois

By: Walter K. Knorr
Walter K. Knorr, Comptroller 9/16/11

For INSTITUTION B:

By: Deirdre M. Mageean Date: 09/07/2011
FWA Signatory Official
Printed Name: Deirdre M. Mageean Title: Vice Chancellor and
Institutional Official

Approved for legal form by LMP/2011.08.29

APPENDIX D: PERMISSION LETTER FROM CLEFT PALATE-CRANIOFACIAL
JOURNAL



Date: June 22, 2016

Dear Lakshmi Kollara Sujnil,

On behalf of Allen Press Publishing Services, I am pleased to grant permission to you for the reprinting of the following:

"Effects of gravity on the velopharyngeal structures in children using upright magnetic resonance imaging" by Kollara L, Perry JL appearing in *The Cleft Palate – Craniofacial Journal* 51.6 (2014).

For use in a doctoral dissertation.


This permission is a one-time, non-exclusive, electronic worldwide grant for English language use as described in this letter, and is subject to the following conditions:

1. No payment required.
2. Each copy containing our material that you reproduce or distribute must bear the appropriate copyright information, crediting the author, journal, and publisher (*The Cleft Palate – Craniofacial Journal*, Allen Press Publishing Services).

If these terms are acceptable, please sign and date, and fax back to my attention at 785-843-1853. This permission will be effective upon our receipt of the signed contract. If applicable, when sending payment, please make clear reference to our title and author. Materials should be addressed to *The Cleft Palate – Craniofacial Journal*, c/o Lindsey Givens, P.O. Box 1897, Lawrence, KS 66044.

Sincerely,

Marilyn Kearney
Publishing Specialist
Allen Press Publishing Services

AGREED:  DATE: 6/22/16

_____ We have elected not to use this material

APPENDIX E: PERMISSION LETTER FROM JOURNAL OF SPEECH, LANGUAGE, AND
HEARING RESEARCH

permission to use article in dissertation



Permissions Asha <Permissions@asha.org>

06/24/2016

Kollara Sunil, Lakshmi ✉

Dear Lakshmi:

Thank you for contacting ASHA Permissions. Permission is granted to reprint

Racial Variations in Velopharyngeal and Craniometric Morphology in Children: An Imaging Study.

Kollara L, Perry JL, Hudson S.

J Speech Lang Hear Res. 2016 Feb 1;59(1):27-38. doi: 10.1044/2015_JSLHR-S-14-0236.

PMID: 26540447

in your forthcoming dissertation. Please cite ASHA as the source and include a link to the original article (<http://jslhr.pubs.asha.org/article.aspx?articleid=2469135&resultClick=3>).

Best regards,

Libby

Libby Bauer

Associate Director of Serial Publications

American Speech-Language-Hearing Association

