



## Acute motor neuropathy with quadriplegia following treatment with triple tyrosine kinase inhibitor, nintedanib



Afua Kunadu<sup>a,\*</sup>, Shehabaldin Alqalyoobi<sup>a</sup>, Robert C. Frere<sup>b</sup>, Ogugua Ndili Obi<sup>a</sup>

<sup>a</sup> Division of Pulmonary, Critical Care and Sleep Medicine, Brody School of Medicine, East Carolina University, Greenville, NC, USA

<sup>b</sup> Division of Neurology, Brody School of Medicine, East Carolina University, Greenville, NC, USA

### ARTICLE INFO

#### Keywords:

Nintedanib  
Guillain barre  
Interstitial lung disease  
Motor neuropathy  
Idiopathic pulmonary fibrosis

### ABSTRACT

Idiopathic pulmonary fibrosis (IPF) is a rare progressive interstitial lung disease characterized by declining lung function, worsening dyspnea and poor prognosis with median survival of 3–5 years. IPF predominantly affects people over 60 years, it however has worse prognosis in younger patients with genetic predisposition like short telomere syndrome. Nintedanib, one of two anti-fibrotic therapies approved for IPF treatment has occasional neurological side effects like fatigue, dizziness and headaches. Significant polyneuropathy or motor dysfunction is rarely seen. This case report illustrates a patient who developed quadriplegia following initiation of Nintedanib.

### 1. Introduction

Idiopathic pulmonary fibrosis (IPF) is a rare progressive interstitial lung disease characterized by declining lung function, worsening dyspnea, exercise capacity and poor prognosis with median survival of 3–5 years [1,2]. IPF predominantly affects people over the age of 60, however it has worse prognosis in younger patients with genetic predisposition like short telomere syndrome [3].

Nintedanib, one of two anti-fibrotic therapies approved for IPF treatment, is associated with predominantly gastrointestinal adverse effects with rare neurological side effects like fatigue, dizziness and headaches [4]. Significant polyneuropathy or motor dysfunction is rarely seen. We present the case of a patient who developed quadriplegia following initiation of Nintedanib.

#### 1.1. Case report

A 39-year-old Caucasian male with suspected familial IPF secondary to short telomere syndrome (telomere length < 1st percentile using flow cytometry and FISH; mom had IPF), was started on Nintedanib for symptomatic progressive fibrosis six months after his initial diagnosis (See Fig. 1–3 for chest computed tomography and telomere length test images, and Table 1 for details of initial work up).

Figures: 1 and 2 showing Bilateral Subpleural honeycombing in axial and coronal views.

24 hours after his first dose of Nintedanib, he developed tingling “pins and needle” sensation in his fingers and toes. This progressed rapidly over the next 2 days to bilateral upper and lower extremity numbness and motor weakness by the 4th day prompting him to seek medical attention. Upon presentation to the emergency department (ED), he was unable to lift his arms against gravity and had a fall at home due to severe lower extremity motor weakness and loss of sensation in his feet. He took a total of 6 doses of Nintedanib dosed at 150mg twice a day. Prior to initiating Nintedanib, he had no motor or sensory complaints. He had chronic shortness of breath and dry cough from his underlying disease, but otherwise denied any fevers, chills or upper respiratory symptoms. He had multiple loose stools on the first day of symptoms which self-resolved. There was no associated abdominal pain, nausea or vomiting. There was no worsening of his respiratory symptoms. His only other medications were omeprazole for acid reflux and fluticasone propionate for chronic sinusitis. Neurological examination in the ED was notable for areflexia with flaccid paresis in all extremities (Table 2 - shows detailed physical exam).

He had extensive autoimmune and neurological workup which was mostly negative with the exception of marginally decreased IgG subclass 3 and low thiamine levels. Cerebro-spinal fluid analysis from lumbar puncture was unrevealing with normal protein level and white blood cell count. Brain and pan spinal magnetic resonance imaging (MRI) were also unremarkable without any evidence of nerve root enhancement (see Table 3 for details of work up).

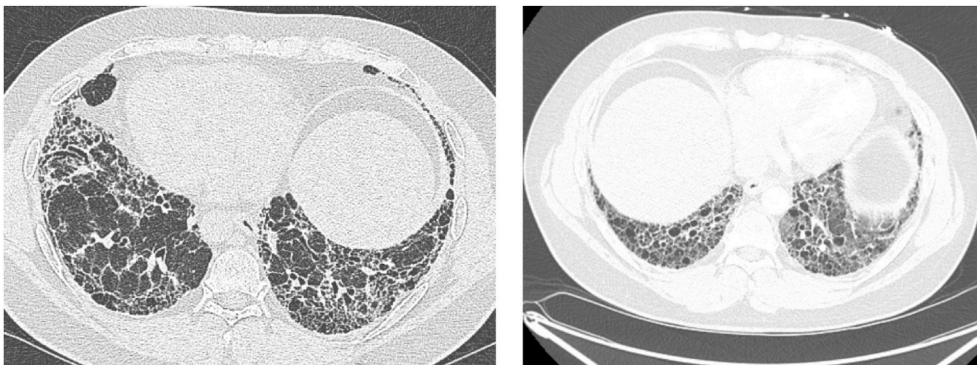
\* Corresponding author. 3E-149E Brody Medical Sciences Building, 600 Moye Blvd, Mail stop 628, East Carolina University, Greenville, NC, 27834-4354, USA.

E-mail address: [totezee@yahoo.com](mailto:totezee@yahoo.com) (A. Kunadu).

Available online 17 July 2021

<https://doi.org/10.1016/j.rmcr.2021.101472>

Published by Elsevier Ltd. This is an open access article under the CC BY-NC-ND license  
Received 25 February 2021; Received in revised form 29 May 2021; Accepted 6 July 2021



**Fig. 1.** Bilateral Subpleural honeycombing in axial view. Figure Legend: High Resolution Chest CT Scan images at diagnosis showing basal predominant honeycomb cystic changes.

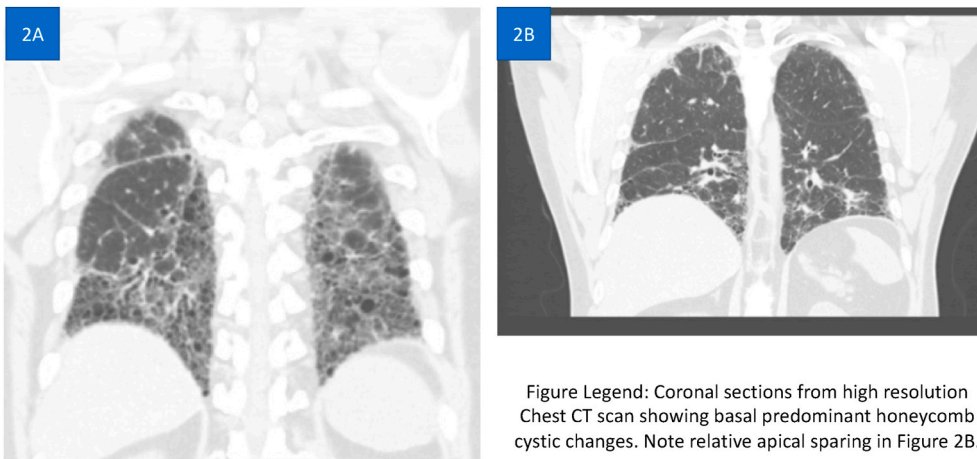
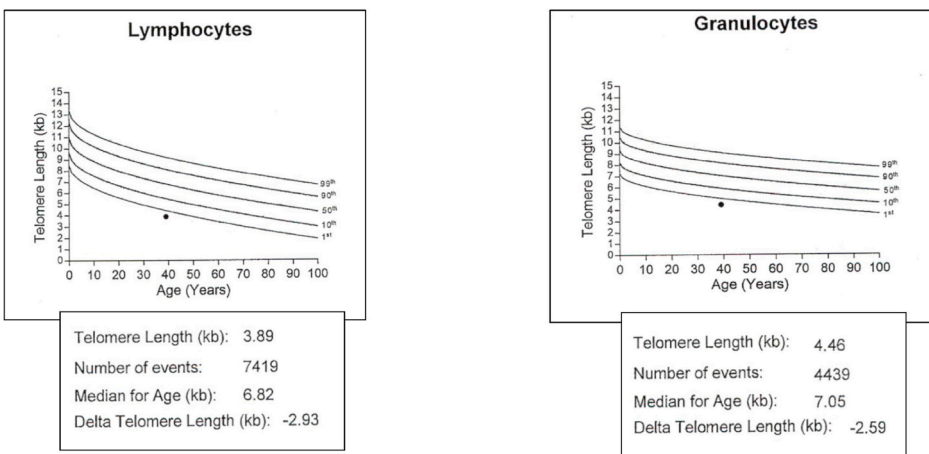


Figure Legend: Coronal sections from high resolution Chest CT scan showing basal predominant honeycomb cystic changes. Note relative apical sparing in Figure 2B.

**Fig. 2.** Bilateral Subpleural honeycombing in coronal view. Figure Legend: Coronal sections from high resolution Chest CT scan showing basal predominant honeycomb cystic changes. Note relative apical sparing in Figure 2B.



<sup>1</sup>Baerlocher, G., Vulto, I., de Jong, G. et al. Flow cytometry and FISH to measure the average length of telomeres (flow FISH). *Nat Protoc* 1, 2365–2376 (2006)

**Fig. 3.** Telomere Length as measured on peripheral blood cells using flow cytometry and fluorescent in situ hybridization (FISH)<sup>1</sup>. 1. Baerlocher, G., Vulto, I., de Jong, G. et al. Flow cytometry and FISH to measure the average length of telomeres (flow FISH). *Nat Protoc* 1, 2365–2376 (2006)

Electrodiagnostic study done 8 days after initial onset of symptoms showed evidence of motor polyneuropathy involving the upper and lower extremities with limited demyelinating features (Table 4A, C, D). It also showed normal upper and lower extremity sensory potentials (Table 4B). Repetitive nerve stimulation did not identify a

neuromuscular junction disorder. There was concern that this acute motor neuropathy had possibly been triggered by his new anti-fibrotic therapy.

Intravenous immunoglobulin and plasmapheresis were discussed but not initiated because he began to improve clinically with physical

**Table 1**

Initial Work up done at the time of IPF diagnosis.

<p>Positive Workup:</p> <ul style="list-style-type: none"> <li>-Aldolase - 9.7 (Upper limit of Normal, 8.1)</li> <li>-ESR: 23 (Elevated)</li> <li>-C-Reactive Protein: 6.6 (Elevated)</li> <li>-Immunoglobulin G (IgG) subclass 3: 20, low (22–178)</li> </ul> <p>FISH peripheral blood mononuclear cell (PBMC) telomere length study: Abnormally short telomere length (see Fig. 3).</p> <p>Negative workup (Including Autoimmune work up):</p> <ul style="list-style-type: none"> <li>-Antinuclear Antibody</li> <li>-Anti Double stranded Antibody</li> <li>-Anti Smith Antibody</li> <li>-Anti Scleroderma Antibody</li> <li>-Anti JO-1 Antibody</li> <li>-CO-GM-1 Triad Antibody</li> <li>-Ganglioside GQ1B Antibody</li> <li>-Glomerular membrane Antibody</li> <li>-Immunoglobulin A and G</li> <li>-Paraneoplastic Autoantibody Panel</li> <li>-Rheumatoid Factor</li> <li>-Anti Citrullinated Peptide</li> <li>-U1 RNP Antibody</li> <li>-Anti Sjogren Antibodies (SSA/SSB)</li> <li>-Anti Centromere Antibody</li> <li>-Anti- topoisomerase Antibody</li> <li>-HIV</li> <li>-Extended Myositis Panel- SSA-52 IgG Ab, SSA-60 IgG Ab, Smith/RNA OgG Ab, Jo-1 IgG Ab, PL-12 Ab, PL-17 Ab, PL-7 Ab, EJ Ab, Oj Ab, SRP Ab, Ku Ab, PM/Sc 100 Ab, Fibrillar IgG Ab, P155/140 Ab, Mi-2 Ab, TIF-1 gamma Ab, SAE1 Ab, MDA 5 Ab, NXP2 Ab</li> </ul> <p>Pulmonary Function Test</p> <ul style="list-style-type: none"> <li>Forced Vital Capacity (FVC) 2.94L (55% of predicted)</li> <li>Forced Expiratory Volume in the first second (FEV1) = 2.41L (56% of predicted)</li> <li>FEV1/FVC = 82</li> <li>Total Lung Capacity (TLC) = 4.60L (66%)</li> <li>Diffusion Capacity (DLCO) = 13.63 ml/min/mmHg (42% predicted)</li> <li>Six-Minute Walk Distance (6MWD)</li> <li>Walked 67% of expected distance with significant desaturation requiring 2L of oxygen via nasal cannula to complete 6MWT</li> </ul>
---

**Table 2**

Detailed Physical examination upon presentation.

<p>Admission Vitals: BP 134/99   Pulse 96 bpm   Temp 36.7 °C (98 °F)   Resp 19 bpm'   Ht 1.778 m   Wt. 104.5 kg   SpO2 98%   BMI 33.06 kg/m<sup>2</sup></p> <p>General: Well-built obese Caucasian man in no respiratory distress</p> <p>Eyes: Pupils equal and reactive to light, no conjunctival pallor or scleral icterus</p> <p>ENT: oropharynx without any lesions</p> <p>Neck: supple, jugular veins not distended</p> <p>Respiratory: No respiratory distress, bilateral fine velcro crackles in the mid and lower lung zones</p> <p>CVS: Normal 1st and 2nd heart sounds, no murmurs, rubs or gallop, no pedal edema, distal pulses palpable and equal bilaterally</p> <p>GI: Abdomen non distended, soft, mild epigastric tenderness, normoactive bowel sounds</p> <p>Skin: warm and well perfused, no rashes</p> <p>Neurology: Alert and oriented to person, place and time. Cranial Nerves: II - Visual fields full to finger confrontation at bedside. Pupils equal and reactive. Discs sharp. CN III, IV and VI - Extraocular movements intact. No nystagmus. V - Sensory branches intact. VII - Face symmetric. VIII - Hearing intact bilaterally. CV IX, X and XII - Tongue, uvula and palate mid position.</p> <p>Motor Examination: Decreased tone, normal muscle bulk. Power 3/5 in both proximal and distal muscle groups of lower extremities and 4/5 in all upper extremity muscle groups</p> <p>Coordination: Dysmetria on finger-to-nose-test bilaterally</p> <p>Reflexes: Areflexic. Lower extremity fasciculations present.</p> <p>Sensation: Intact to light touch and temperature but impaired to pin prick in bilateral lower extremities without spinal sensory level</p> <p>Gait: Wobbly, unsteady gait, barely able to take a few steps without falling</p> <p>KEY:</p> <p>Ht = Height; Wt. = Weight; SPO2 = Oxygen saturation as measured on finger pulse oximetry</p> <p>Bpm = beats per minute; bpm' = breaths per minute</p>
---

**Table 3**Respiratory Medicine Case Reports 34 (2021) 101472  
Work up done on admission.

<p>Normal Work-up Results</p>	<p><b>Auto-Immune and Inflammatory work-up:</b></p> <ul style="list-style-type: none"> <li>Creatine phosphokinase (CPK) Normal</li> <li>(Erythrocyte sedimentation rate ESR) normal</li> <li>Antinuclear Antibody: &lt;40</li> <li>Anti-scleroderma Antibody</li> <li>Anti-Native DNA (Double stranded) antibody</li> <li>Glomerular Basement Antibody</li> <li>Anti-smooth muscle Antibody</li> <li>U1 RNP/SNRRNP IgG antibody</li> </ul> <p><b>Paraneoplastic Antibody Work-up</b></p> <ul style="list-style-type: none"> <li>Paraneoplastic Antibodies</li> <li>CO-GM-Triad Antibody</li> <li>Ganglioside GQ1B Antibody</li> </ul> <p><b>Infectious Work-up:</b></p> <ul style="list-style-type: none"> <li>Lyme disease IgG and IgM antibodies</li> <li>Negative HIV</li> </ul> <p><b>Nutritional Work-up:</b></p> <ul style="list-style-type: none"> <li>Normal Vitamin B12 levels</li> </ul> <p><b>Heavy Metal Screen:</b></p> <ul style="list-style-type: none"> <li>Negative heavy metal screen</li> </ul> <p><b>Cerebrospinal Fluid (CSF) Analysis</b></p> <ul style="list-style-type: none"> <li>CSF Glucose 54- Normal</li> <li>CSF Protein 30.5- Normal</li> </ul> <p><b>Others:</b></p> <ul style="list-style-type: none"> <li>Complete Blood Count</li> <li>Comprehensive chemistry and liver panels</li> <li>Hypersensitivity panel</li> <li>Serum and Urine Protein electrophoresis</li> <li>Elevated C-reactive protein 7.1 (&lt;5 mg/l)</li> <li>Low Vitamin B1 (Thiamine) levels &lt;6 (8–30nmol/l)</li> <li>Low Immunoglobulin G (IgG) subclass 3: 20 (22–178)</li> <li>Abnormal Nerve Conduction Studies (See Table 4A for details)</li> </ul>
<p>Abnormal Results</p>	

therapy and discontinuation of nintedanib. At the time of discharge, he was ambulating with minimal assistance and gradually regained his strength back to baseline over the next 2–3 weeks post discharge.

## 2. Discussion

Nintedanib is a tyrosine kinase inhibitor (TKI) which works by blocking the receptors of vascular endothelial growth factor (VEGF), fibroblast growth factor, platelet-derived growth factor and  $\beta$  kinase activity. These have been implicated in the pathogenesis of IPF. Nintedanib binds competitively to the adenosine triphosphate binding pocket of these receptors and blocks the intracellular signaling, which is crucial for proliferation, migration, and fibroblast to myofibroblast transformation of lung fibroblasts, thereby inhibiting essential pathways in the pathogenesis of IPF [5].

Nintedanib, has been shown to slow the rate of decline in forced vital capacity in IPF [4]. More recently, it has been shown to be efficacious in slowing disease progression in progressive fibrosing ILD of other etiologies [6–8]. With its widening use, it is important to monitor for potential adverse effects aside from what was noted in initial experimental trials of which diarrhea was the commonest [4]. During the experimental phases of the then test drug BIBF 1120 (Nintedanib), rodents and non-rodents who received this medication displayed some elements of neurological toxicity like abnormal gait and paralysis after receiving nintedanib, but these symptoms did not persist [9].

Other TKIs have also been reported to cause neurotoxicity. Tandu-tinib, an experimental first generation FLT3 inhibitor, has been shown in experimental studies to cause reversible muscle weakness and electro-physiologic changes consistent with neuromuscular junction dysfunction and peripheral neuropathy, [10] [[11,12]. Sunitinib, a

**Table 4A**  
Electrodiagnostic motor nerve studies.

Nerve/Sites	Muscle	Latency Ms	Amplitude MV	Segments	Distance cm	Lat Diff ms	Velocity m/s	Temp °C
<b>L Median- APB</b>								
Wrist	APB	3.8	1.5	Wrist- APB	5			20
Elbow	APB	9.1	1.1	Elbow- Wrist	25	5.3	47	20
<b>R Median- APB</b>								
Wrist	APB	3.5	2.9	Wrist-APB	5			31.9
<b>L Ulnar-ADM</b>								
Wrist	ADM	2.8	3.6	Wrist-ADM	5			32
B. Elbow	ADM	6.3	1.6	B. Elbow- Wrist	22	3.5	63	32
A. Elbow	ADM	10.1	0.7	A. Elbow Wrist	32	7.3	44	32
<b>R Ulnar- ADM</b>								
Wrist	ADM	2.1	3.1	Wrist- ADM	5			31.9
<b>L. Peroneal-EDB</b>								
Ankle	EDB	5.5	3.6	Ankle-EDB	8			31.9
Fib Head	EDB	13.1	3.0	Fib Head- Ankle	33	7.6	43	31.9
Pop Fossa-Ankle	EDB	14.8	2.8	Pop Fossa- Ankle	43	9.3	46	31.9
<b>L. Tibial- AH</b>								

Motor nerve studies showing reduced bilateral upper extremity motor amplitudes with borderline left median conduction velocity and slowed left ulnar motor conduction velocity. Left ulnar amplitude is significantly reduced at the elbow by 80% (>20% drop is abnormal) compared to wrist with significant amplitude increase of over 50% and nearly 20m/s conduction velocity increase with stimulation below the elbow consistent with conduction block at the level of the elbow. This could be consistent with demyelination.

**Table 4B**  
Electrodiagnostic sensory nerve studies.

Nerve/Sites	Rec. Site	Peak Lat ms	Amp µV	Segments	Distance cm	Peak Diff ms	Velocity m/s	Temp °C
<b>L Median-Digit II (Antidromic)</b>								
Wrist	Dig II	2.9	28	Wrist- Dig II	13		61	31.9
<b>L Radial- Anatomical Snuff box (Forearm)</b>								
Forearm	Wrist	2.2	44	Forearm- Wrist	10		58	31.8
<b>L Superficial Peroneal- Ankle</b>								
Lat Leg	Ankle	2.6	8	Lat Leg- Ankle	10		51	32
<b>L Median, Ulnar- Transcarpal comparison</b>								
Median Palm	Wrist	1.7	59	Median Palm- Wrist	8		64	32
Ulnar Palm	Wrist	1.8	17	Ulnar Palm- Wrist	8		59	32
				Median Palm-Ulnar Palm		-0.1		32
<b>L Sural- Ankle (A 7cm, B 14cm, C 21cm)</b>								
Calf (A)	Lat mall	2.2	18	Calf (A)- Lat mall	7		45	32
Calf (B)	Lat mall	3.6	13	Calf (B)- Lat mall	14		51	32
Calf (C)	Lat mall	4.9	7	Calf (C)- Lat mall	21		49	32
				Calf (C)- Calf (A)	14	2.7	51	32

Normal left upper and lower extremity sensory potentials, including palmar and left median antidromic responses.

**Table 4C**  
F wave.

Nerve	F Lateral ms	M Lat Ms	F-M Lat ms
L. Tibial- AH	57.3	4.4	52.9
L. Ulnar- ADM	0.0	2.9	2.9

F-wave table showing absence of left ulnar F wave response (which could be consistent with demyelination or axonal degenerative process. Normal left tibial F-wave latency.

**Table 4D**  
H reflex.

Nerve	H Lat ms	
	Left	Right
Tibial- Soleus	0.0	0.0

Absent bilateral tibial H reflexes, a demyelinating feature.

multitargeted tyrosine kinase inhibitor approved for the treatment of renal cell carcinoma and imatinib-resistant gastrointestinal stromal tumor (GIST) [13], has also been described as a cause of Guillain-Barre

syndrome [14].

The mechanism by which Nintedanib may have caused quadriplegia remains unclear but similar to sunitinib, it may be via inhibitory extracellular action against VEGF receptors, thus increasing levels, which is commonly associated with development of different neuropathies [14].

Diagnosis of acute inflammatory demyelinating polyneuropathy (AIDP) is based on clinical presentation and a constellation of findings on electrodiagnostic study including slowed motor conduction velocities, delayed latencies, dispersion of responses, conduction block, low distal compound muscle action potential amplitudes, and prolongation of minimum F wave latency. Even though our patient's electrodiagnostic study had some limited demyelination features like slowed motor conduction velocities, conduction block, absent H reflexes, absent left ulnar F-wave, it also had features which were inconsistent with a demyelinating process like absence of temporal dispersion and normal latencies in the motor waves. Patient's electrodiagnostic study therefore did not meet criteria for AIDP. Additionally, the absence of albumin-cytologic differentiation on CSF, brain and pan spinal MRI without any evidence of nerve root enhancement were not supportive of AIDP.

With increasing use of Nintedanib, it is inevitable that previously unknown and unreported side effects will come to bear, and this calls for a higher level of vigilance among physicians. To the best of our

knowledge, this is the second reported case of quadriparesis following the use of Nintedanib. Patejdl et al. [15] reported a similar case of quadriparesis that occurred 12 weeks after initiation of Nintedanib. Their patient required plasmapheresis with slow improvement in motor weakness over several months as opposed to our patient whose symptoms started within 24 hours of initiation of therapy and resolved over 3 weeks with withdrawal of medication and supportive management. Our case suggests that neurologic complications associated with Nintedanib could potentially be immediate and have different clinical courses in different patients.

#### Declarations of interest

None.

#### Declaration of competing interest

Authors have no conflicts of interest to declare.

#### References

- [1] G. Sgalla, A. Biffi, L. Richeldi, Idiopathic pulmonary fibrosis: diagnosis, epidemiology and natural history, *Respirology* 21 (3) (2015) 427–437.
- [2] J. Hutchinson, A. Fogarty, R. Hubbard, T. McKeever, Global incidence and mortality of idiopathic pulmonary fibrosis: a systematic review, *Eur. Respir. J.* 46 (3) (2015) 795–806, <https://doi.org/10.1183/09031936.00185114>.
- [3] L. Planas-Cerezales, E. Arias-Salgado, I. Buendia-Roldán, et al., Predictive factors and prognostic effect of telomere shortening in pulmonary fibrosis, *Respirology* 24 (2) (2018) 146–153, <https://doi.org/10.1111/resp.13423>.
- [4] Efficacy and safety of nintedanib in idiopathic pulmonary fibrosis, 782-782, *N. Engl. J. Med.* 373 (8) (2015), <https://doi.org/10.1056/nejmx150012>.
- [5] L. Wollin, E. Wex, A. Pautsch, et al., Mode of action of nintedanib in the treatment of idiopathic pulmonary fibrosis, *Respiratory Medicine Case Reports* 34 (2021) 101472, <https://doi.org/10.1183/09031936.00174914>.
- [6] K. Flaherty, A. Wells, V. Cottin, et al., Nintedanib in progressive fibrosing interstitial lung diseases, *N. Engl. J. Med.* 381 (18) (2019) 1718–1727, <https://doi.org/10.1056/nejmoa1908681>.
- [7] O. Distler, K. Highland, M. Gahlemann, et al., Nintedanib for systemic sclerosis-associated interstitial lung disease, *N. Engl. J. Med.* 380 (26) (2019) 2518–2528, <https://doi.org/10.1056/nejmoa1903076>.
- [8] M. Kuwana, A. Azuma, Nintedanib: new indication for systemic sclerosis-associated interstitial lung disease, *Mod. Rheumatol.* 30 (2) (2019) 225–231, <https://doi.org/10.1080/14397595.2019.1696505>.
- [9] Human medicines European public assessment report (EPAR): ofev, nintedanib, idiopathic pulmonary fibrosis, date of authorisation: 14/01/2015, revision: 10, status: authorized, Case Medical Research (2019), <https://doi.org/10.31525/cm-587247>.
- [10] T. Lehky, F. Iwamoto, T. Kreisl, M. Floeter, H. Fine, Neuromuscular junction toxicity with tandutinib induces a myasthenic-like syndrome, *Neurology* 76 (3) (2011) 236–241, <https://doi.org/10.1212/wnl.0b013e3182074a69>.
- [11] D. DeAngelo, R. Stone, M. Heaney, et al., Phase 1 clinical results with tandutinib (MLN518), a novel FLT3 antagonist, in patients with acute myelogenous leukemia or high-risk myelodysplastic syndrome: safety, pharmacokinetics, and pharmacodynamics, *Blood* 108 (12) (2006) 3674–3681, <https://doi.org/10.1182/blood-2006-02-005702>.
- [12] S. Kavanagh, V. Bril, J. Lipton, Peripheral neuropathy associated with imatinib therapy for chronic myeloid leukemia, *Blood Research* 53 (2) (2018) 172, <https://doi.org/10.5045/br.2018.53.2.172>.
- [13] G.S. Papaetis, K.N. Syrigos, Sunitinib: a multitargeted receptor tyrosine kinase inhibitor in the era of molecular cancer therapies, *BioDrugs* 23 (6) (2009) 377–389, <https://doi.org/10.2165/11318860-000000000-00000>. PMID: 19894779. (2021).
- [14] Z. Kanaan, Z. Kulairi, M. Titianu, S. Saha, S. Kumar, Guillain-barré syndrome following treatment with sunitinib malate, 2014, *Case Reports in Oncological Medicine* (2014) 1–2, <https://doi.org/10.1155/2014/712040>.
- [15] R. Patejdl, S. Markmann, R. Benecke, M. Wittstock, Severe acute motor neuropathy after treatment with triple tyrosine kinase inhibitor BIBF 1120 (Nintedanib), *Clin. Neurol. Neurosurg.* 115 (9) (2013) 1851–1852, <https://doi.org/10.1016/j.clineuro.2013.01.011>.