

INTRODUCTION

Cutaneous basal cell carcinoma (BCC) is an increasingly common malignancy with a rising incidence over the past decade.¹ BCC seldom exhibits lymphatic or hematogenous metastasis with an incidence of only 0.0028% to 0.5%.² There are only around 400 combined reports of metastatic spread of basal cell carcinoma (mBCC) since the 1980s, with hematogenous cases constituting a small minority. Typically, those diagnosed with hematogenous mBCC have a median survival of 8-14 months compared to those diagnosed with lymphatic mBCC, whose survival average is reported to be 3.6 years.³ This case report focuses on a patient who presented with a basal cell carcinoma on his left shoulder that had metastasized to the spine. Ultimately, a multimodal therapeutic approach was required to bring the patient's metastatic disease under control, including surgical resection, radiation therapy, and systemic therapy with hedgehog inhibitors (vismodegib, sonidegib) and novel employment of immunotherapy agents including pembrolizumab. To the author's knowledge and based on our included literature review, this is the first case where pembrolizumab was used to treat osseous mBCC.

MATERIALS & METHODS

- A systematic literature review returned 229 articles for review. Articles were removed if they were not available in english (N=26) or if they were only reviews (N=19). Articles were then removed after review by authors (AG and AC) based on their topic by review of abstracts (N=120) and subsequently review at the manuscript level (59 removed).
- Articles were determined to be significant if metastatic basal cell carcinoma (mBCC) was spread to any bone in the body as confirmed by histological testing in the article.

Results

- 29 total cases of osseous metastasis of BCC.
- Primary lesions of the head and neck usually spread locally to the skull or mandible.
- Primary lesions of the thorax and extremities had organ and spine metastasis
- Treatment usually included surgery and radiation therapy for local involvements and hedgehog inhibitors and/or chemotherapy for distant metastasis
- None of the patients received immunotherapy for mBCC making this the first patient in publication for osseous metastasis, due to the patients TMB-H status

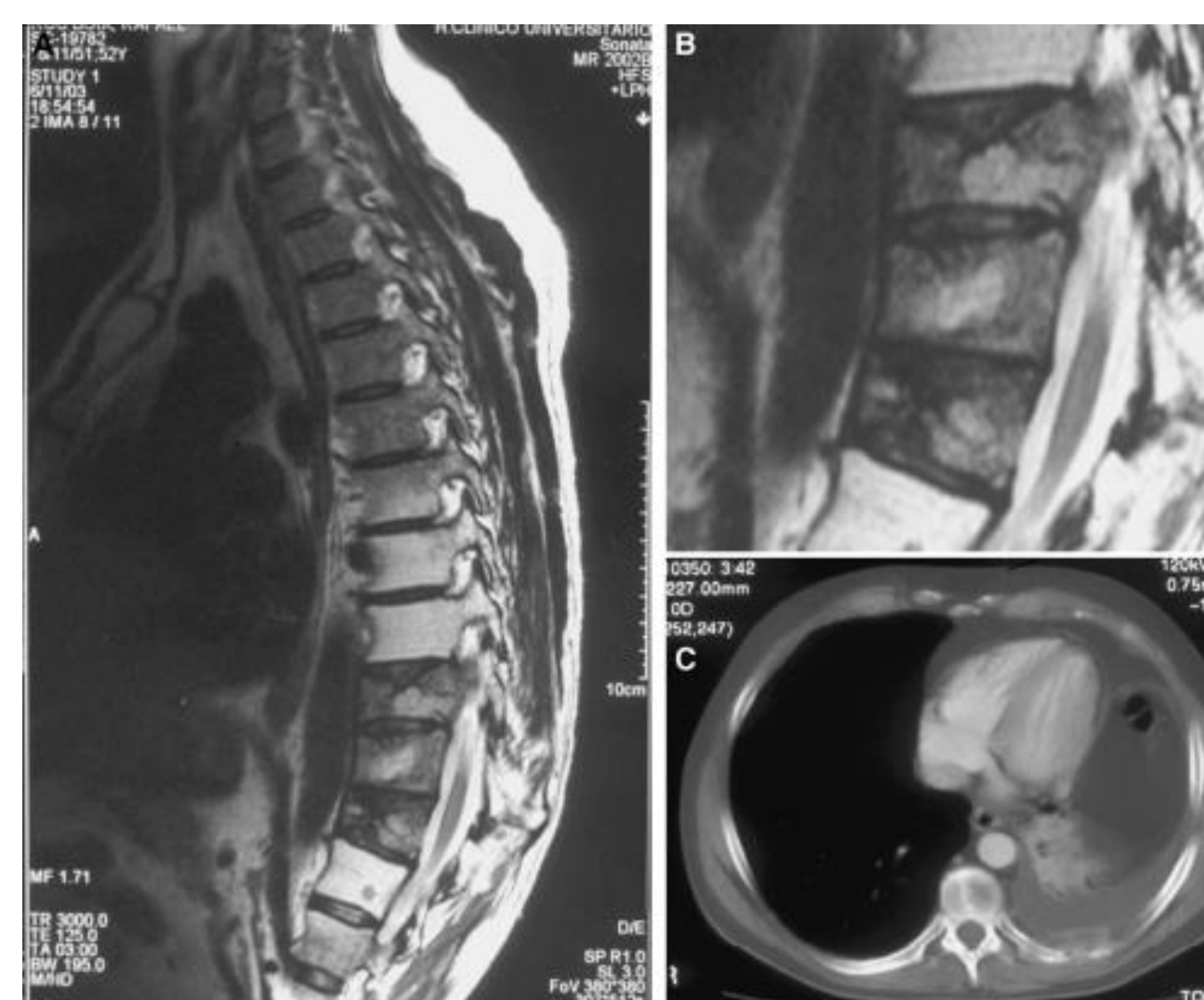
Pembrolizumab Induced Tumor Shrinkage in Rare Osseous Metastasis of Basal Cell Carcinoma

Amanda Goetz¹, Andrew Cunningham¹, Andrew Ju¹, Matthew Peach¹

¹. Department of Radiation Oncology, Brody School of Medicine, East Carolina University, Greenville, USA

Case Report

- **Initial Presentation:** 59 year old male presented with 3 year old left posterior mass confirmed to be BCC on exam. Initial results showed lymphatic spread of nodulocystic basal cell carcinoma.
- **1 month post-Dx:** 20 lung nodules of mBCC and lesion of the T2 spinous process. Started *vismodegib*.
- **23 month post-Dx:** Presented with bilateral lower extremity weakness. Pathological T2-T3 compression fracture with lytic destruction of both vertebra with soft tissue extension. Patient switched to *sonidegib*.
- **53 months post-Dx:** Presented with bilateral leg weakness and recurred T2/T3 enhancing mass and bilateral lung nodules. Irradiation of the thoracic paravertebral disease completed. Tumor showed high TMB and patients switched to *pembrolizumab with denosumab*.
- **60 to 68 months post-Dx:** CT demonstrated decreased size of pulmonary nodules with stable perithoracic disease and now has radiologic response.
- **91 months post-Dx:** Stable mets on 36 months of radiographic follow-up completing 39 cycles of 200mg pembrolizumab + denosumab and 5 cycles of 400mg pembrolizumab + denosumab.



Magnetic Resonance imaging suggestive of neoplastic infiltration of the spine

Credit: Alonso V, Revert A, Monteagudo C, Martin JM, Insa A, Pinazo I, Ferrer J, Jorda E. Basal cell carcinoma with distant multiple metastases to the vertebral column. J Eur Acad Dermatol Venereol. 2006 Jul;20(6):748-9. doi: 10.1111/j.1468-3083.2006.01525.x. PMID: 16836516.

Discussion

- Metastatic mBCC typically treated with surgery and radiation with systemic mets requiring chemotherapeutic agents such as cisplatin, cyclophosphamide, and fluorouracil.
- Hedgehog inhibitors have been a more recent development and remains a primary treatment option.
- Pembrolizumab and denosumab can be used when not responding to hedgehog inhibitors and was shown to shrink lesions by radiographic imaging.
- The effectiveness of pembrolizumab was likely due to the TMB-H status of the patient.

About TMB:

TMB has emerged as a biomarker capable of defining the number of mutations in cancer cells' DNA reported as mutations per megabase (mut/MB).^{4,5} Patients with TMB \geq 10 mut/Mb is considered TMB-H and has been linked to greater overall survival, with FDA approval for Pembrolizumab monotherapy for a subgroup of solid tumor patients with TMB \geq 10 mut/Mb based on data from KEYNOTE-158.⁶ Previous small retrospective studies have demonstrated correlations between TMB and treatment efficacy with pembrolizumab. In tumors with low-TMB (TMB-L) tumors, there was limited response to immunotherapy whereas the highest response rates were seen in TMB-H tumors.^{7,8} Thus, we believe the TMB-H status may have been a contributing factor to the favorable response of the primary tumor and secondary lung nodules to the immunotherapy.

References

1. Rogers HW, Weinstock MA, Feldman SR, Coldiron BM. Incidence estimate of nonmelanoma skin cancer (keratinocyte carcinomas) in the U.S. population, 2012. *JAMA Dermatol*. 2015;151(10):1081-1086. Accessed Jun 12, 2023. doi: 10.1001/jamadermatol.2015.1187.
2. Kim DP, Kus KJB, Ruiz E. Basal cell carcinoma review. *Hematol Oncol Clin North Am*. 2019;33(1):13-24. Accessed Jun 13, 2023. doi: 10.1016/j.hoc.2018.09.004.
3. McCusker M, Basset-Seguín N, Dummer R, et al. Metastatic basal cell carcinoma: Prognosis dependent on anatomic site and spread of disease. *Eur J Cancer*. 2014;50(4):774-783. Accessed Jun 12, 2023. doi: 10.1016/j.ejca.2013.12.013.
4. Sha D, Jin Z, Budzgies J, Kluck K, Stenzinger A, Sinicrope FA. Tumor mutational burden (TMB) as a predictive biomarker in solid tumors. *Cancer Discov*. 2020;10(12):1808-1825. <https://www.ncbi.nlm.nih.gov/pmc/articles/PMC7710563/>. Accessed Jun 12, 2023. doi: 10.1158/2159-8290.CD-20-0522.
5. Shiravand Y, Khodadadi F, Kashani SMA, et al. Immune checkpoint inhibitors in cancer therapy. *Curr Oncol*. 2022;29(5):3044-3060. <https://www.ncbi.nlm.nih.gov/pmc/articles/PMC9139602/>. Accessed Jun 12, 2023. doi: 10.3390/curroncol29050247.
6. Marabelle A, Fakih M, Lopez J, et al. Association of tumour mutational burden with outcomes in patients with advanced solid tumours treated with pembrolizumab: Prospective biomarker analysis of the multicohort, open-label, phase 2 KEYNOTE-158 study. *Lancet Oncol*. 2020;21(10):1353-1365. Accessed Jun 12, 2023. doi: 10.1016/S1473-0165(20)30445-9.
7. Goodman AM, Kato S, Bazhenova L, et al. Tumor mutational burden as an independent predictor of response to immunotherapy in diverse cancers. *Mol Cancer Ther*. 2017;16(11):2598-2608. <https://www.ncbi.nlm.nih.gov/pmc/articles/PMC5670009/>. Accessed Jun 12, 2023. doi: 10.1158/1535-7163.MCT-17-0386.
8. Cristescu R, Mogg R, Ayers M, et al. Pan-tumor genomic biomarkers for PD-1 checkpoint blockade-based immunotherapy. *Science*. 2018;362(6411):eaar3593. <https://www.ncbi.nlm.nih.gov/pmc/articles/PMC6718162/>. Accessed Jun 12, 2023. doi: 10.1126/science.aar3593.